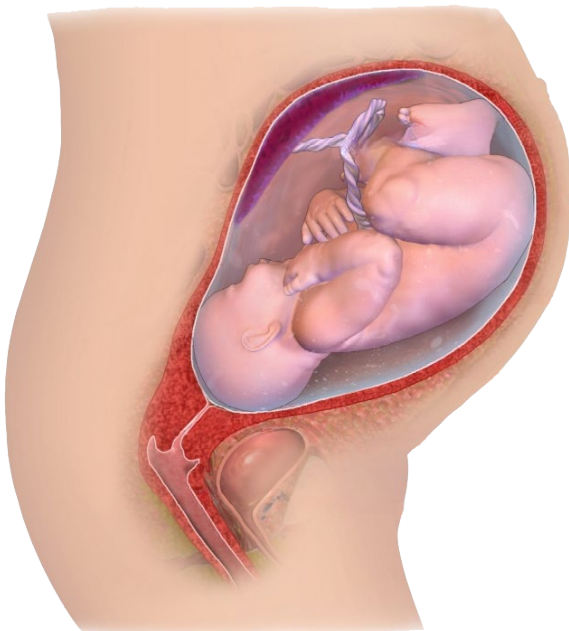




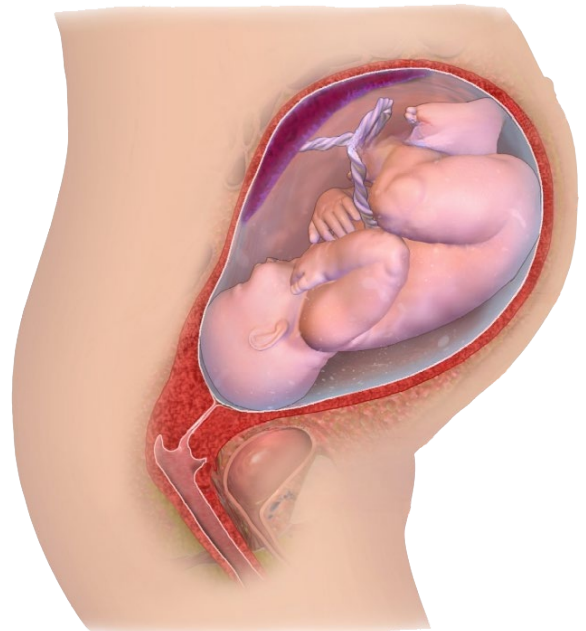
schwängere Frau



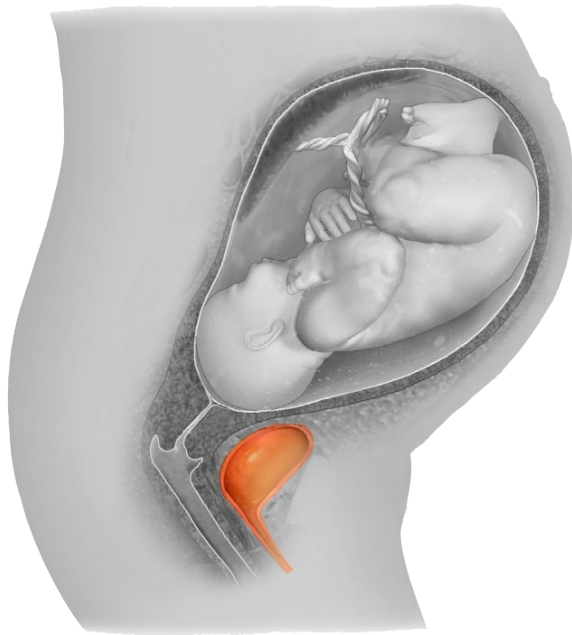
schwängere Frau



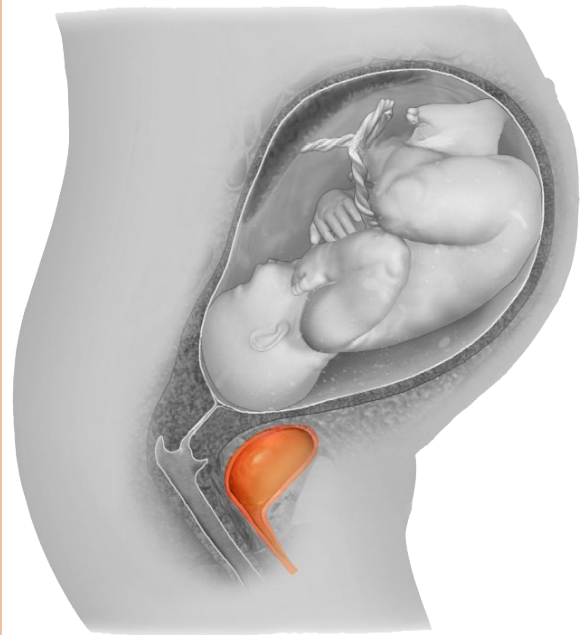
Fötus in der
Gebärmutter



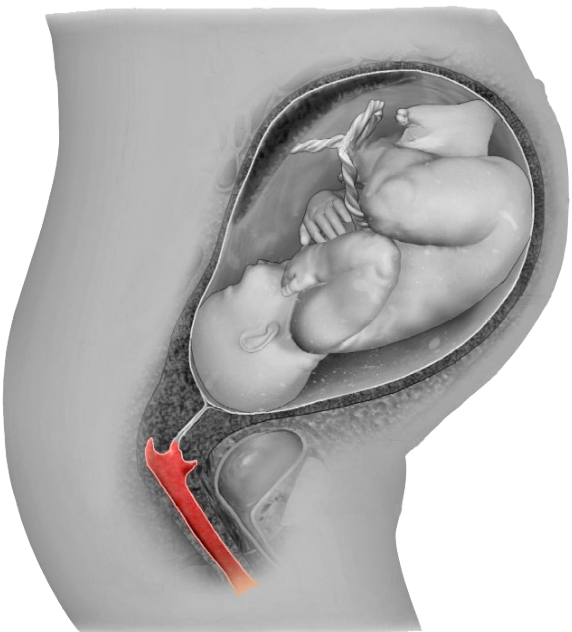
Fötus in der
Gebärmutter



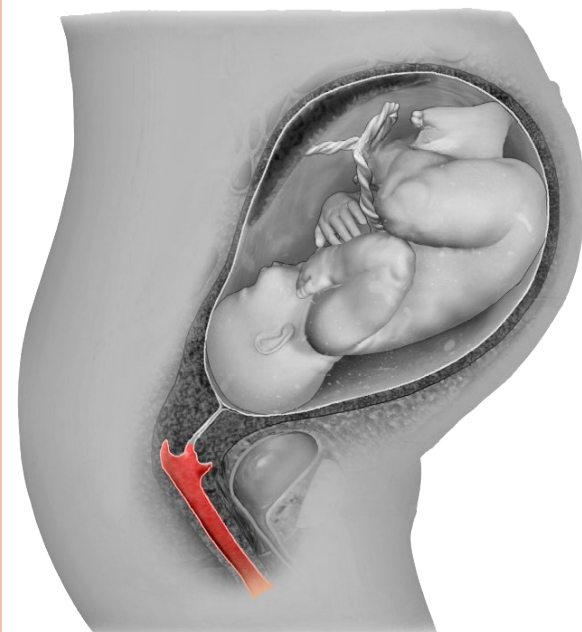
Harnblase und
Harnröhre



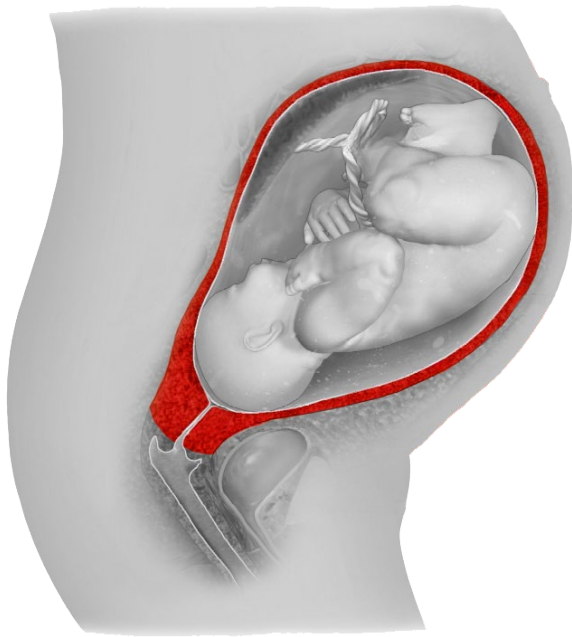
Harnblase und
Harnröhre



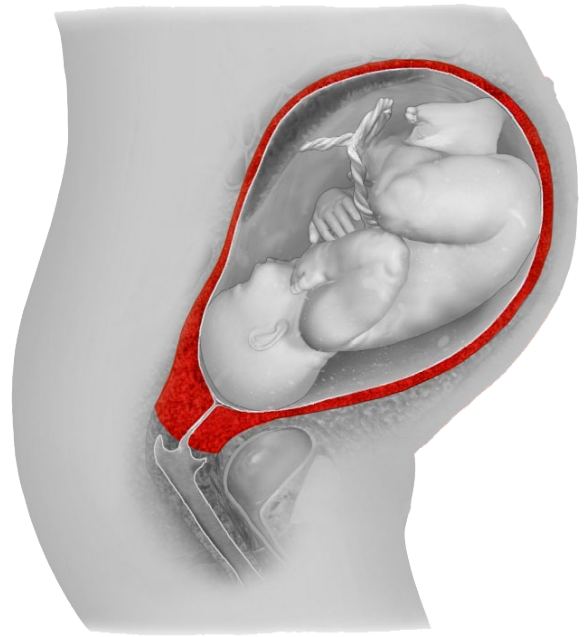
Scheide (Vagina)



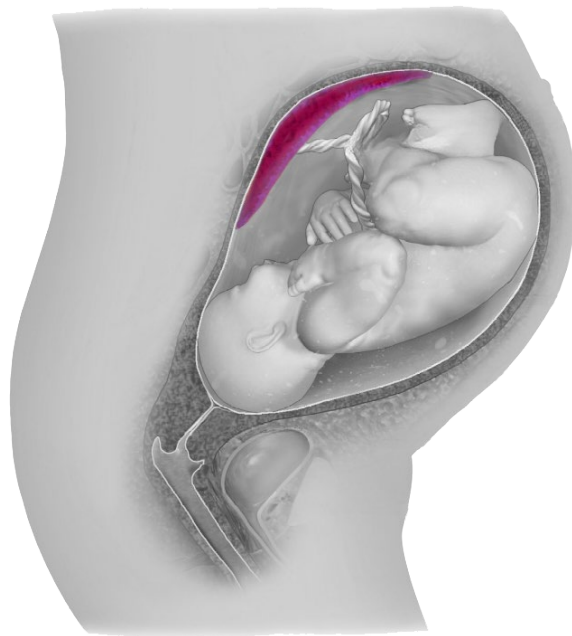
Scheide (Vagina)



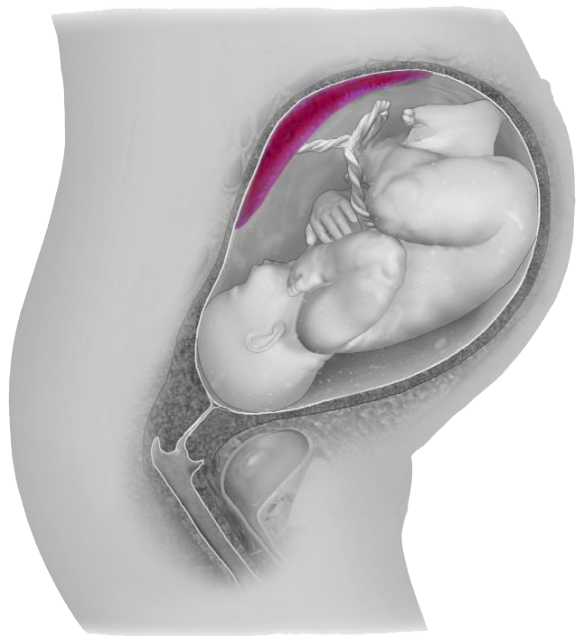
Gebärmutter



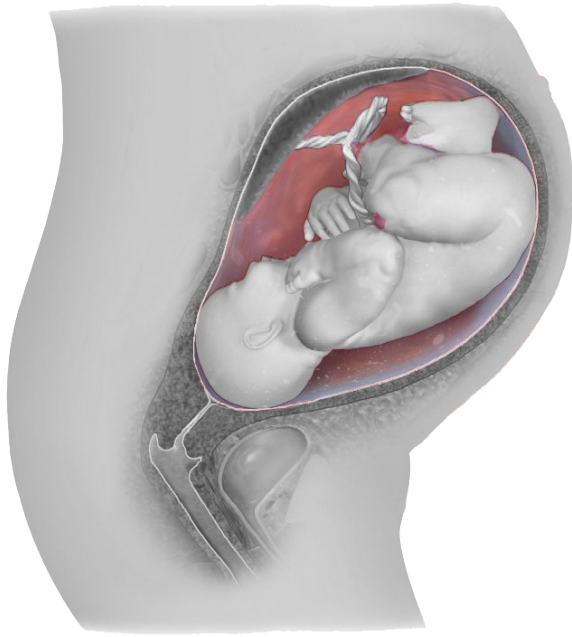
Gebärmutter



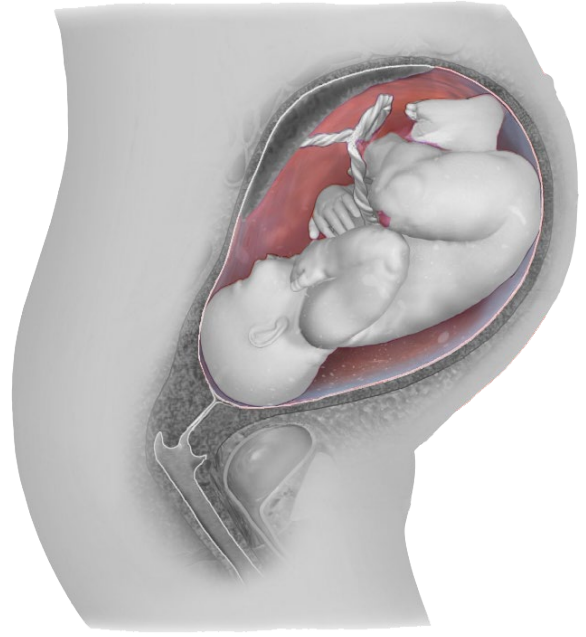
Mutterkuchen
(Plazenta)



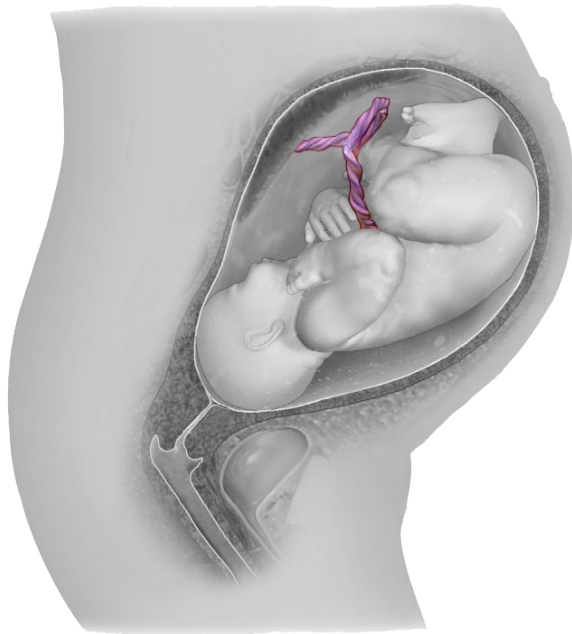
Mutterkuchen
(Plazenta)



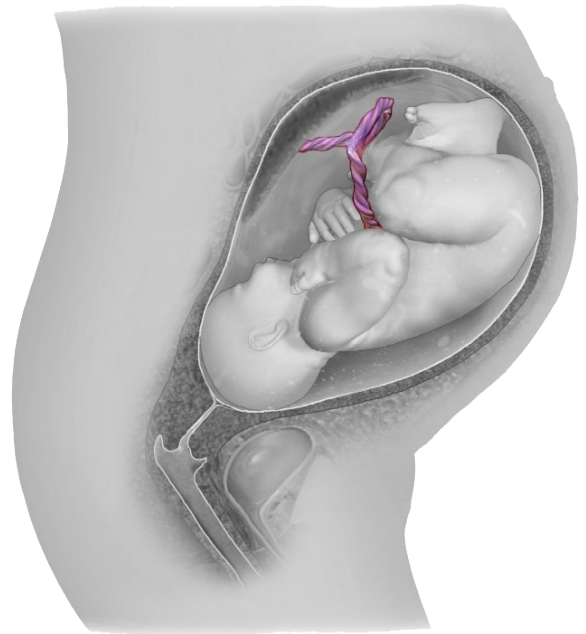
Fruchtblase mit
Fruchtwasser



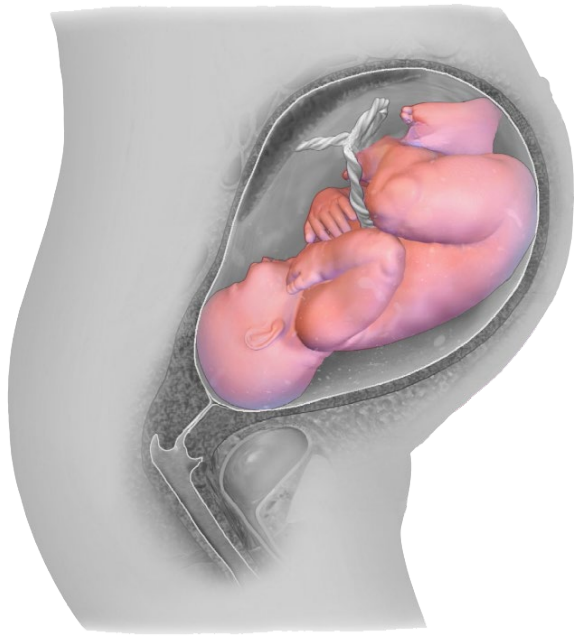Fruchtblase mit
Fruchtwasser



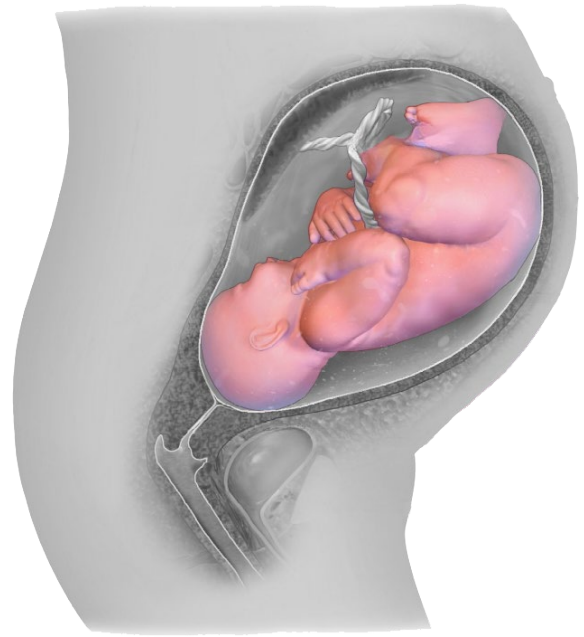Nabelschnur



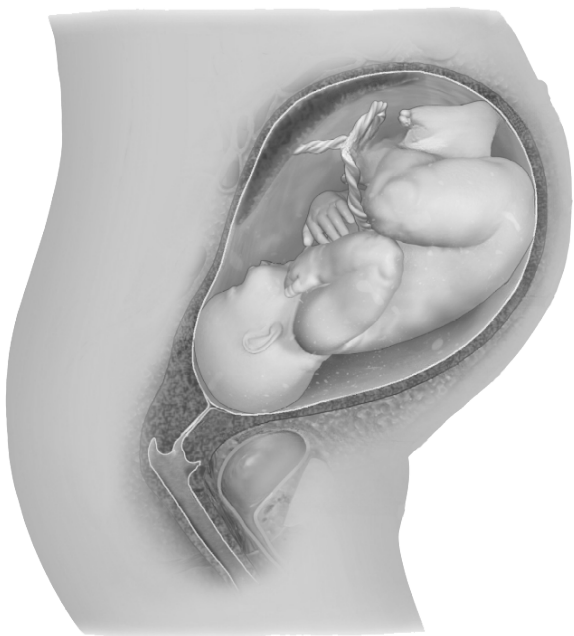
Nabelschnur



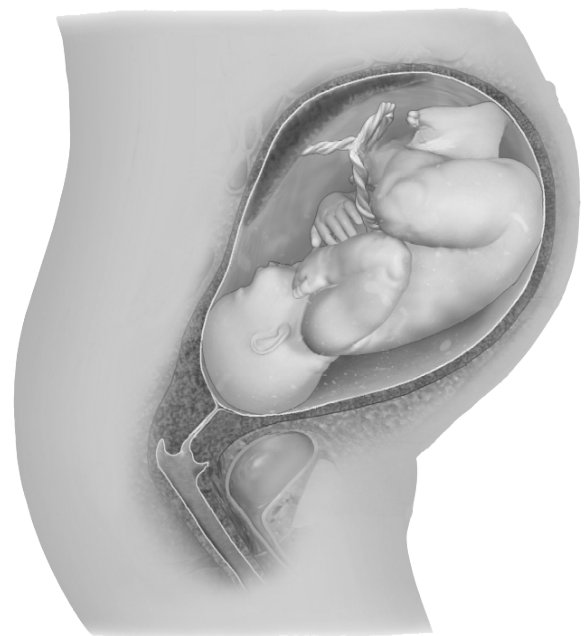
Fötus



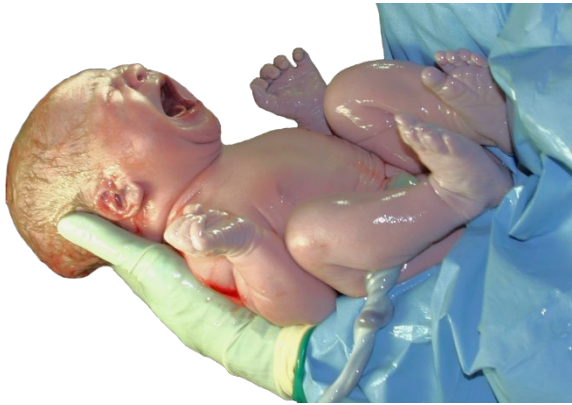Fötus



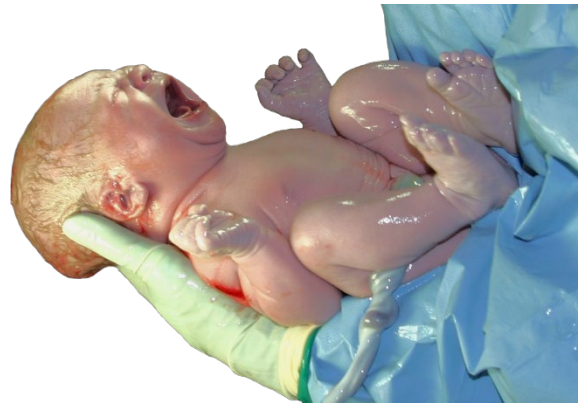Fötus in der Gebärmutter
(schwarz/weiß)



Fötus in der Gebärmutter
(schwarz/weiß)



Neugeborenes



Neugeborenes



etwas älteres Baby



etwas älteres Baby

Quellen

[A Pregnant Woman in Long Dress Standing on Green Grass Field · Free Stock Photo \(pexels.com\)](#)

[BruceBlais](#). When using this image in external sources it can be cited as: Blausen.com staff (2014).

"[Medical gallery of Blausen Medical 2014](#)". WikiJournal of Medicine 1

(2). DOI:[10.15347/wjm/2014.010](#). ISSN [2002-4436](#)., [Blausen 0747 Pregnancy](#), Bild gedreht, Beschriftung entfernt, schwarz/weiß eingefärbt, einzelne anatomische Teile farbig draufgelegt, [CC BY 3.0](#)

Ernest F, [HumanNewborn](#), Hintergrund teilweise entfernt, [CC BY-SA 3.0](#)

[Foto zum Thema baby in blauen unterteilen, die auf weißer oberfläche liegen – Kostenloses Bild zu Grau auf Unsplash](#)