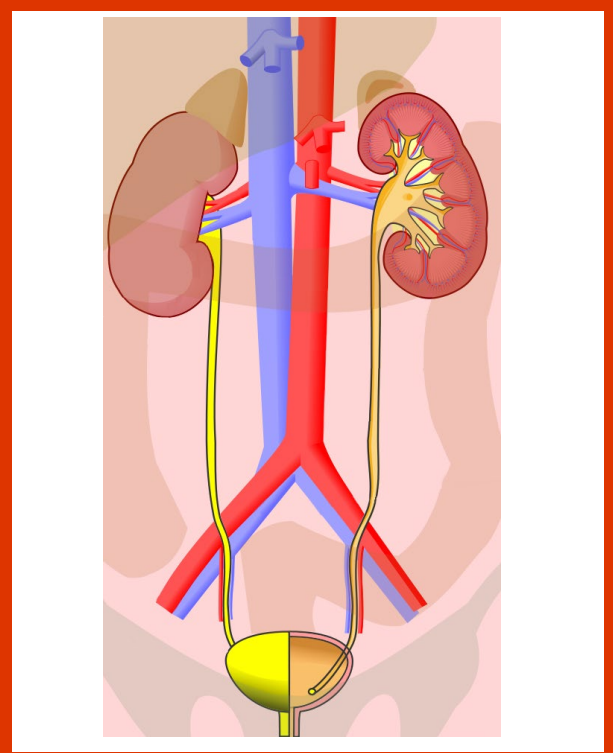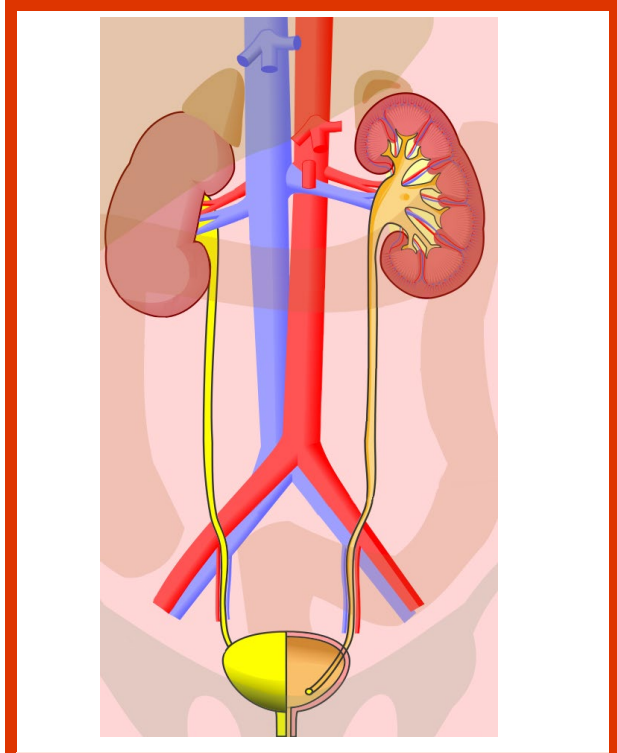
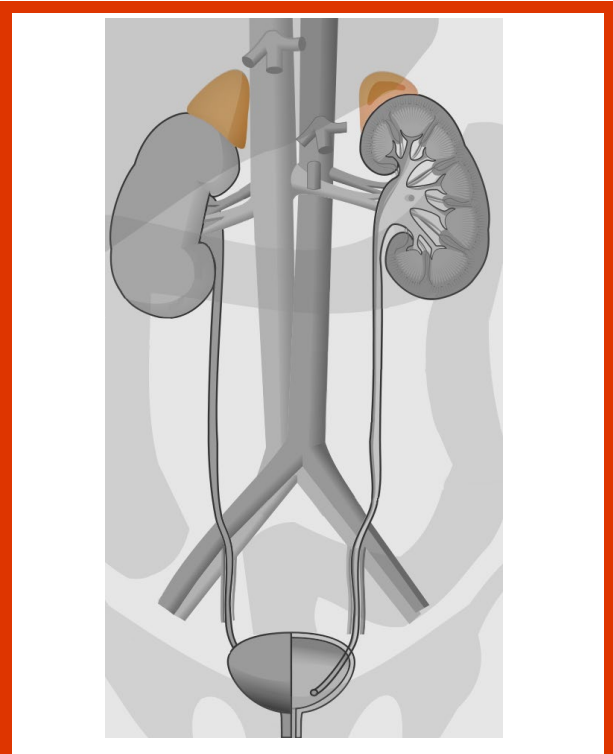


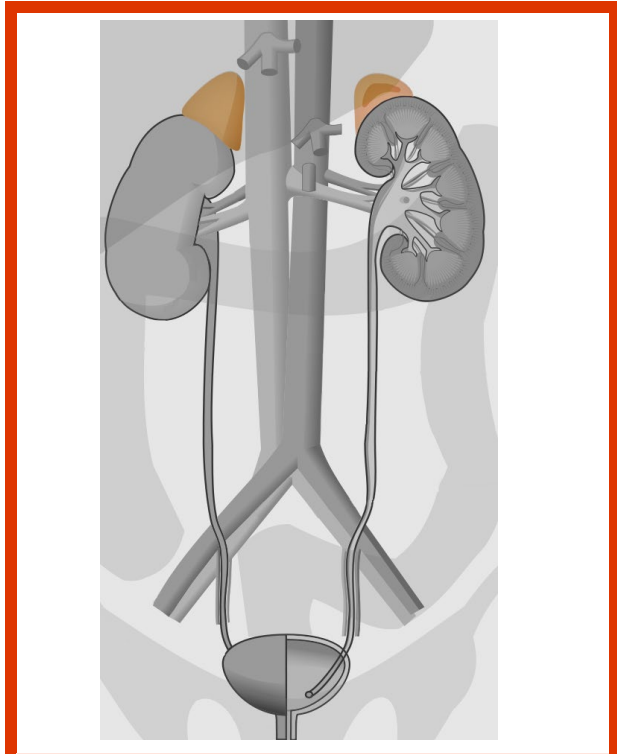
urinary system



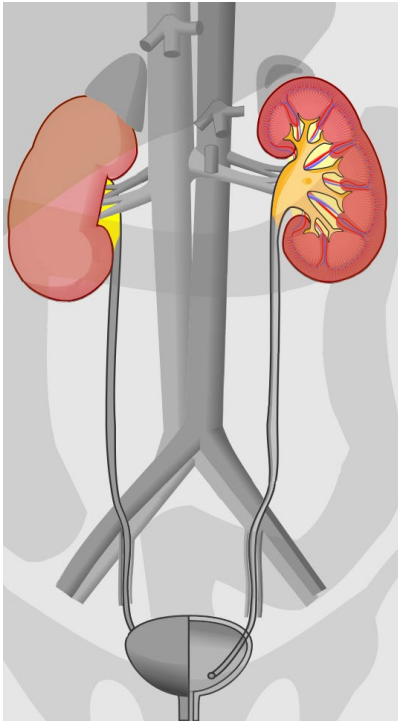
urinary system



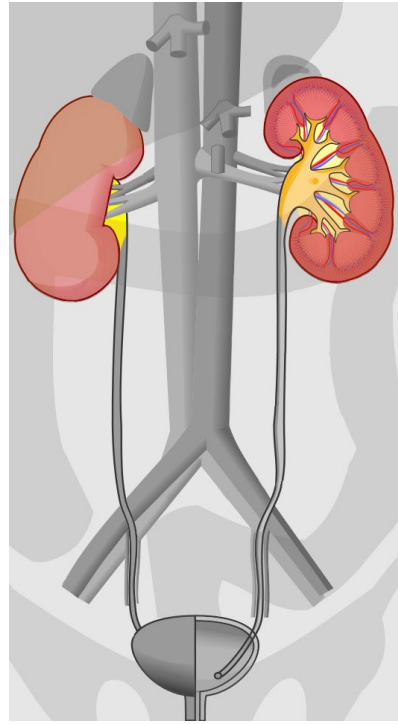
adrenal gland



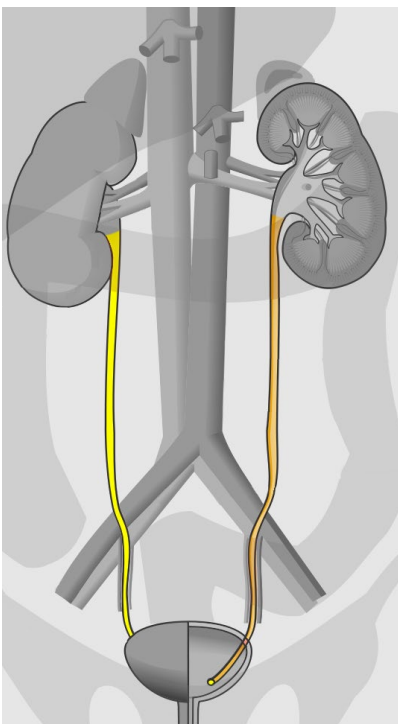
adrenal gland



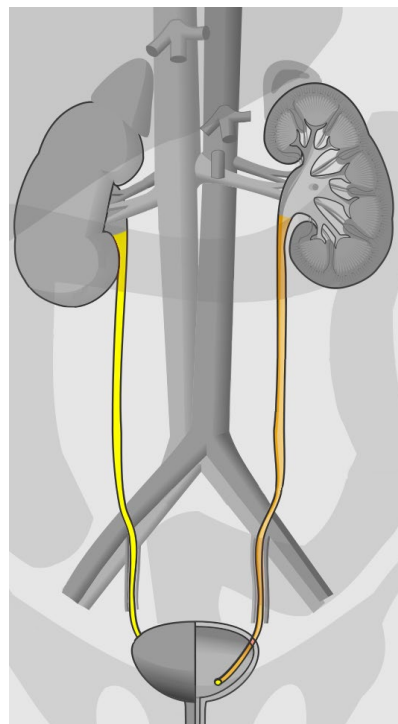
kidney



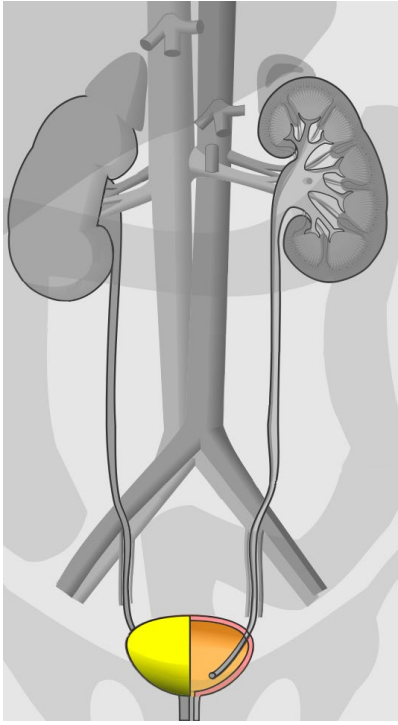
kidney



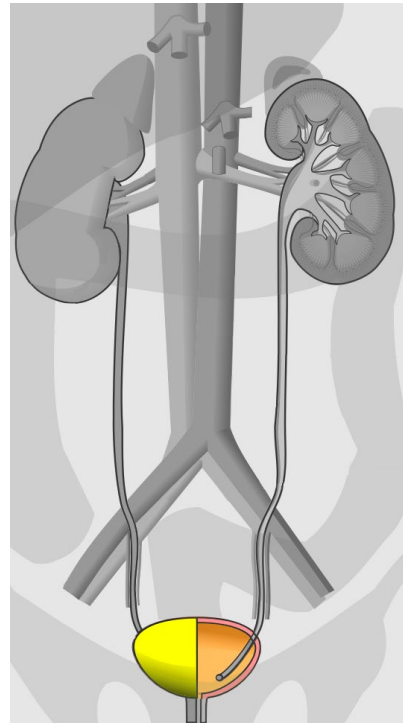
ureter



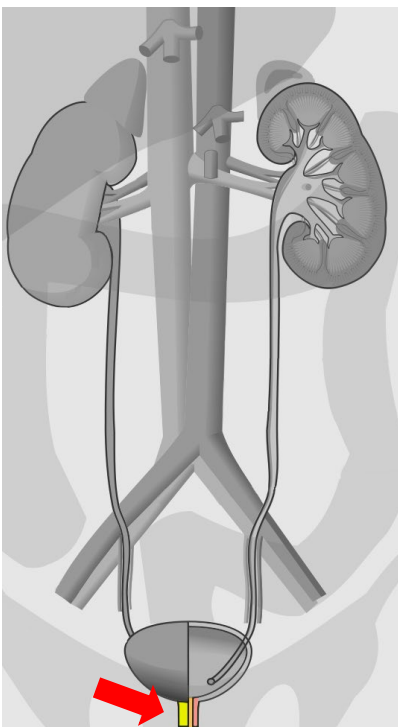
ureter



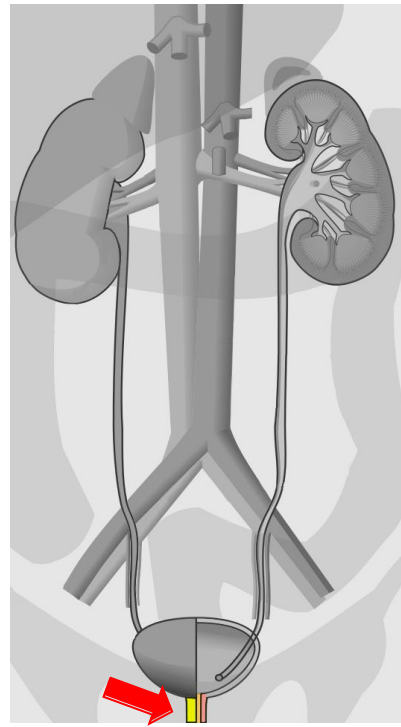
urinary bladder



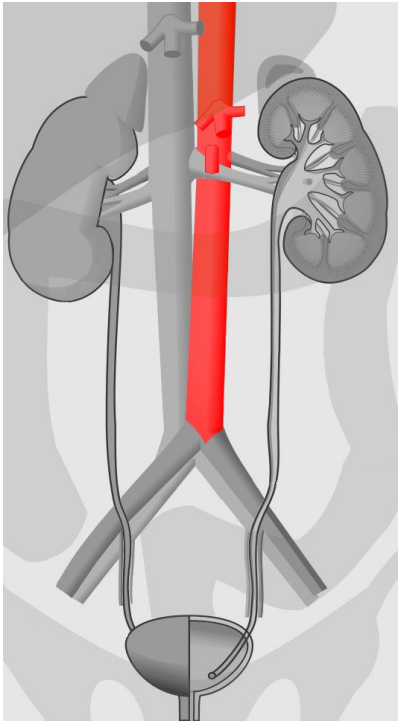
urinary bladder



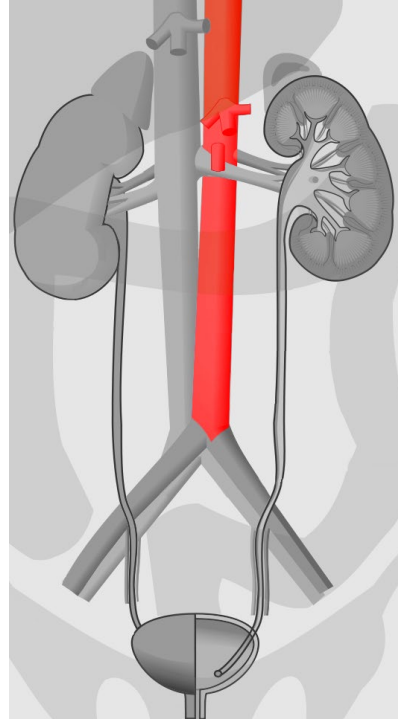
urethra



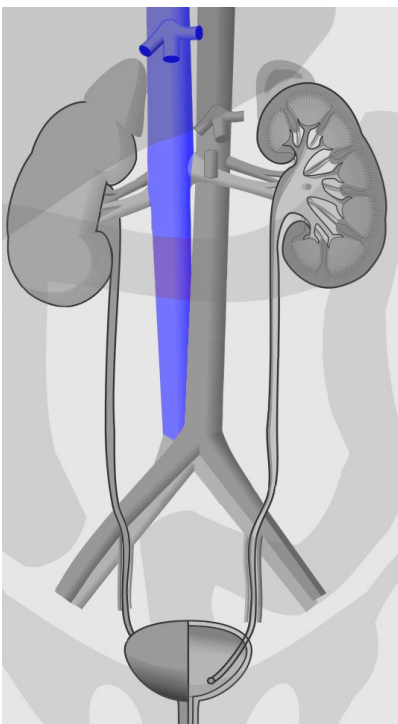
urethra



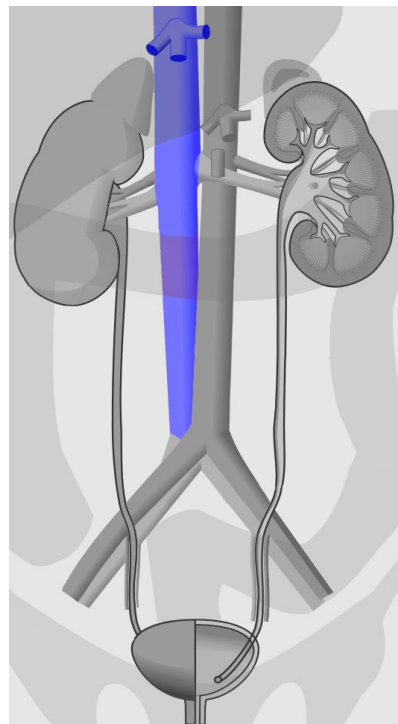
abdominal aorta



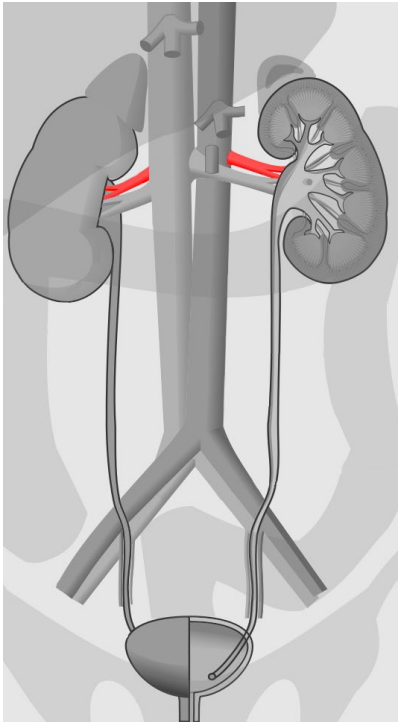
abdominal aorta



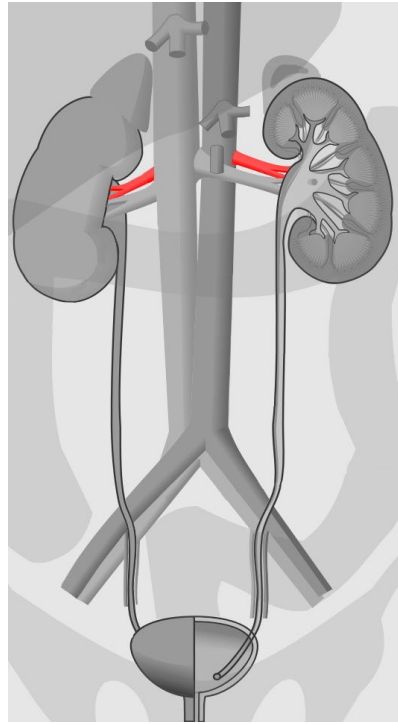
inferior vena cava



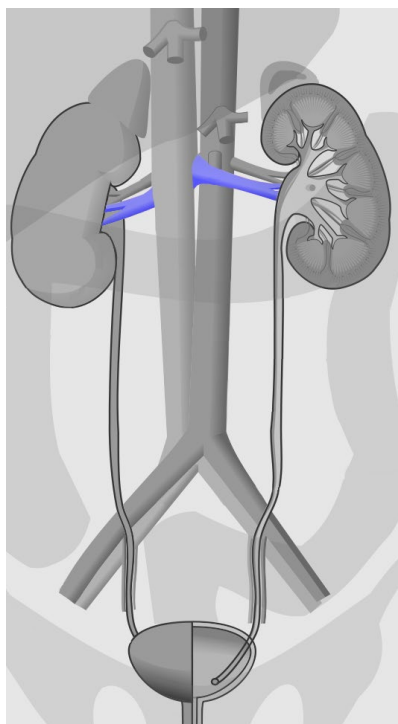
inferior vena cava



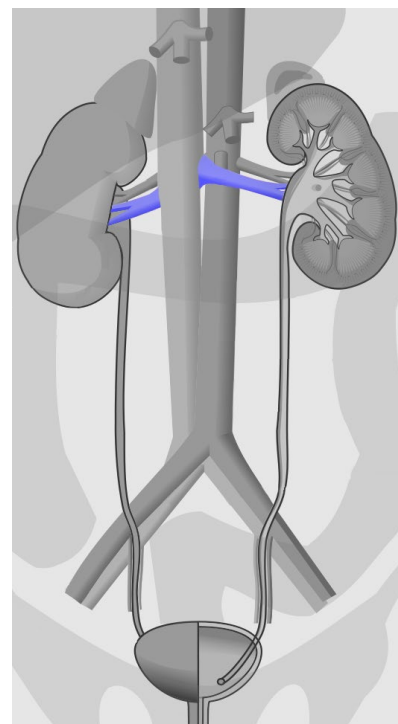
renal artery



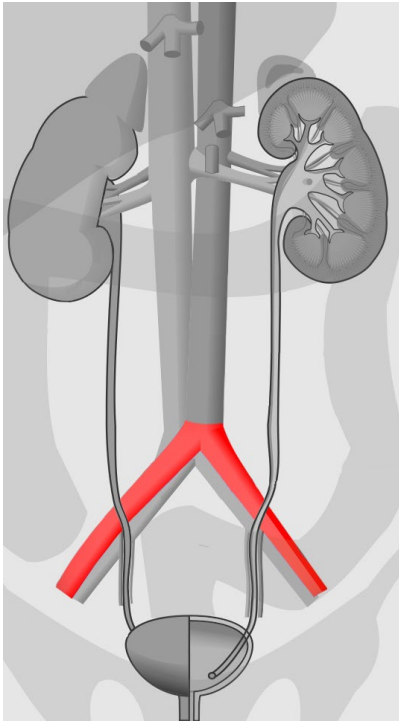
renal artery



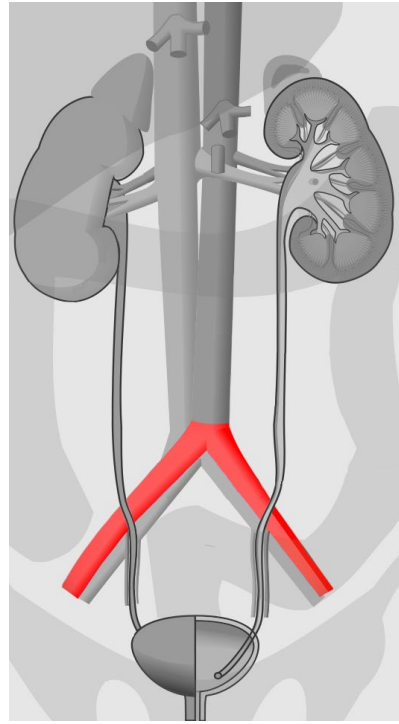
renal vein



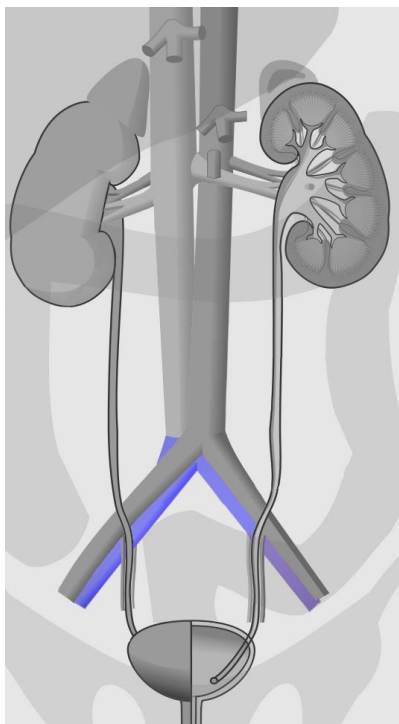
renal vein



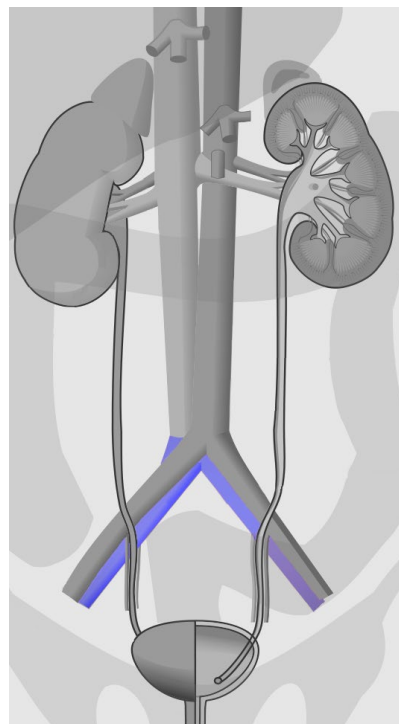
common iliac artery



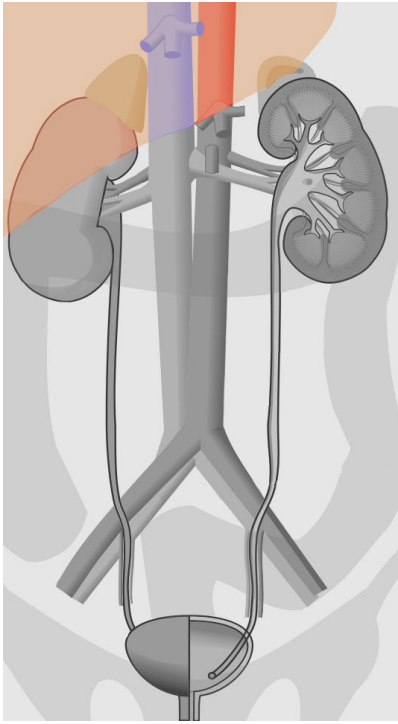
common iliac artery



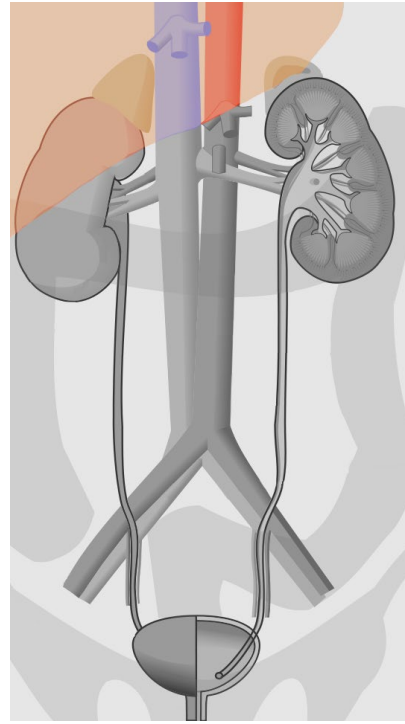
common iliac vein



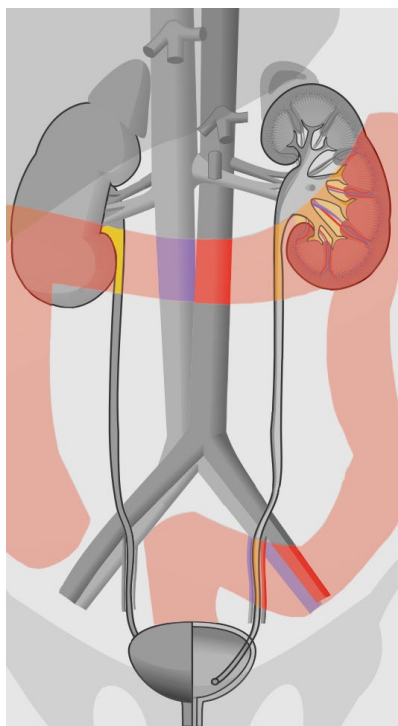
common iliac vein



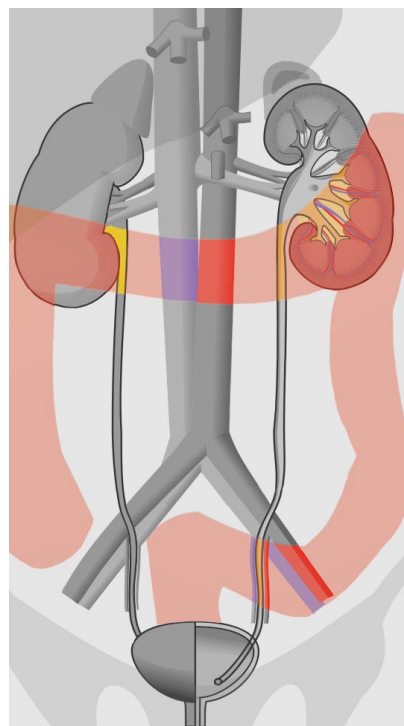
liver



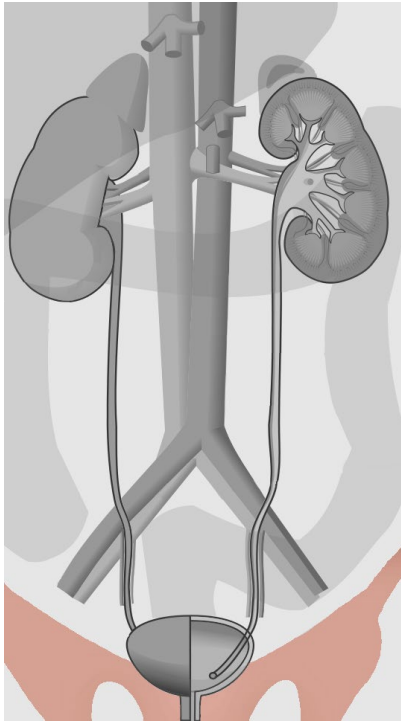
liver



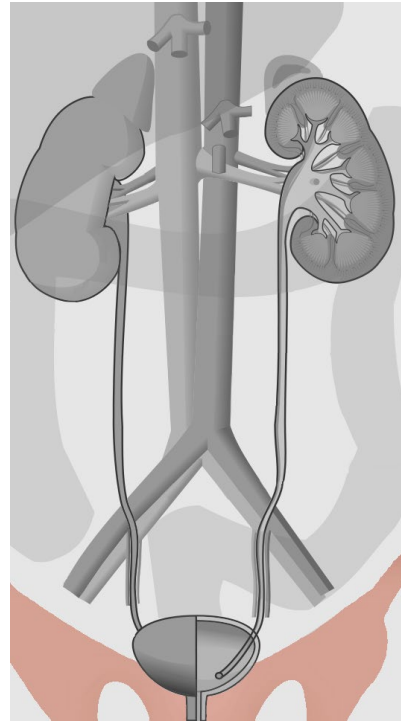
large intestine



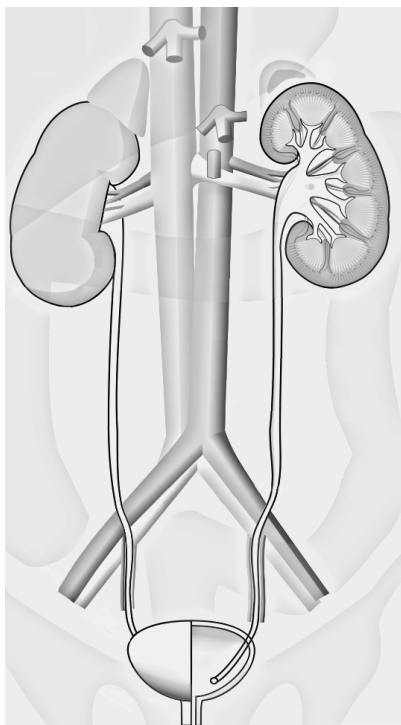
large intestine



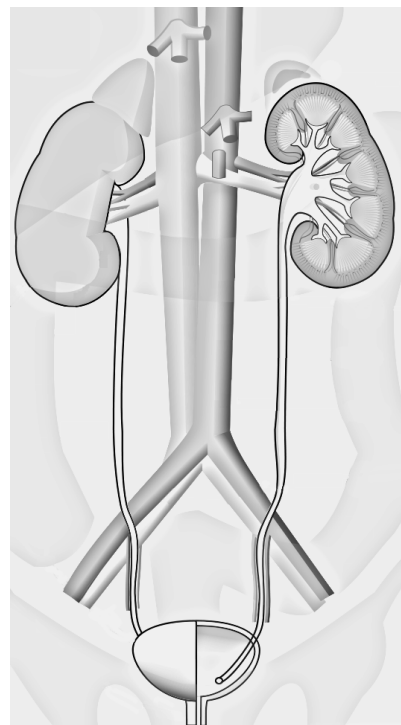
pelvis



pelvis



urinary system
black/white



urinary system
black/white

Quellen

[Andrewmeyerson, Urinary System Large Unlabeled](#), schwarz/weiß eingefärbt und einzelne anatomische Teile farbig draufgelegt, [CC BY-SA 3.0](#)