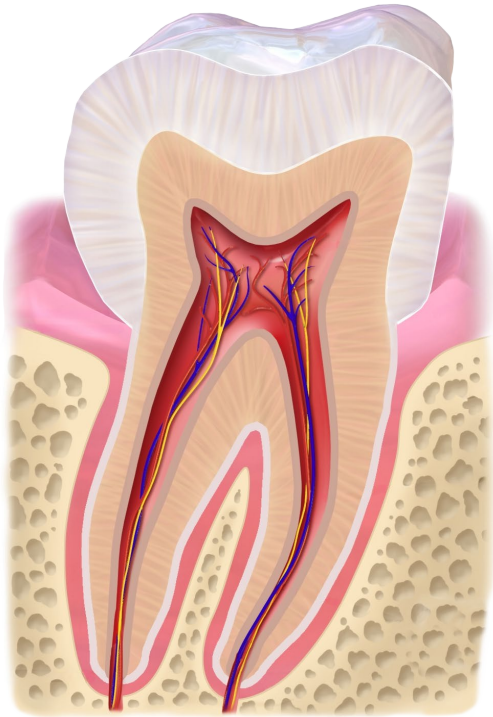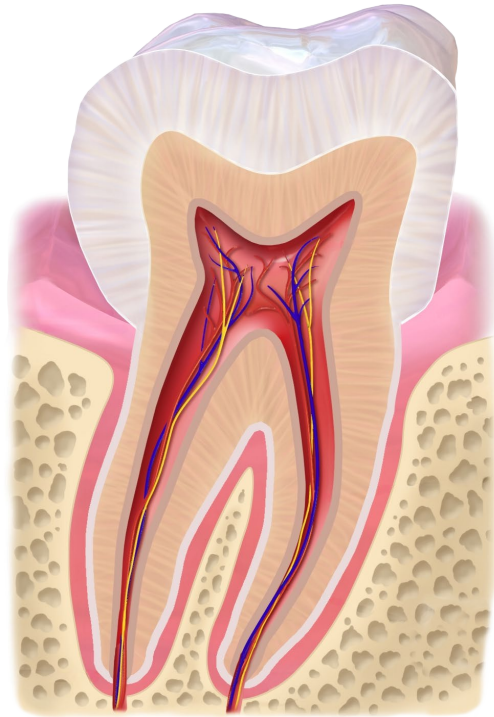
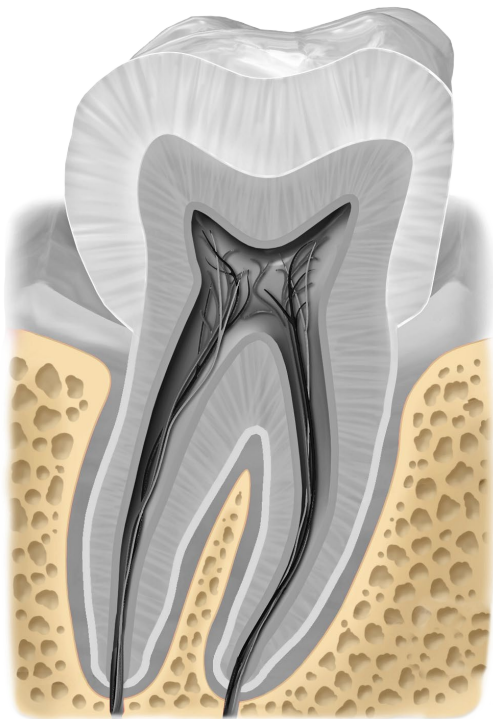


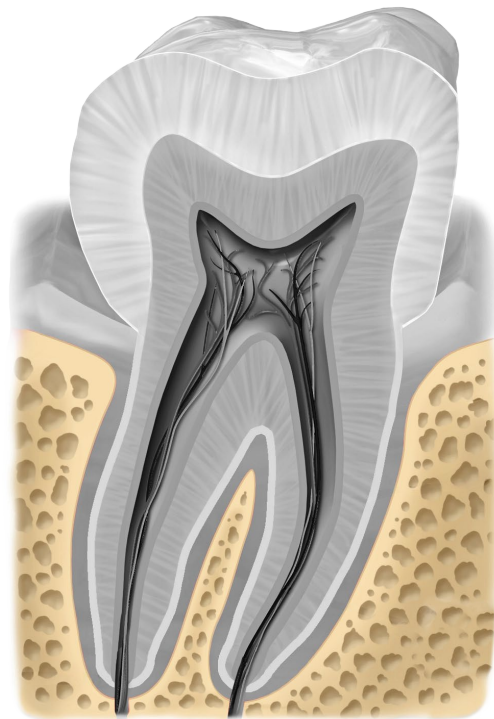
molar



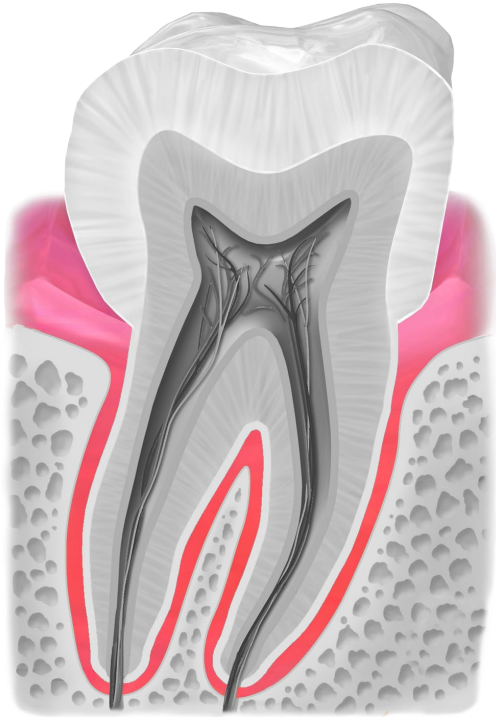
molar



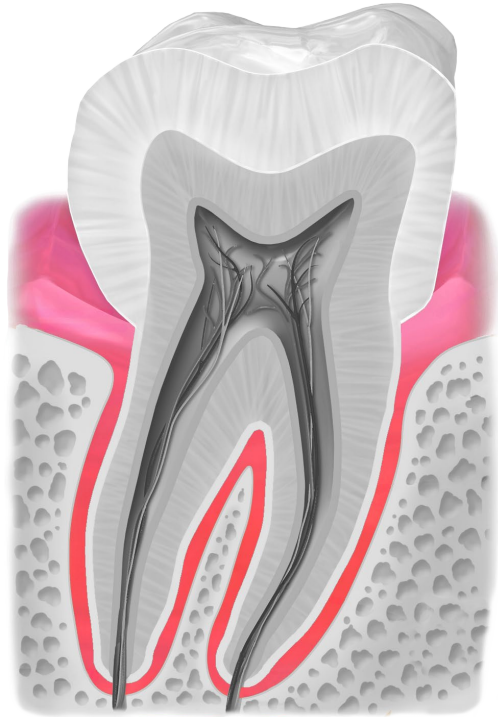
jawbone



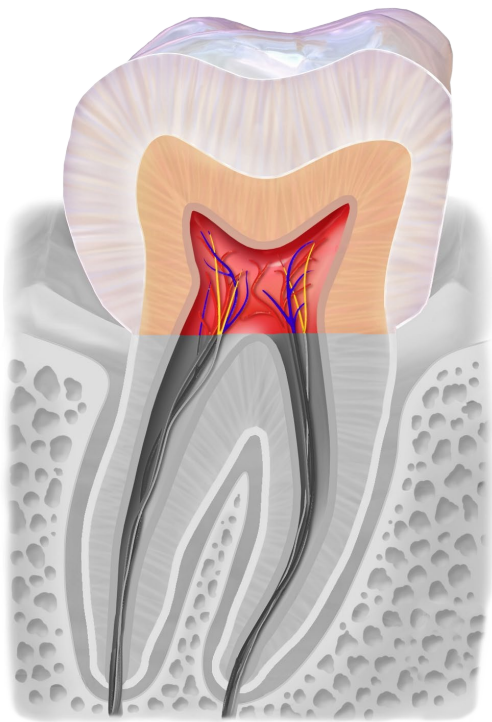
jawbone



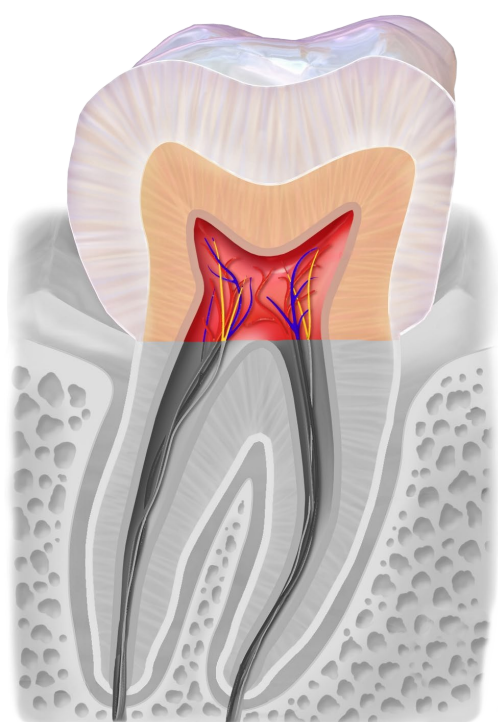
**gums**



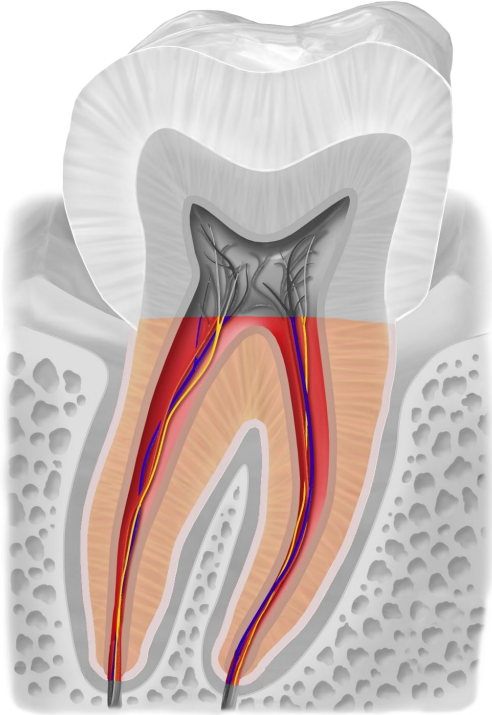
**gums**



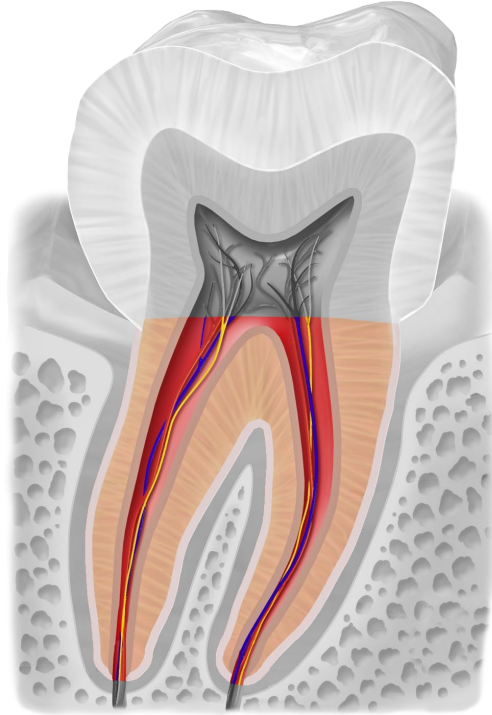
**crown**



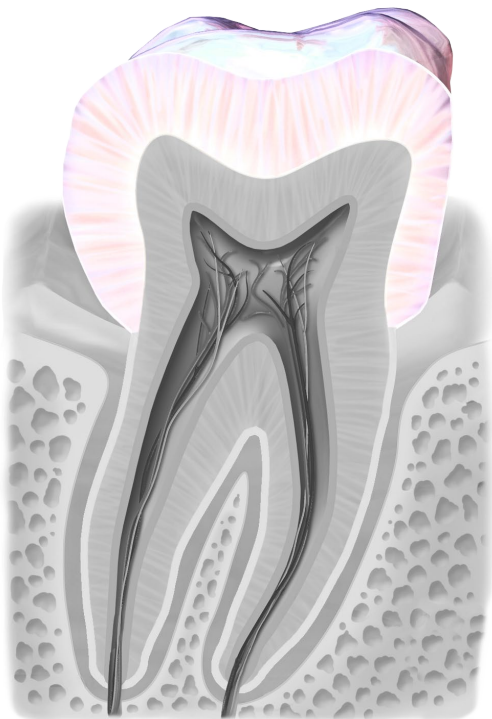
**crown**



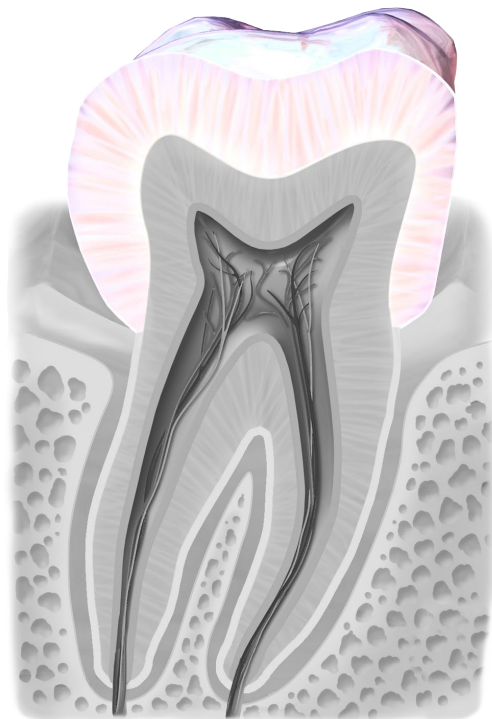
root



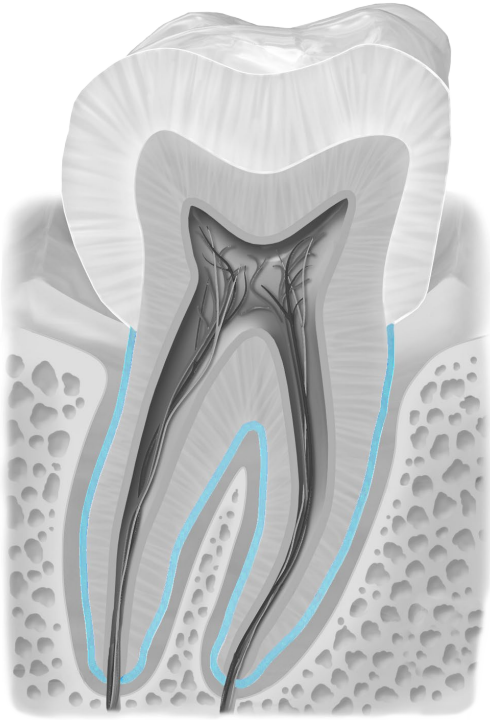
root



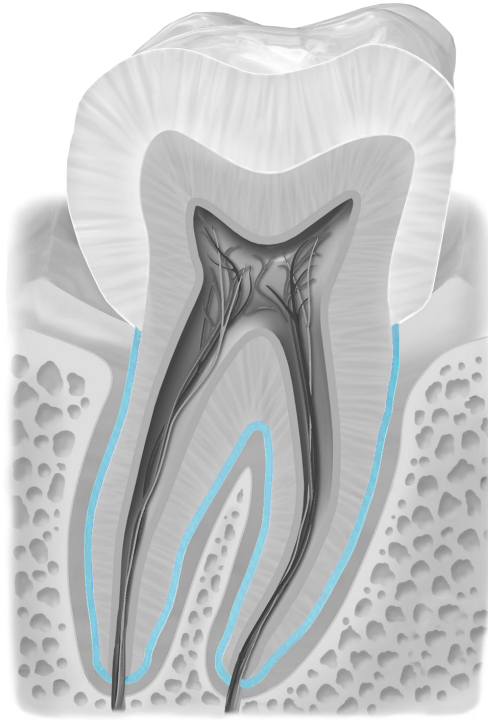
enamel



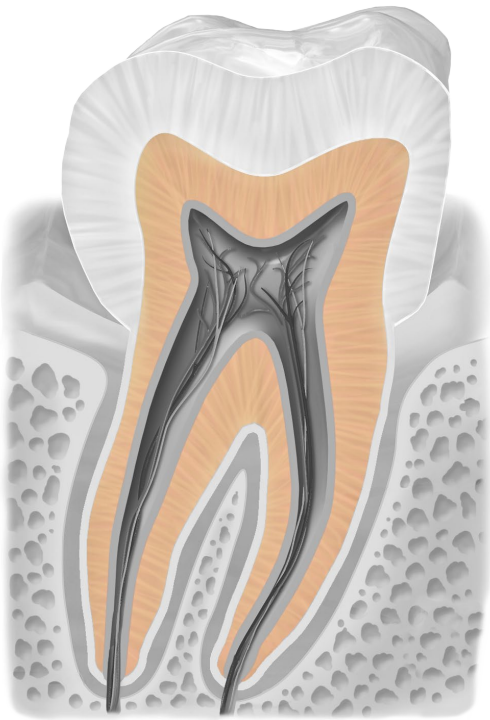
enamel



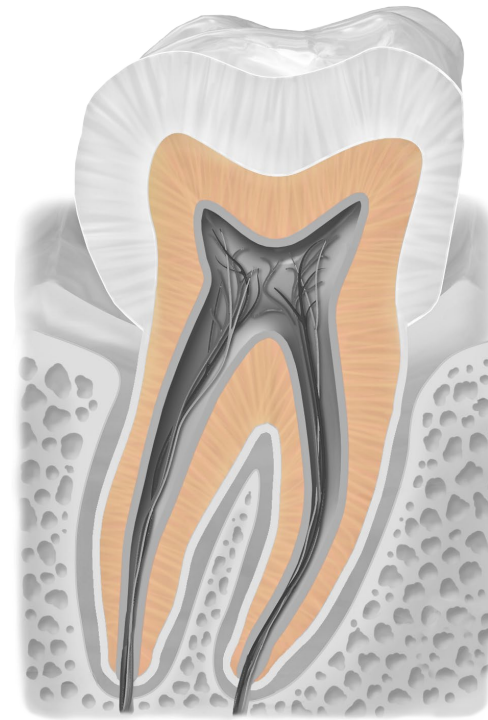
**cementum**



**cementum**

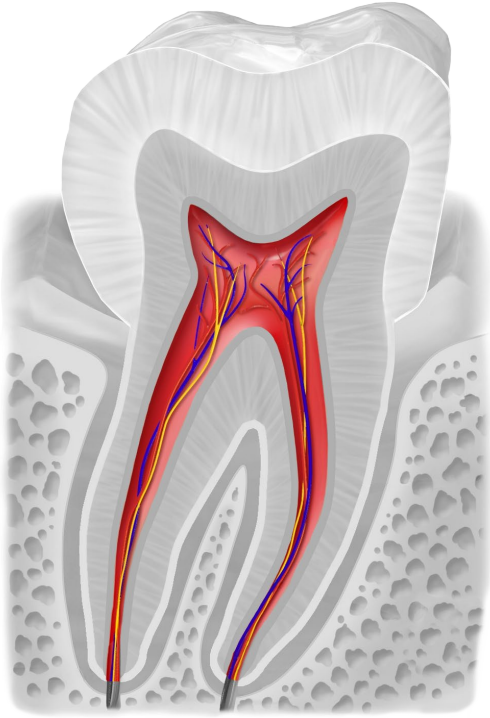


**dentin**

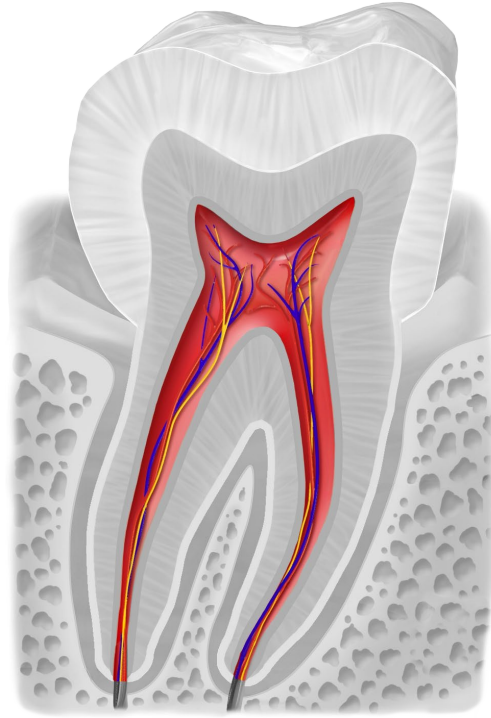


**dentin**

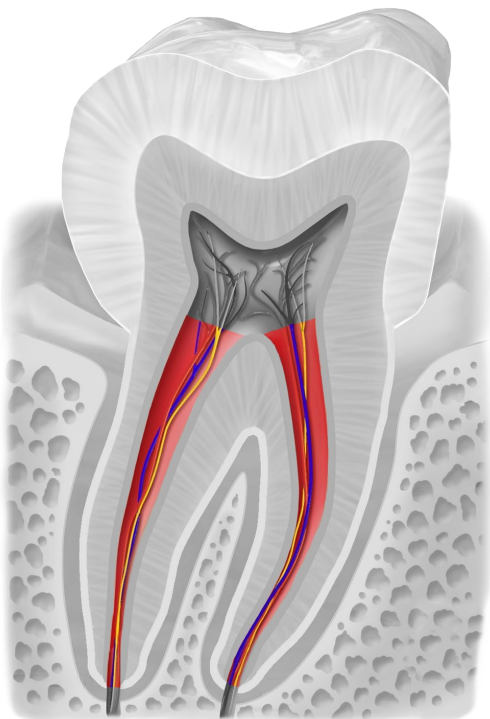




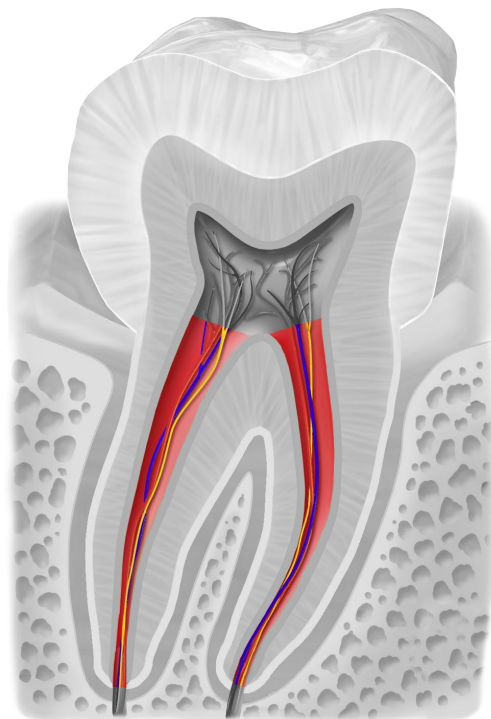
pulp with blood ves-  
sels and nerves



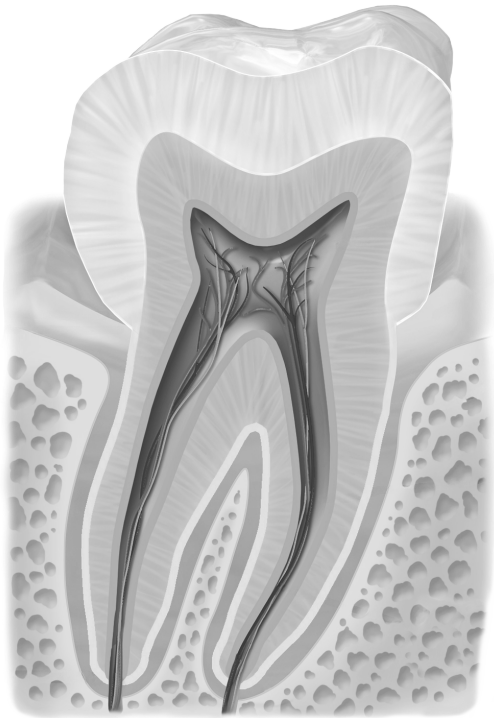
pulp with blood ves-  
sels and nerves



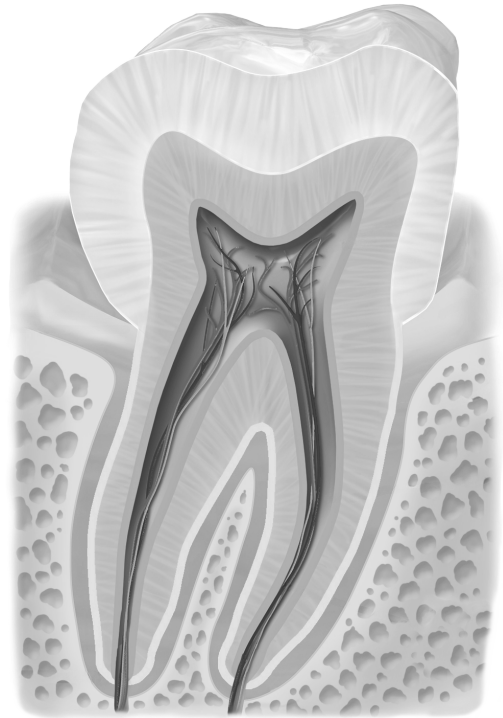root canal



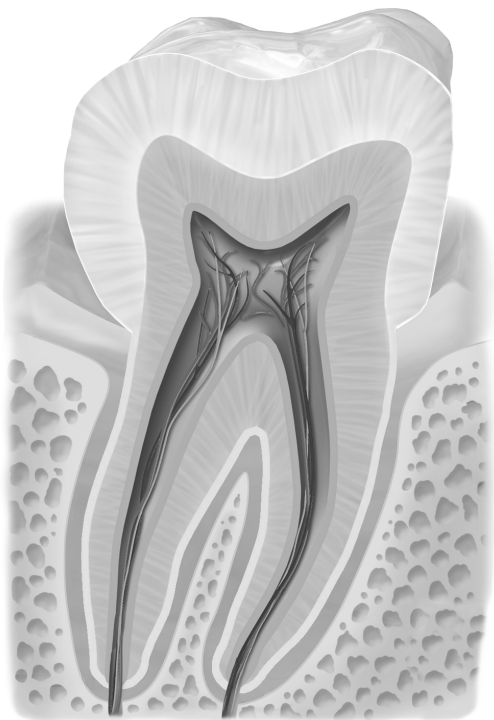
root canal



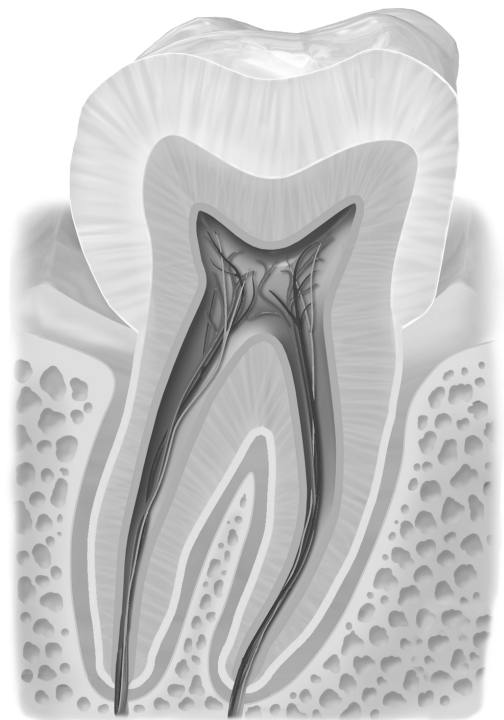
tooth black/white



tooth black/white



tooth black/white



tooth black/white

## Quellen

[BruceBlaus](#). When using this image in external sources it can be cited as:  
Blausen.com staff (2014). "[Medical gallery of Blausen Medical 2014](#)". WikiJournal of  
Medicine 1 (2). [DOI:10.15347/wjm/2014.010](https://doi.org/10.15347/wjm/2014.010). [ISSN 2002-4436](#)., [Blausen 0863](#)  
[ToothAnatomy 02](#), Beschriftung entfernt, Zahn schwarz/weiß eingefärbt und einzelne  
anatomische Teile farbig draufgelegt, [CC BY 3.0](#)