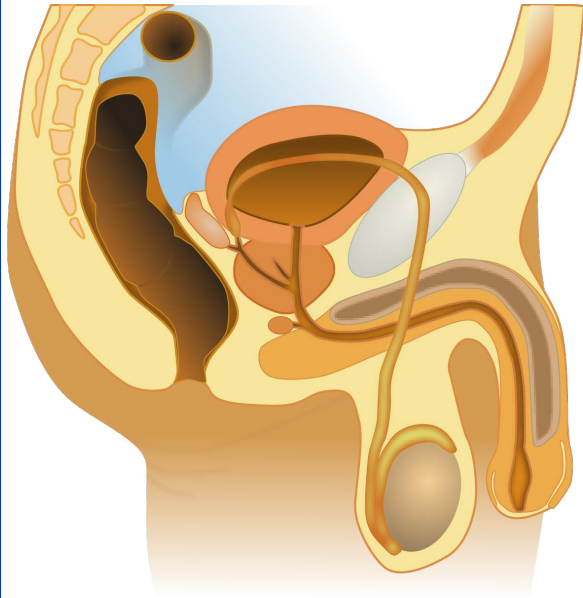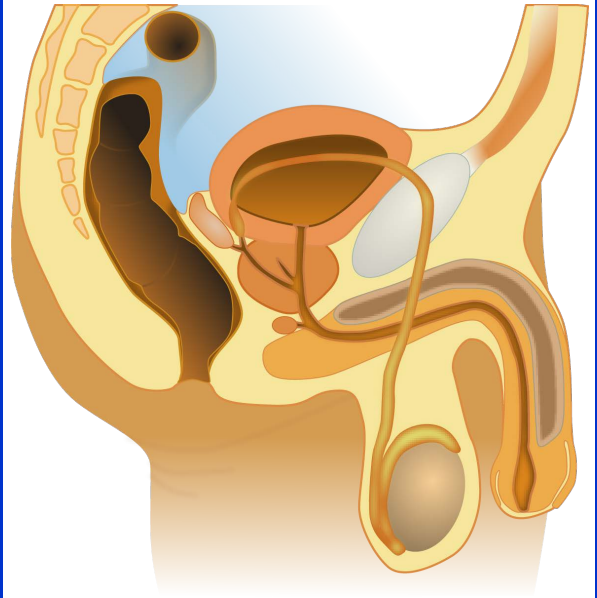
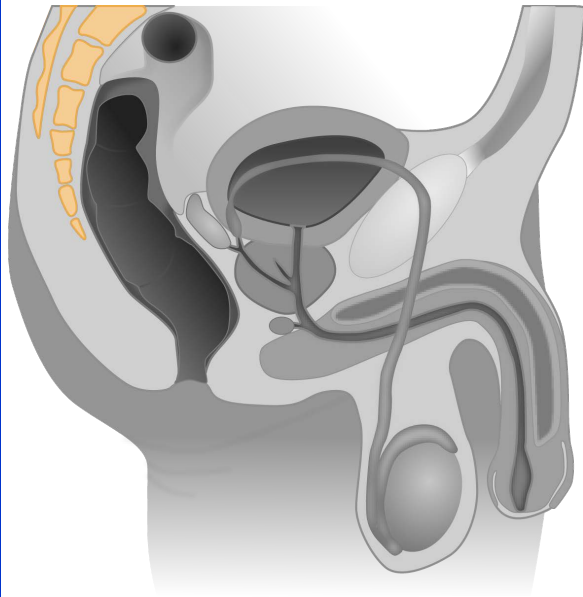


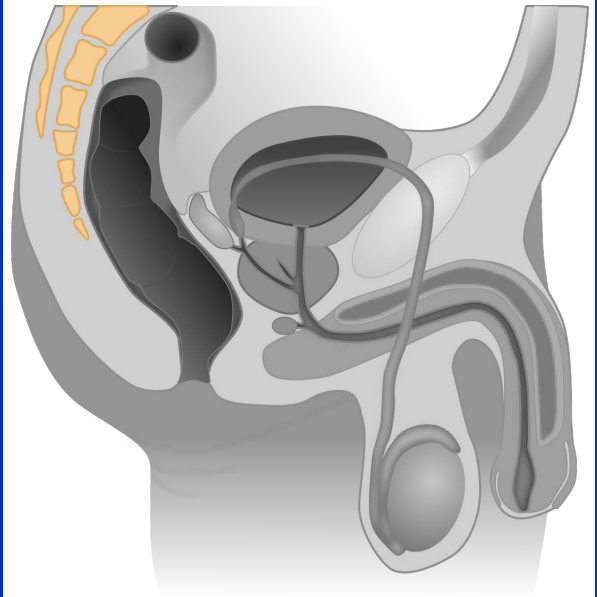
male reproductive
organs



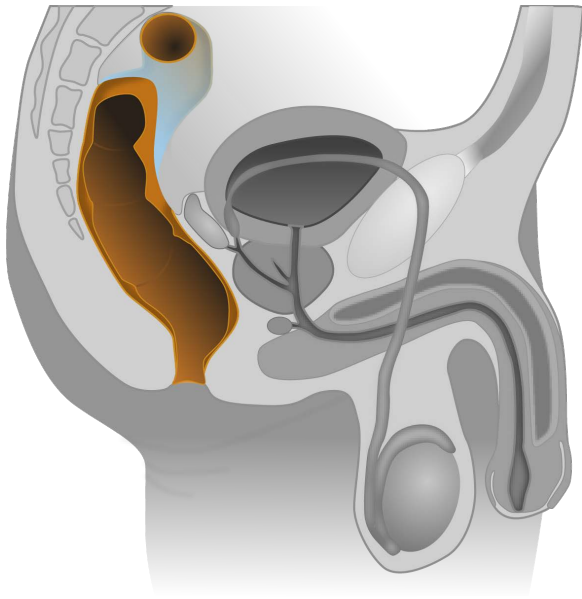
male reproductive
organs



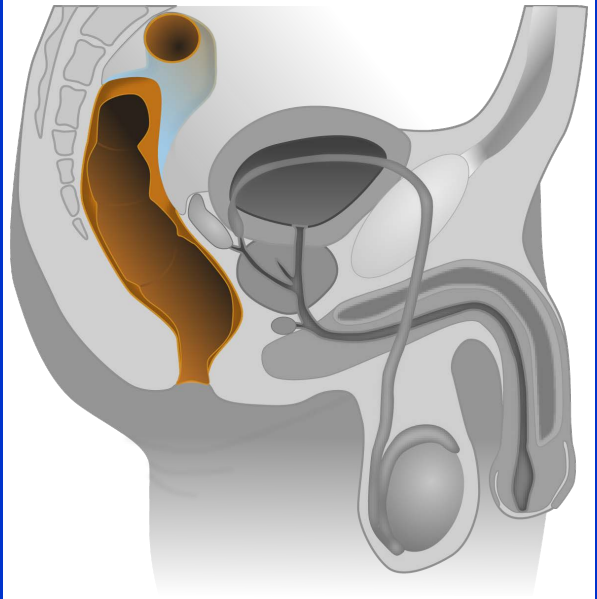
spine



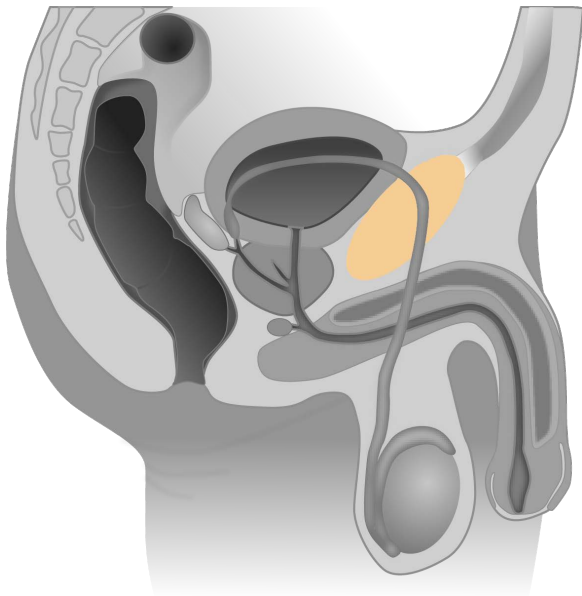
spine



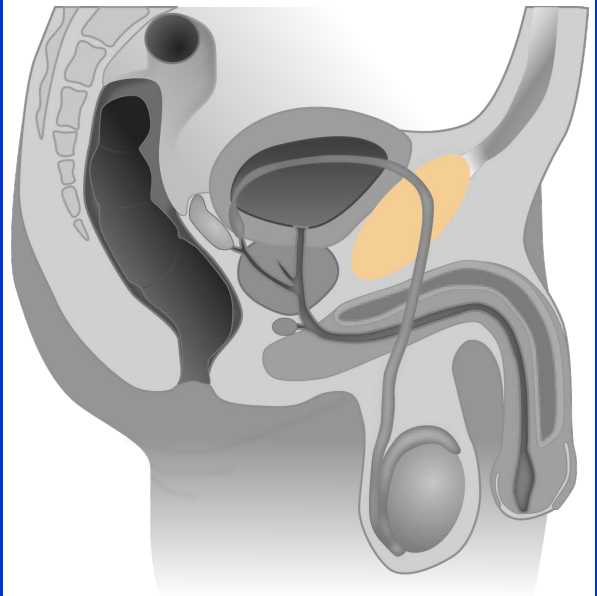
colon



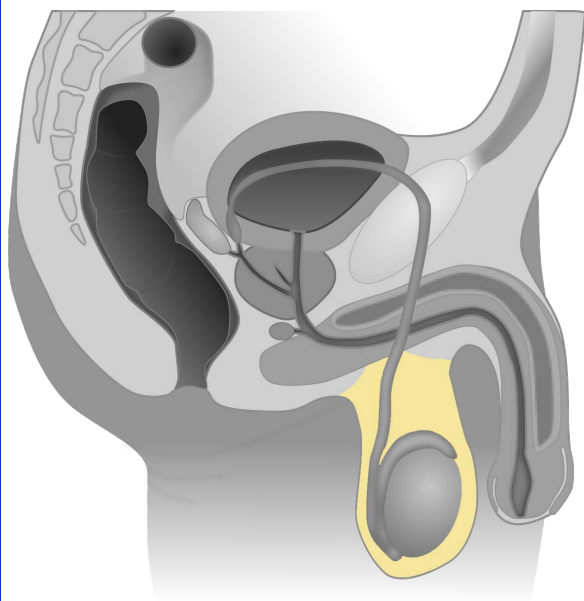
colon



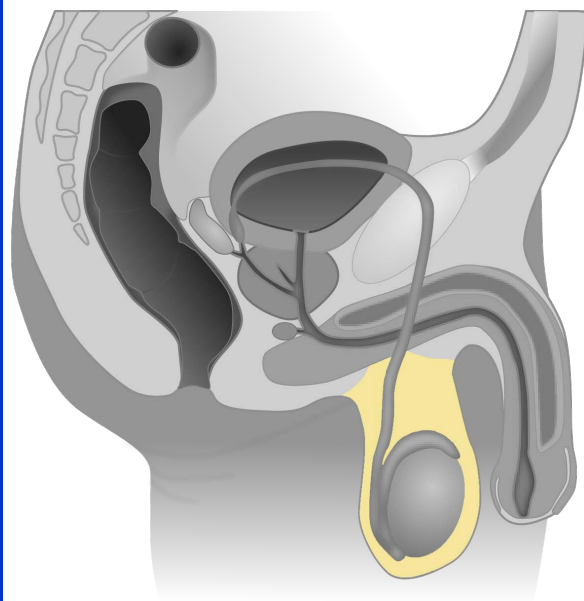
pubic bone



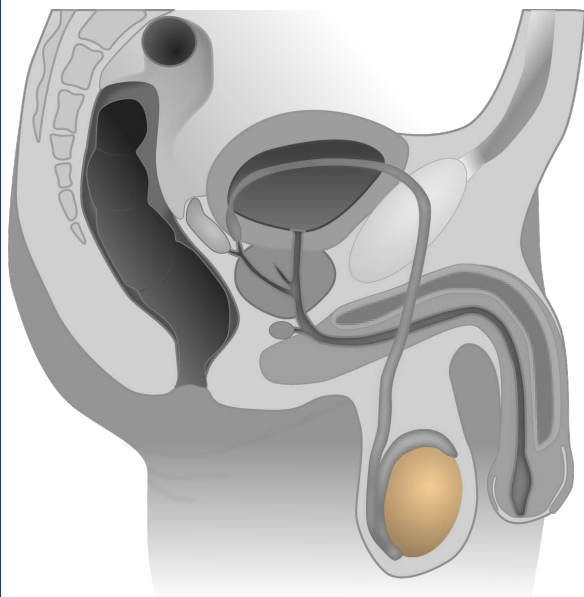
pubic bone



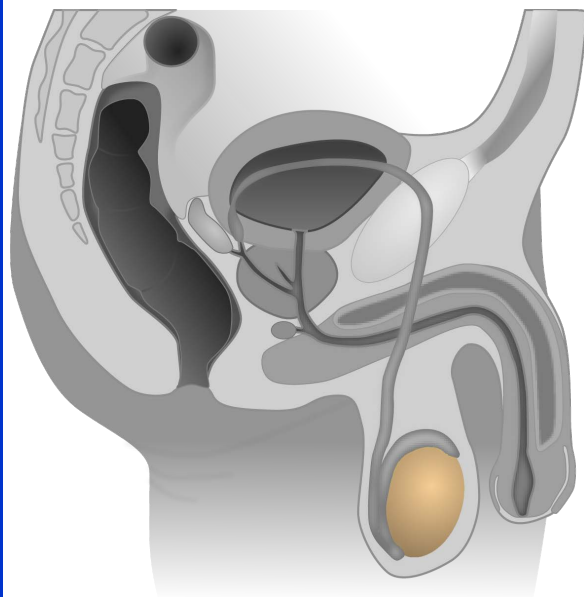
scrotum



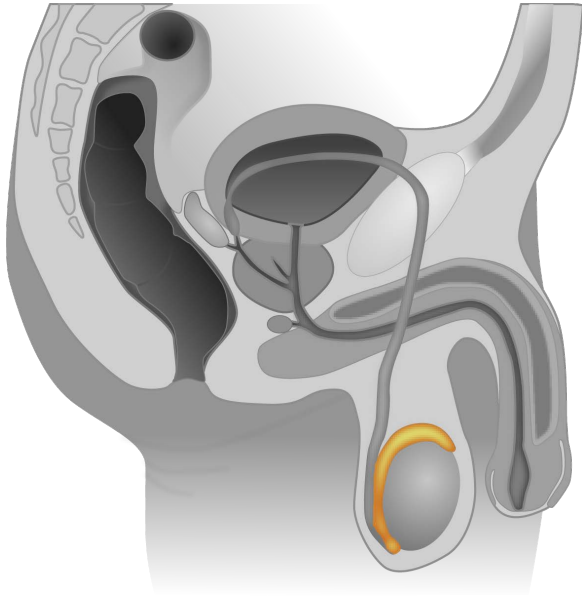
scrotum



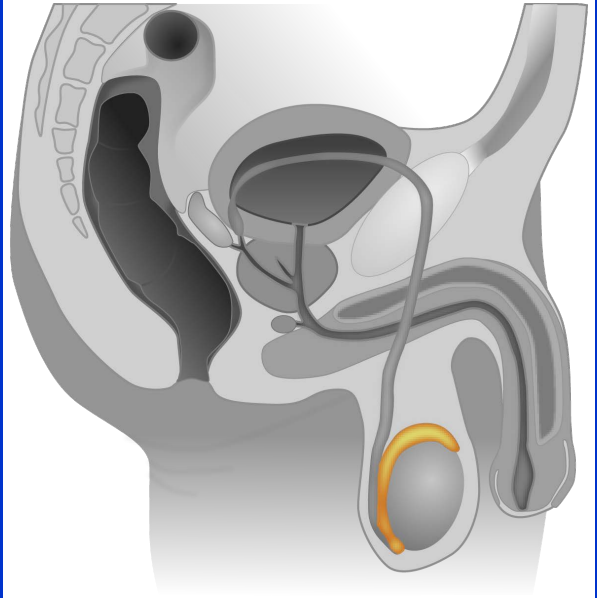
testis



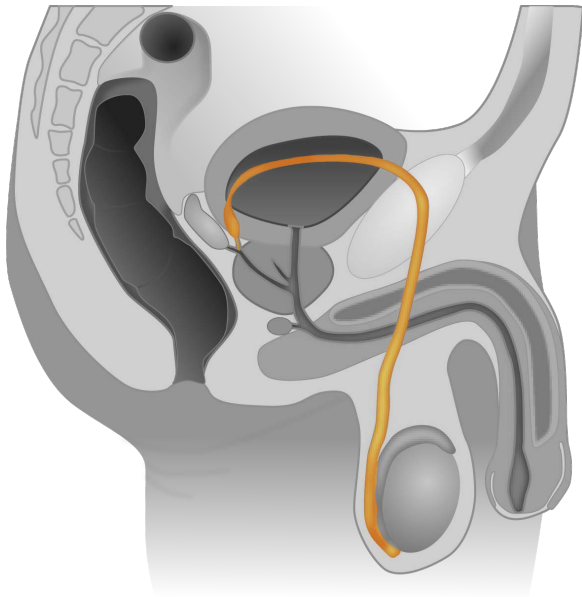
testis



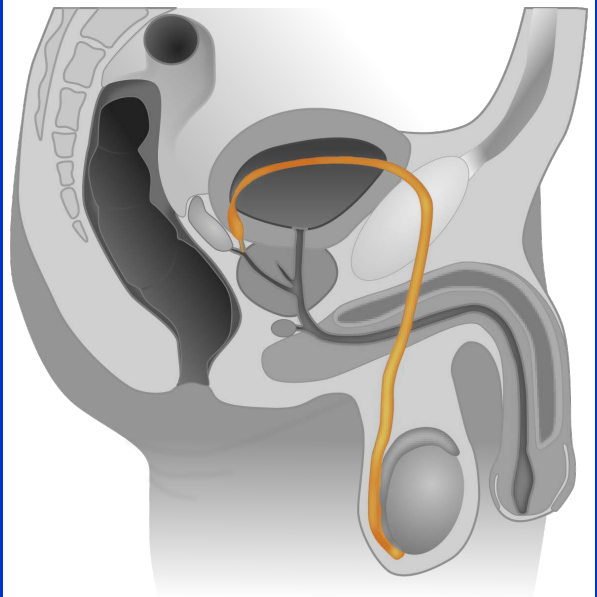
epididymis



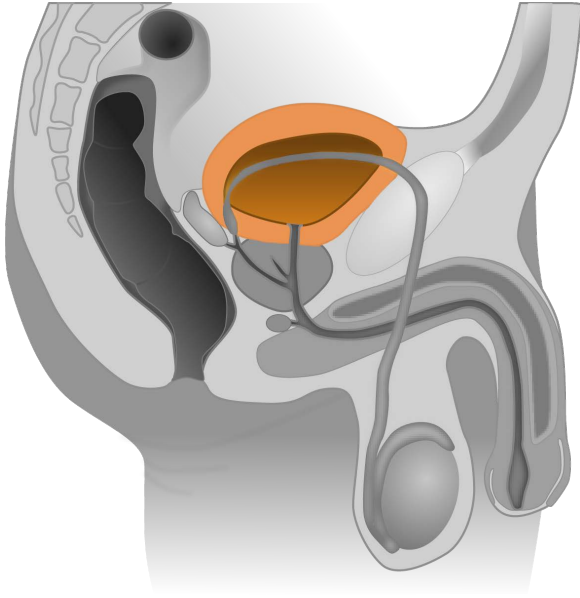
epididymis



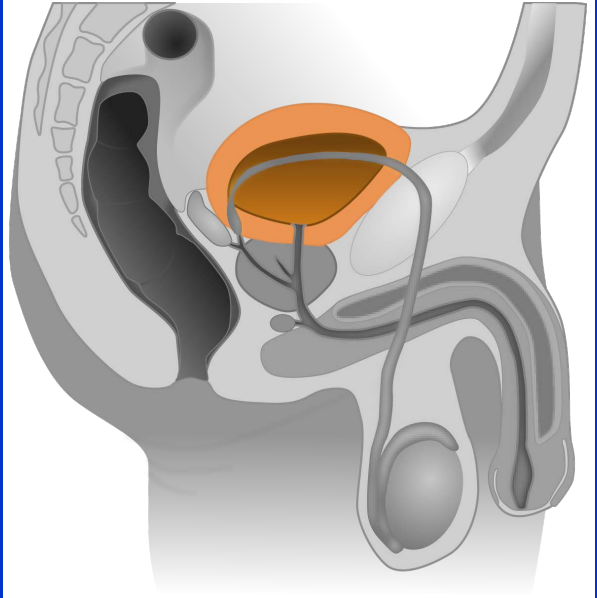
vas deferens



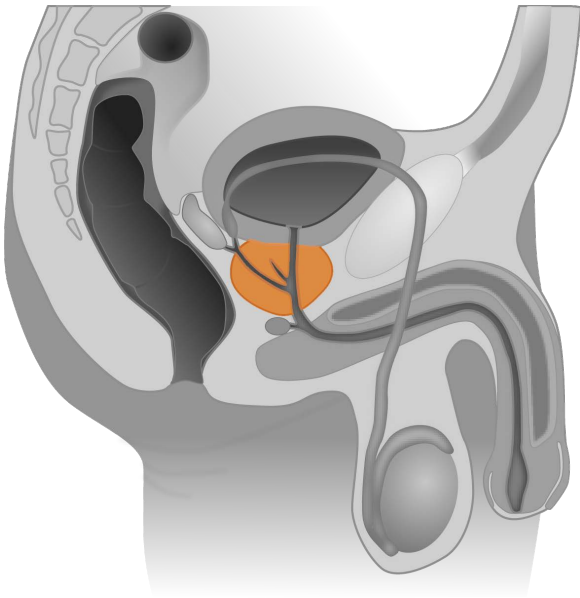
vas deferens



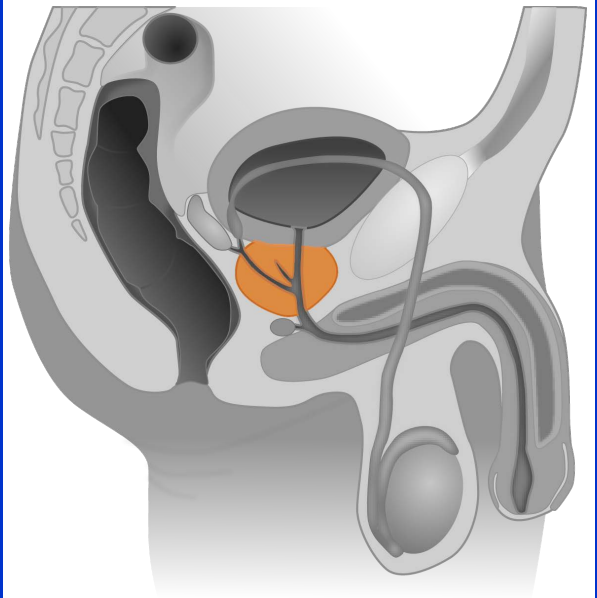
bladder



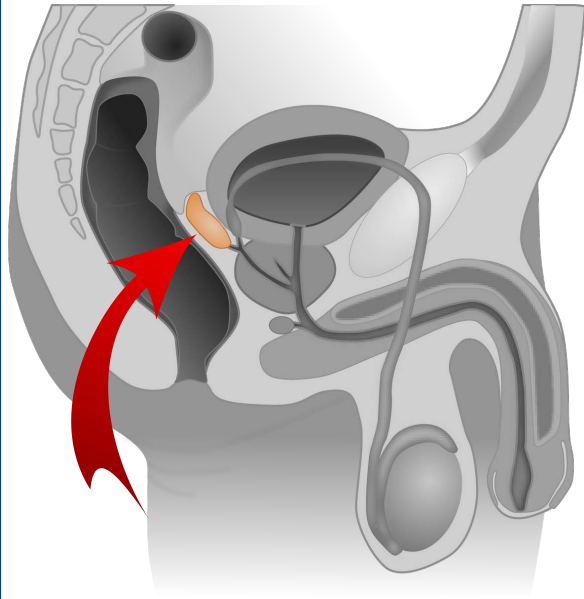
bladder



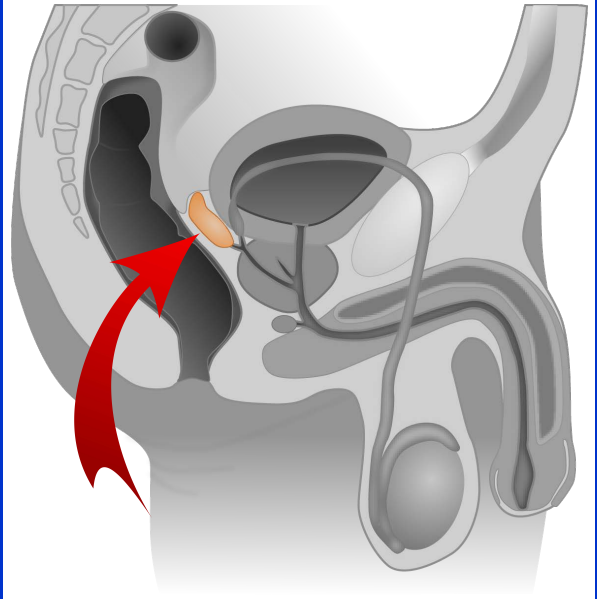
prostate gland



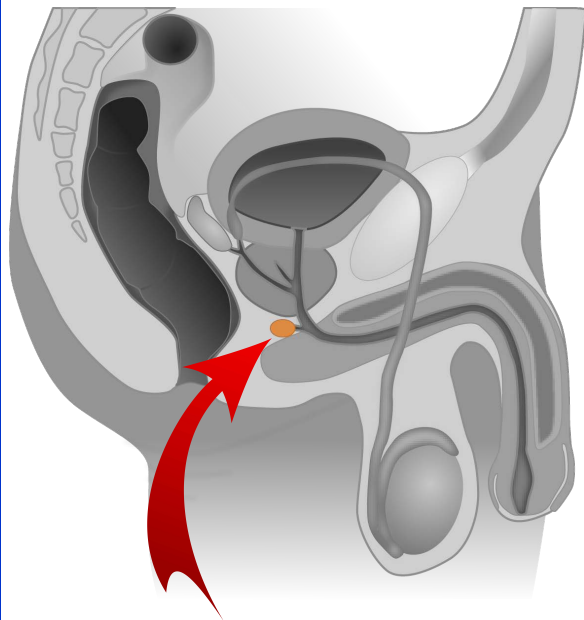
prostate gland



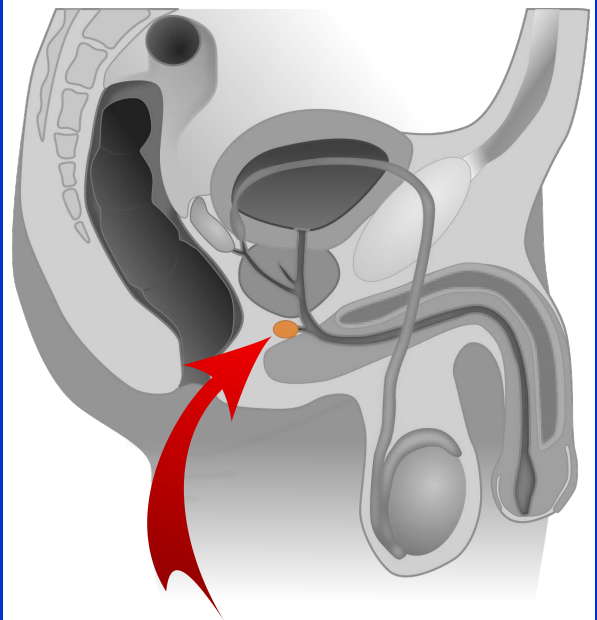
seminal vesicle



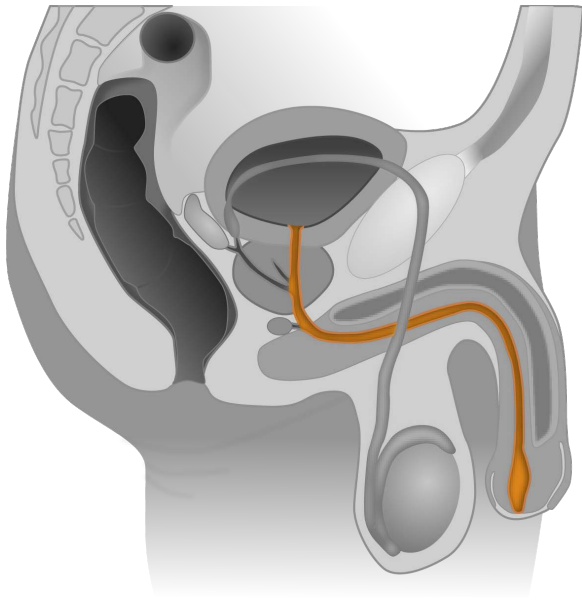
seminal vesicle



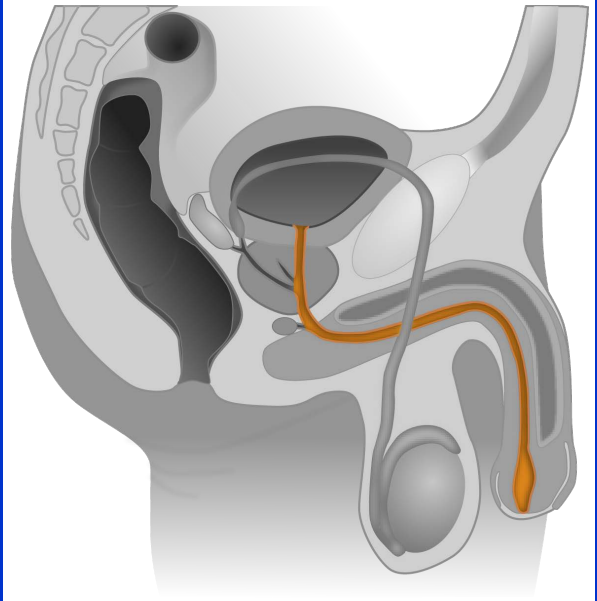
Cowper's gland



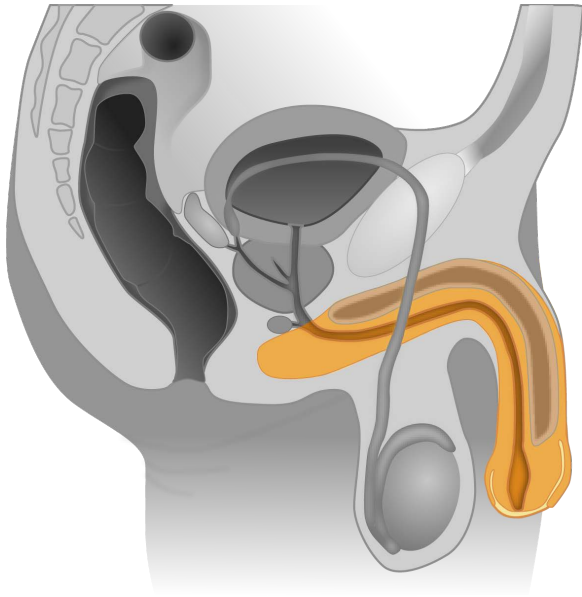
Cowper's gland



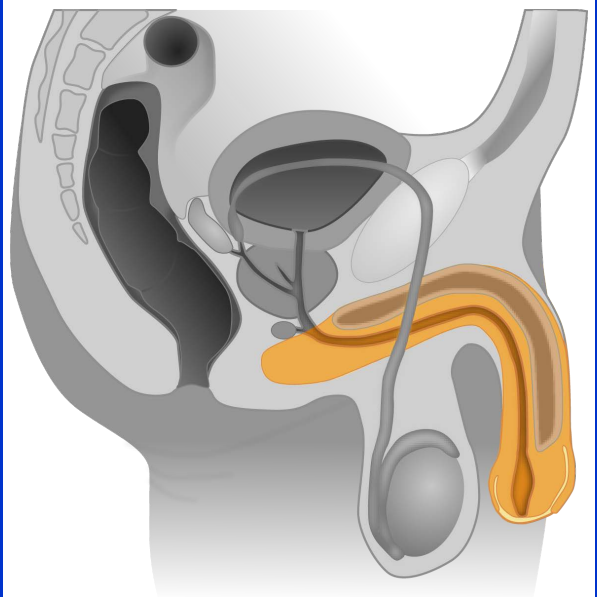
urethra



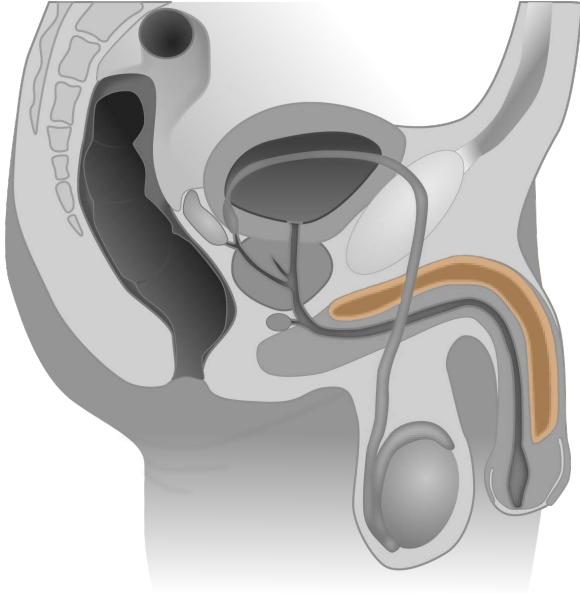
urethra



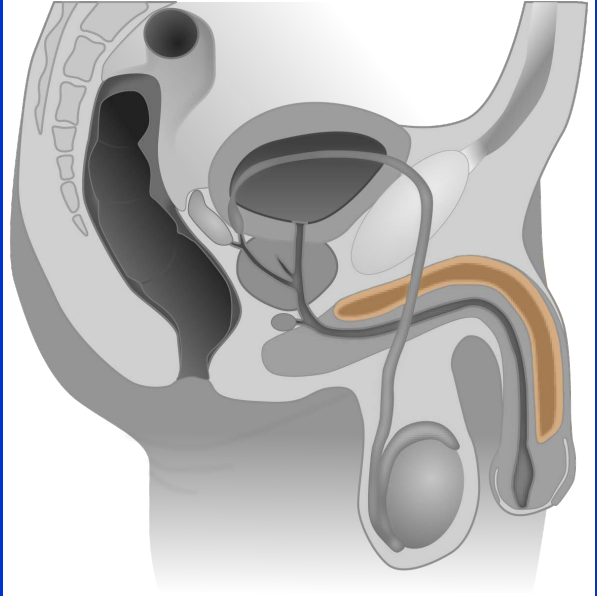
penis



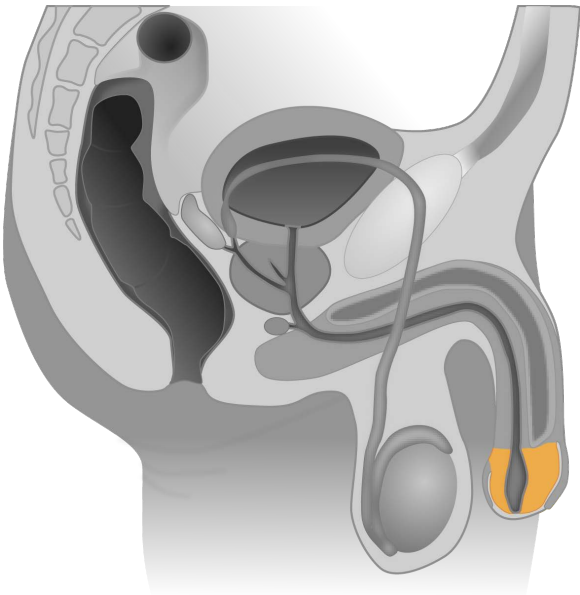
penis



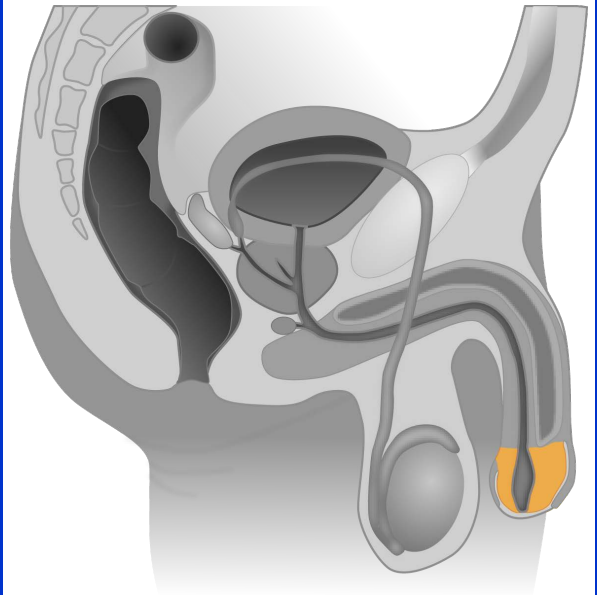
corpus cavernosum



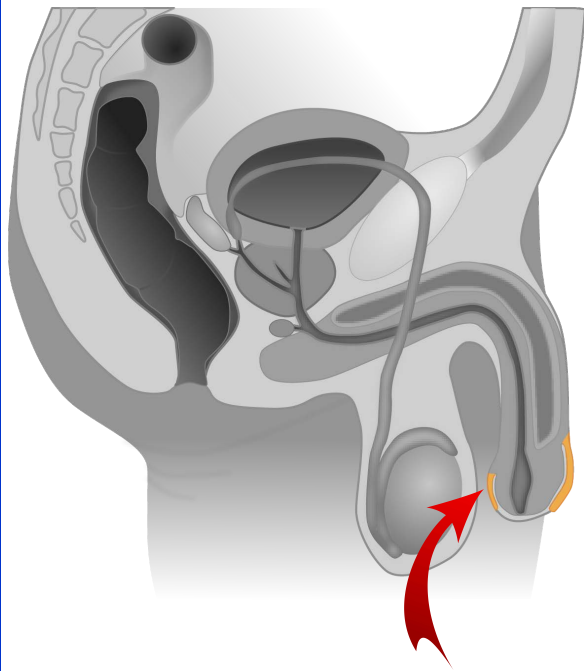
corpus cavernosum



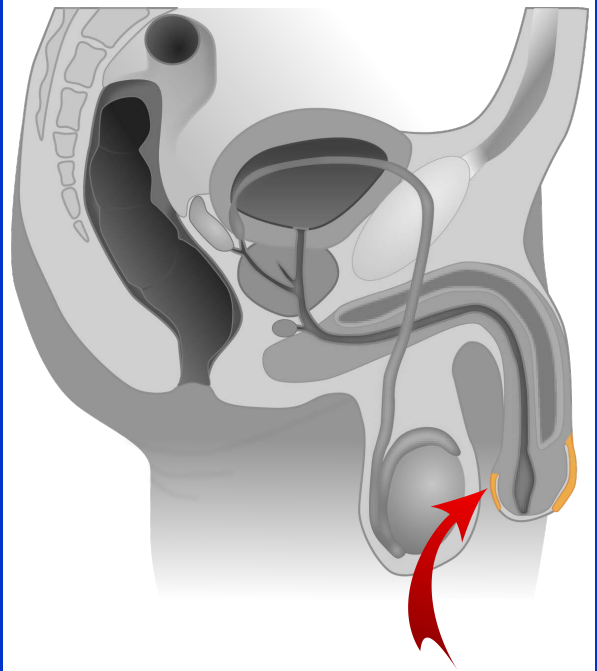
glans penis



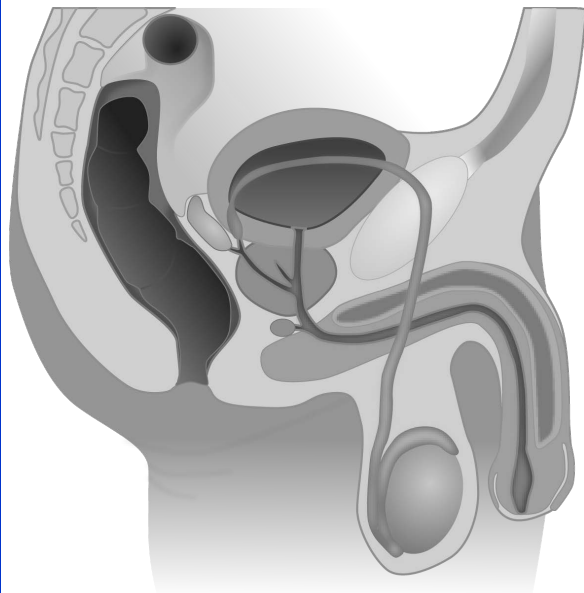
glans penis



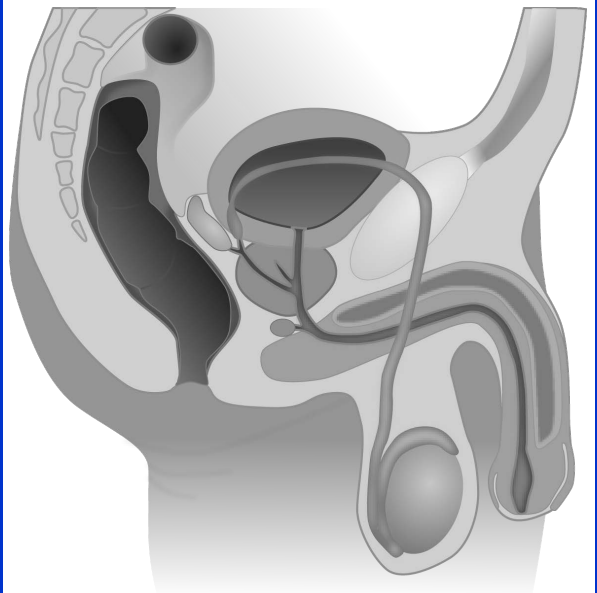
foreskin



foreskin



male reproductive organs, black/white



male reproductive organs, black/white

Quellen

[Tsaitgaist, Male anatomy blank](#), Bild gedreht, schwarz/weiß eingefärbt und einzelne farbige Anatomieteile draufgelegt , [CC BY-SA 3.0](#)

[Arrow Red Up - Free vector graphic on Pixabay](#)