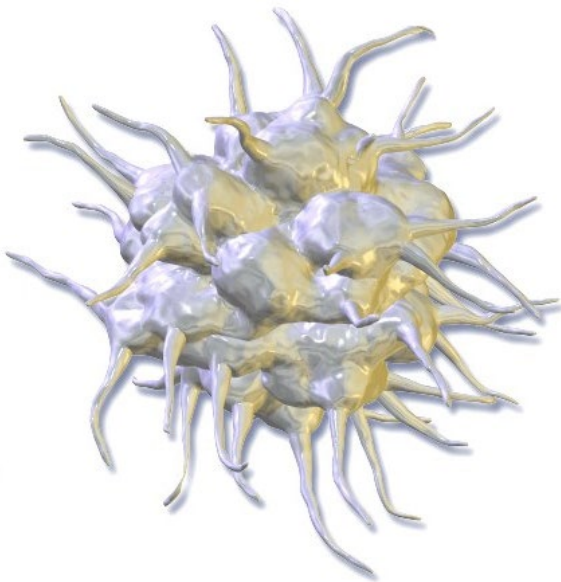




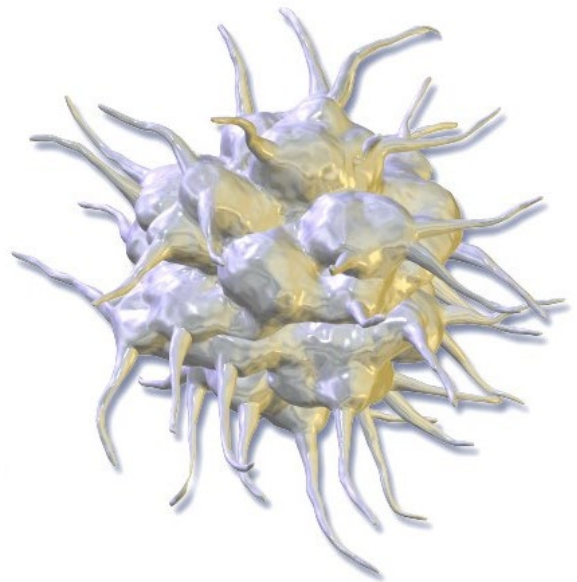
rotes Blutkörperchen



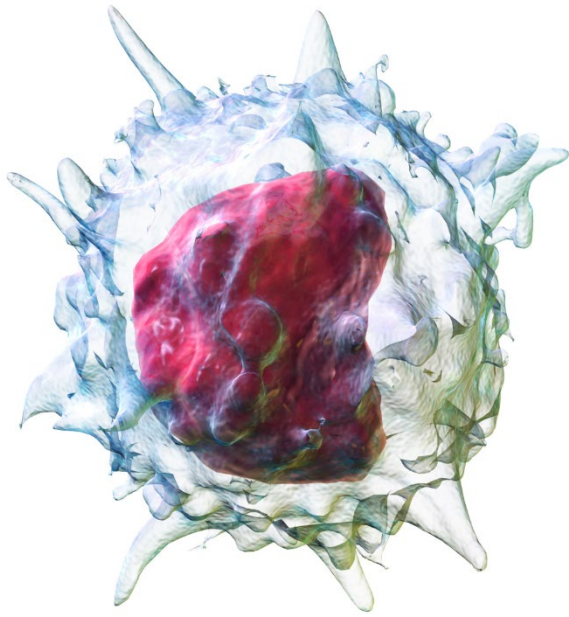
rotes Blutkörperchen



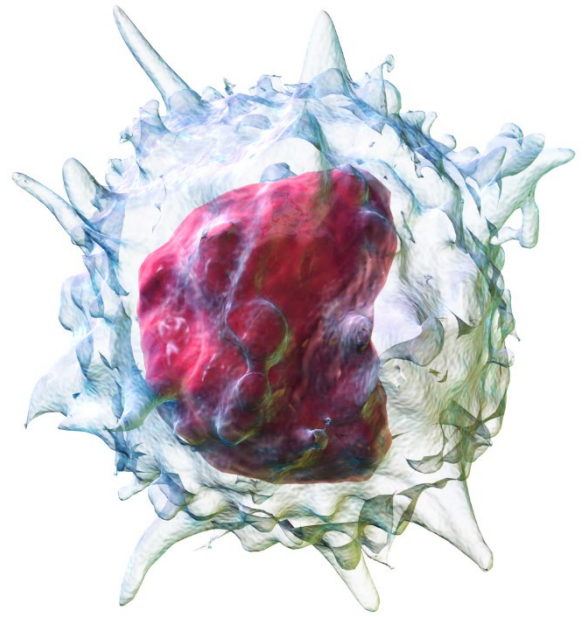
weißes
Blutkörperchen



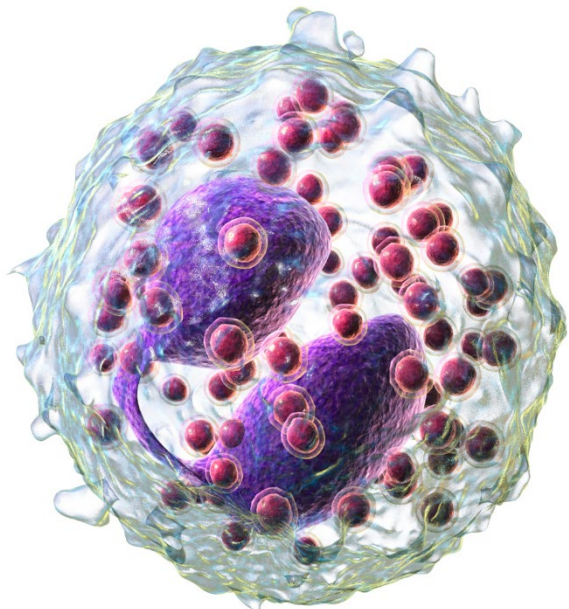
weißes
Blutkörperchen



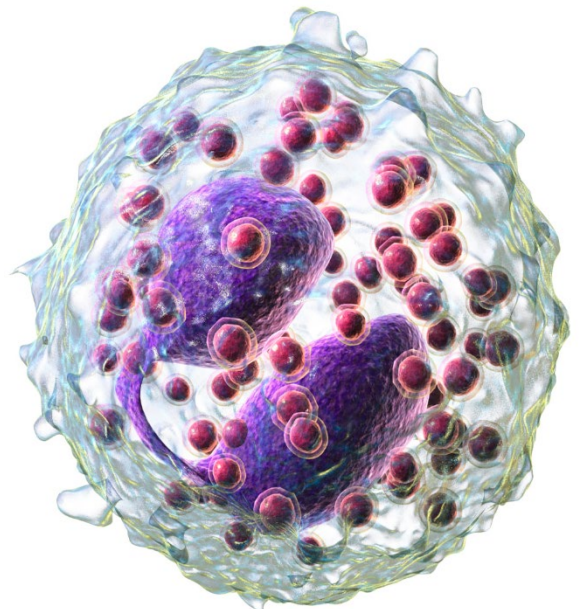
weißes Blutkörperchen
(Monozyt)



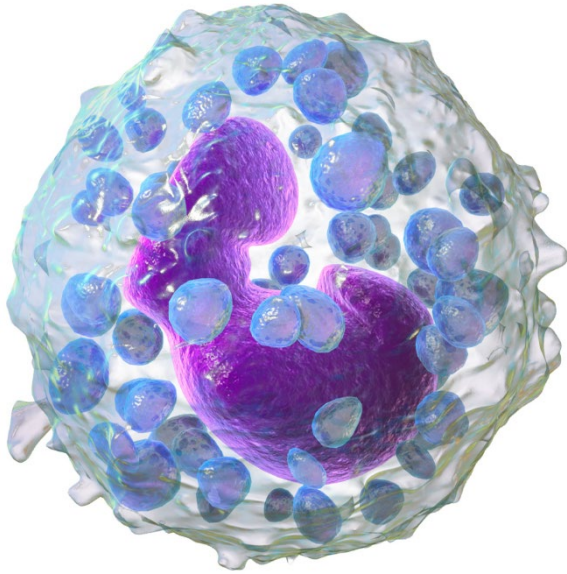
weißes Blutkörperchen
(Monozyt)



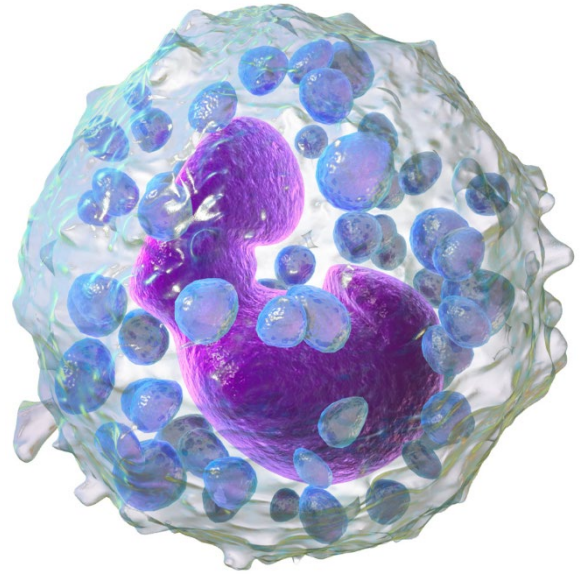
weißes Blutkörperchen
(eosinophiler Granulozyt)



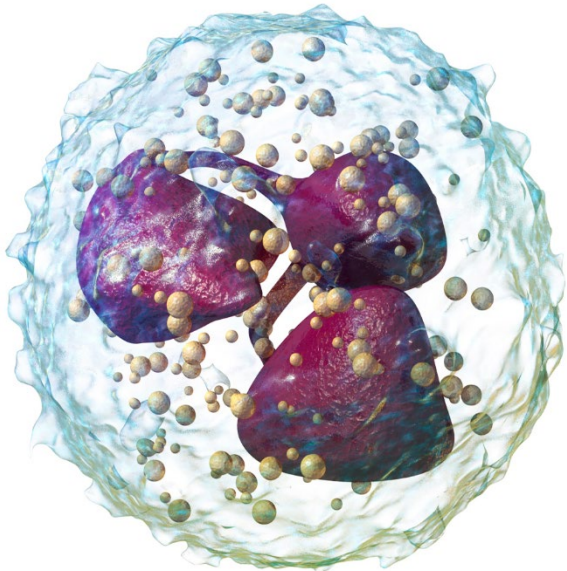
weißes Blutkörperchen
(eosinophiler Granulozyt)



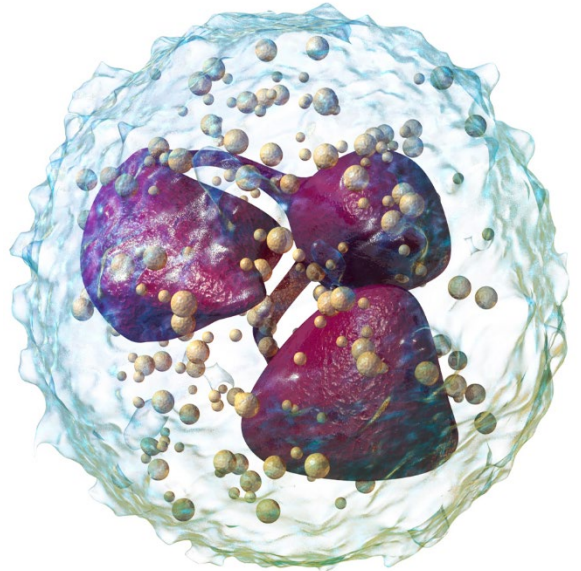
weißes Blutkörperchen
(basophiler Granulozyt)



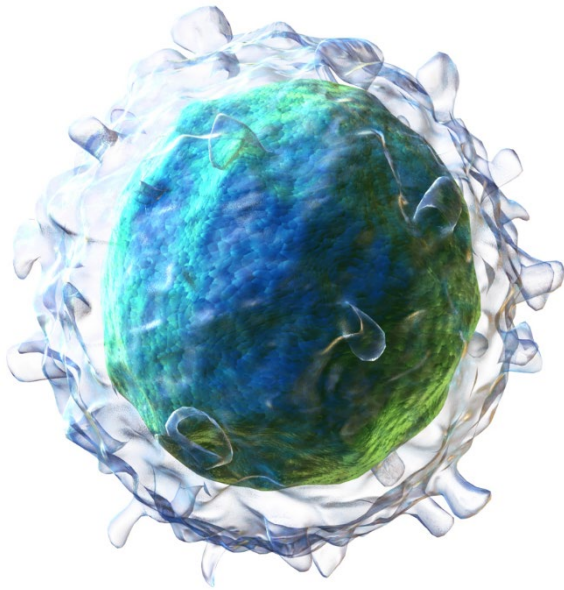
weißes Blutkörperchen
(basophiler Granulozyt)



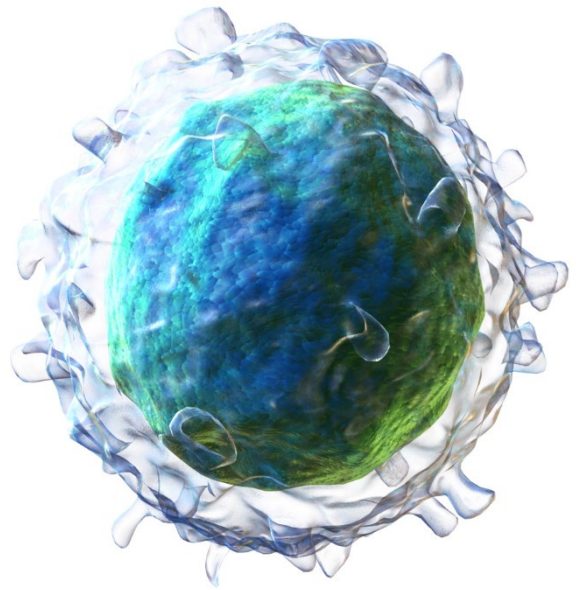
weißes Blutkörperchen
(neutrophiler Granulozyt)



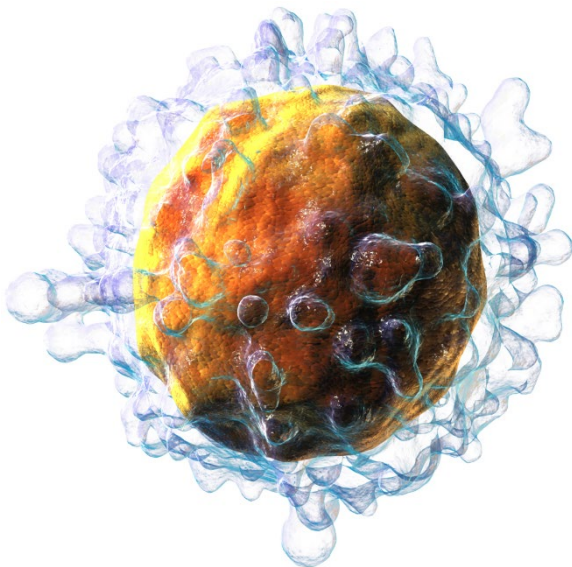
weißes Blutkörperchen
(neutrophiler Granulozyt)



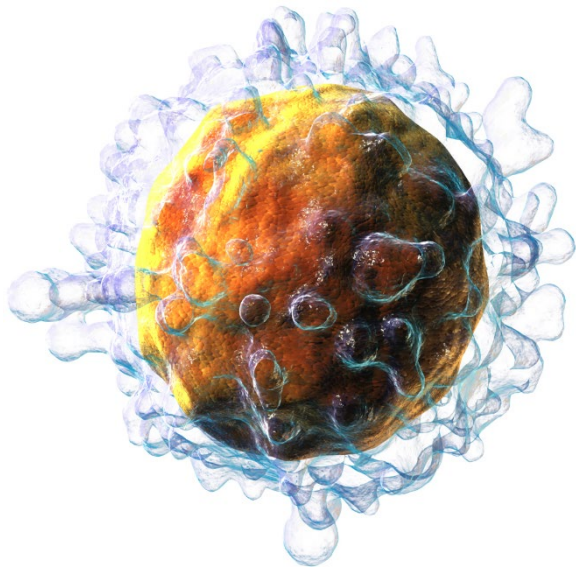
weißes Blutkörperchen
(B-Lymphozyt)



weißes Blutkörperchen
(B-Lymphozyt)



weißes Blutkörperchen
(T-Lymphozyt)



weißes Blutkörperchen
(T-Lymphozyt)

Quellen

[Rogeriopfm](#), [Red blood cell on glass](#), Hintergrund entfernt, Sättigung verstärkt, [CC BY-SA 3.0](#)

[BruceBlaus](#). When using this image in external sources it can be cited as: Blausen.com staff (2014). "[Medical gallery of Blausen Medical 2014](#)". WikiJournal of Medicine 1 (2). DOI:[10.15347/wjm/2014.010](#). ISSN [2002-4436](#)., [Blausen 0740 Platelets](#), Bild zugeschnitten, [CC BY 3.0](#)

Blausen Medical, [Blausen 0649 Monocyte \(crop\)](#), Bild zugeschnitten, [CC BY-SA 4.0](#)

Blausen Medical, [Blausen 0352 Eosinophil \(crop\)](#), Bild zugeschnitten, [CC BY-SA 4.0](#)

Blausen Medical, [Blausen 0077 Basophil \(crop\)](#), Bild zugeschnitten, [CC BY-SA 4.0](#)

Blausen Medical, [Blausen 0676 Neutrophil \(crop\)](#), Bild zugeschnitten, [CC BY-SA 4.0](#)

Blausen Medical, [Blausen 0624 Lymphocyte B cell \(crop\)](#), Bild zugeschnitten, [CC BY-SA 4.0](#)

Blausen Medical, [Blausen 0625 Lymphocyte T cell \(crop\)](#), Bild zugeschnitten, [CC BY 3.0](#)