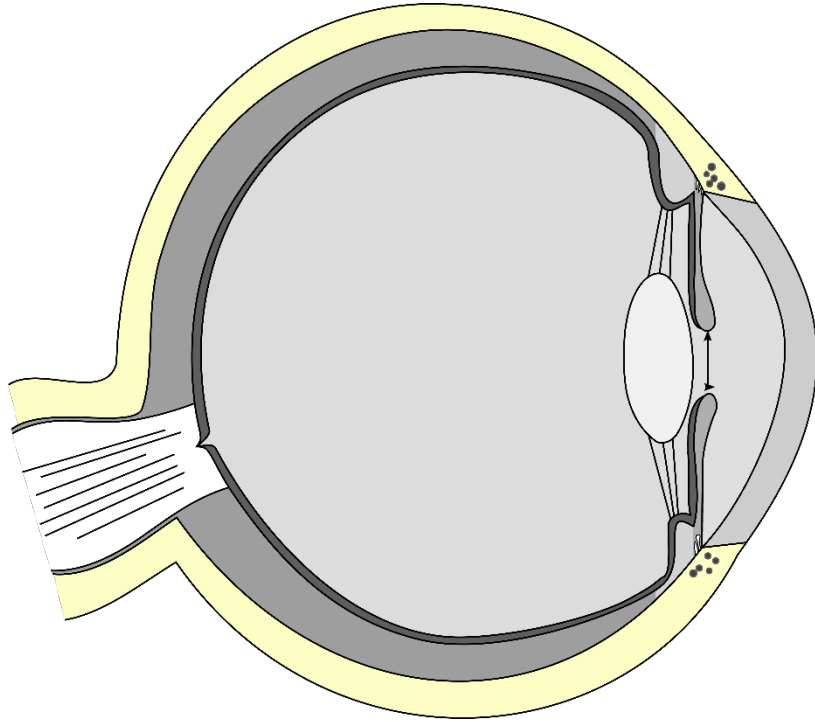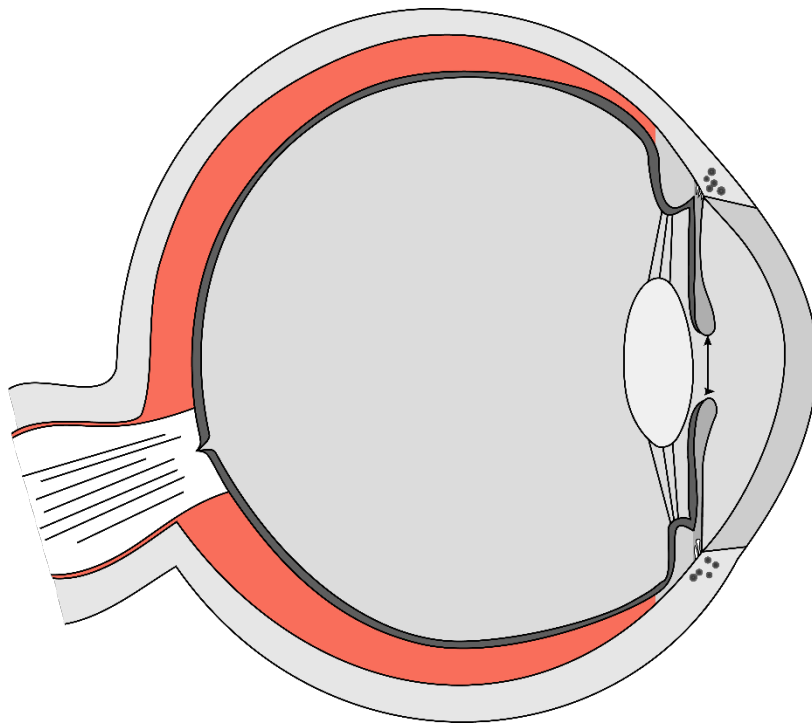
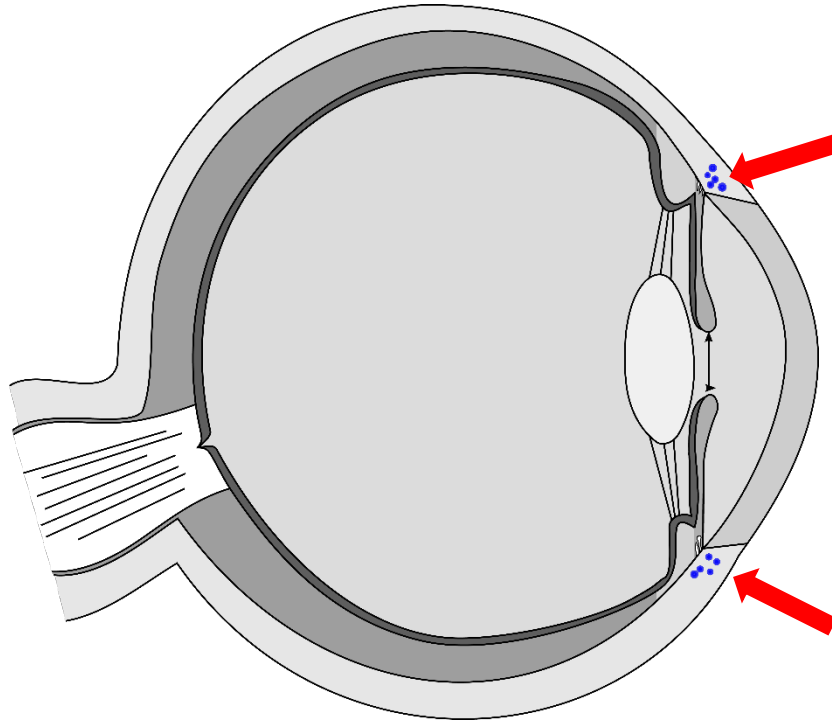


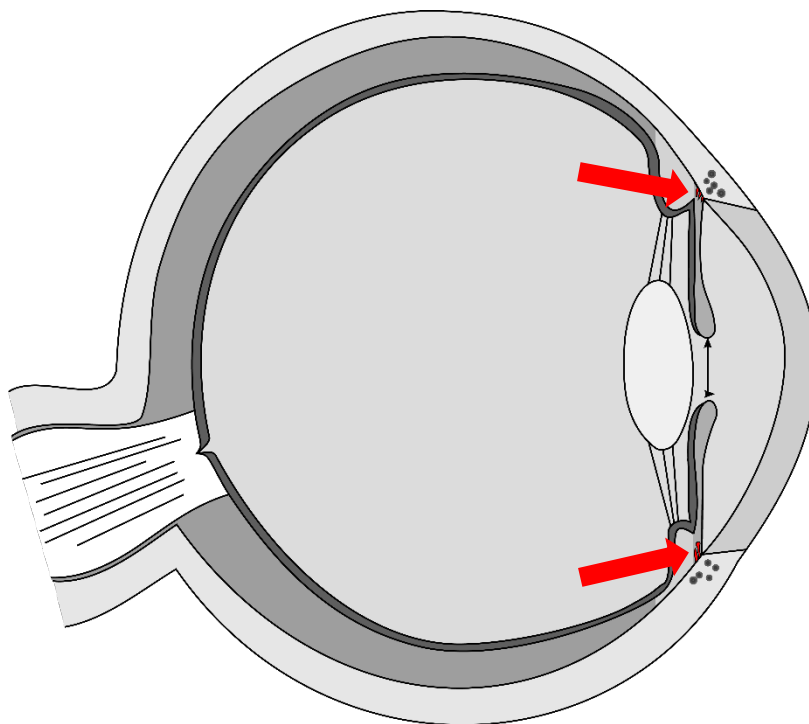
Lederhaut



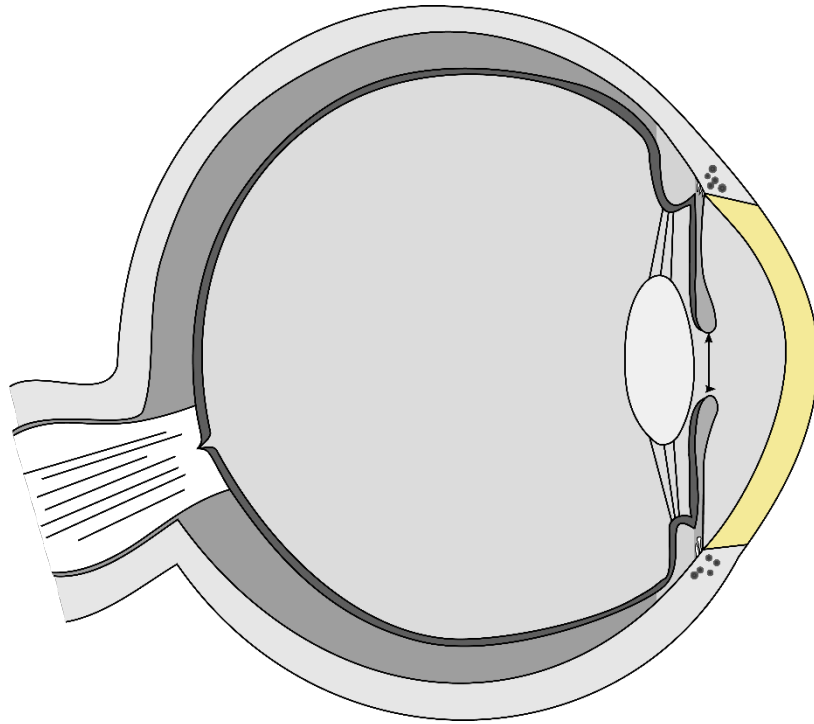
Aderhaut



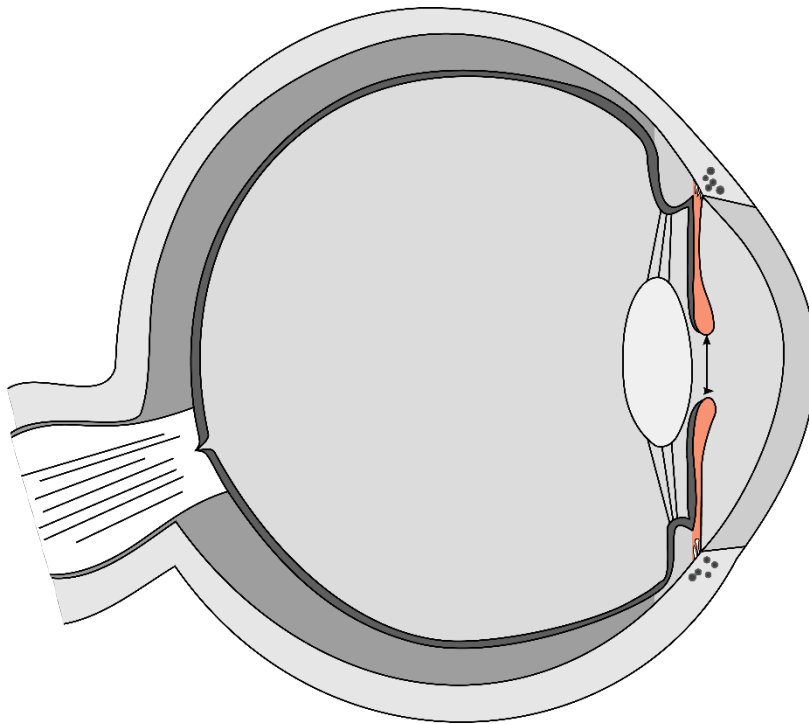
Schlemm-Kanal



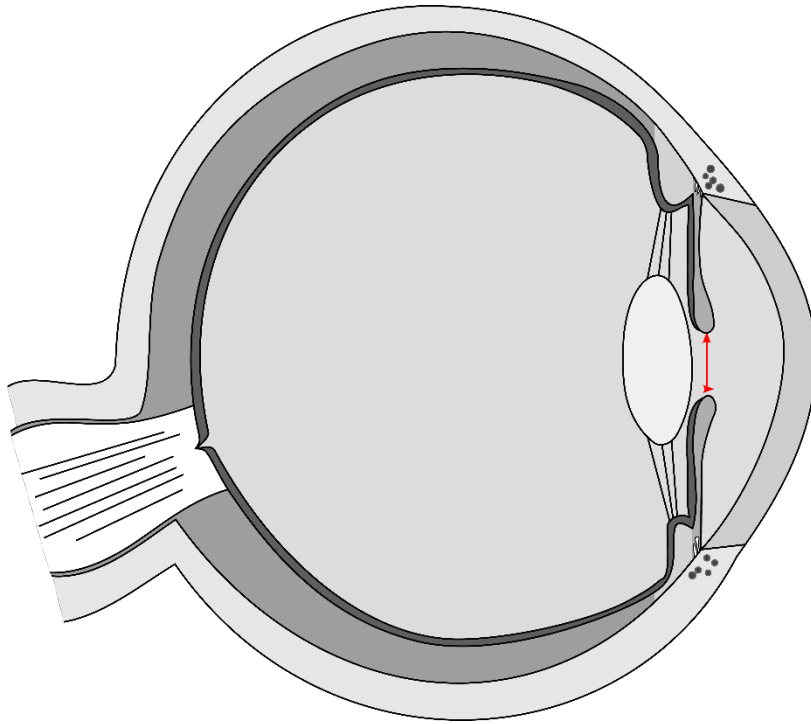
Iriswurzel



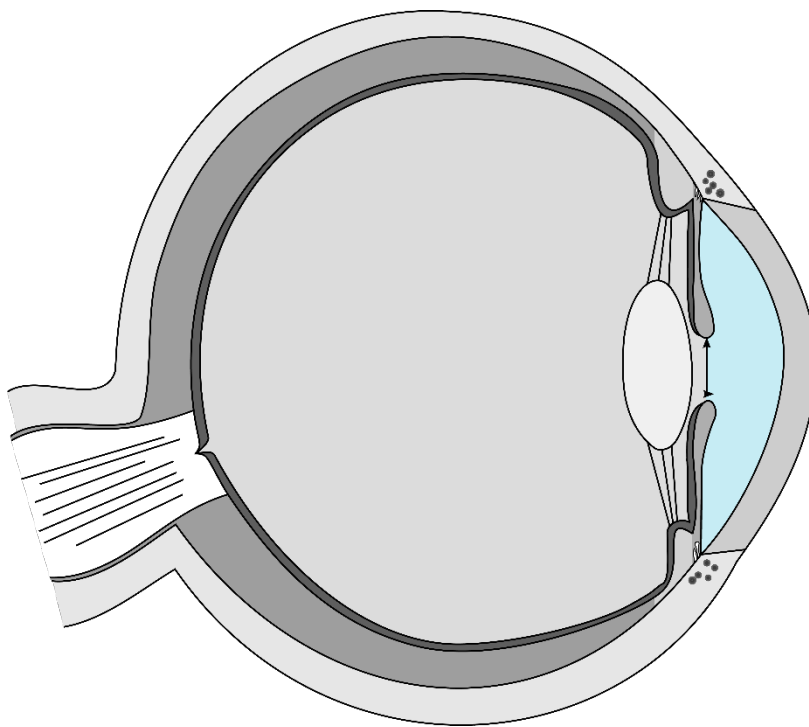
Hornhaut



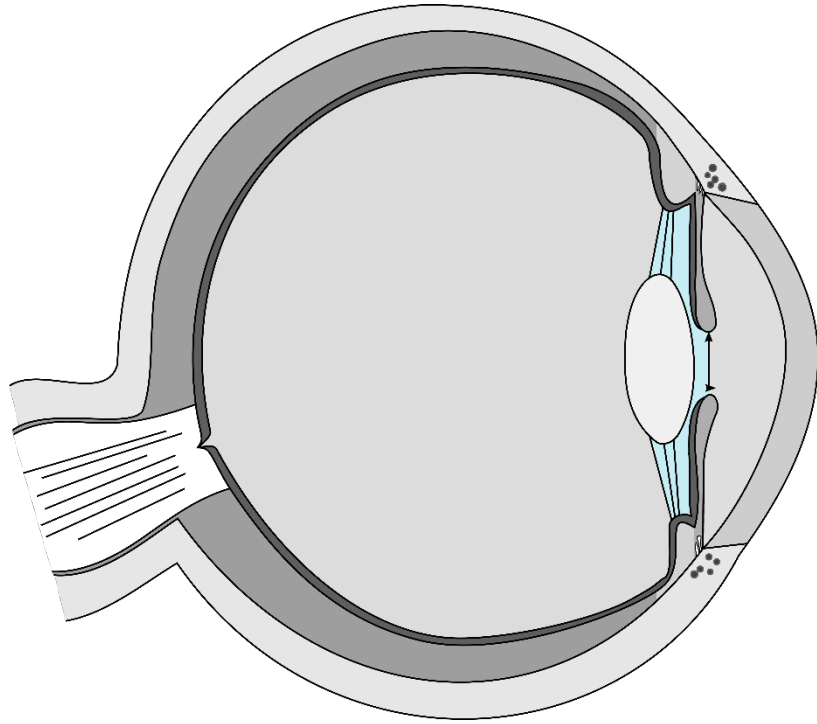
Regenbogenhaut



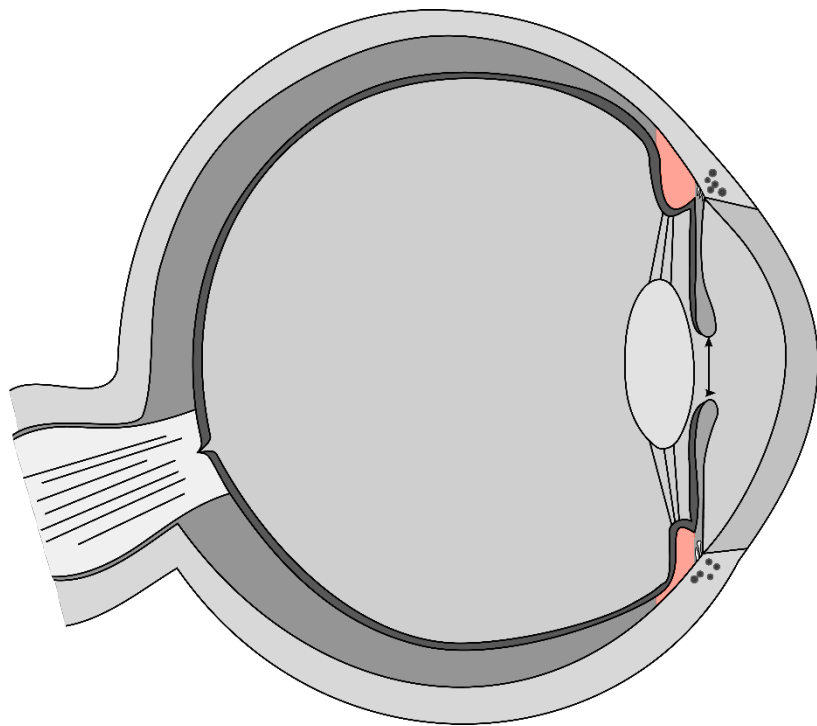
Pupille



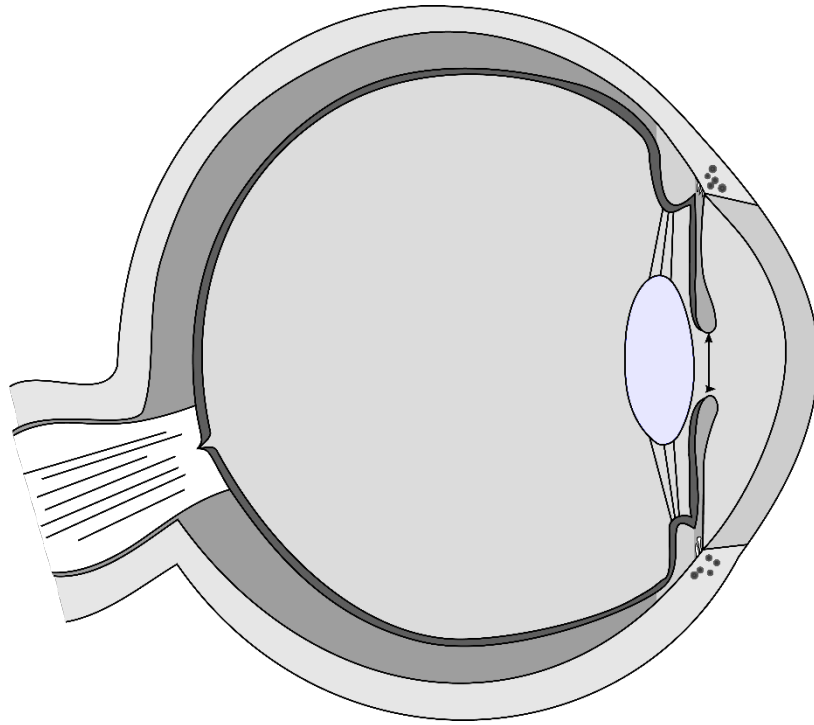
vordere Augenkammer



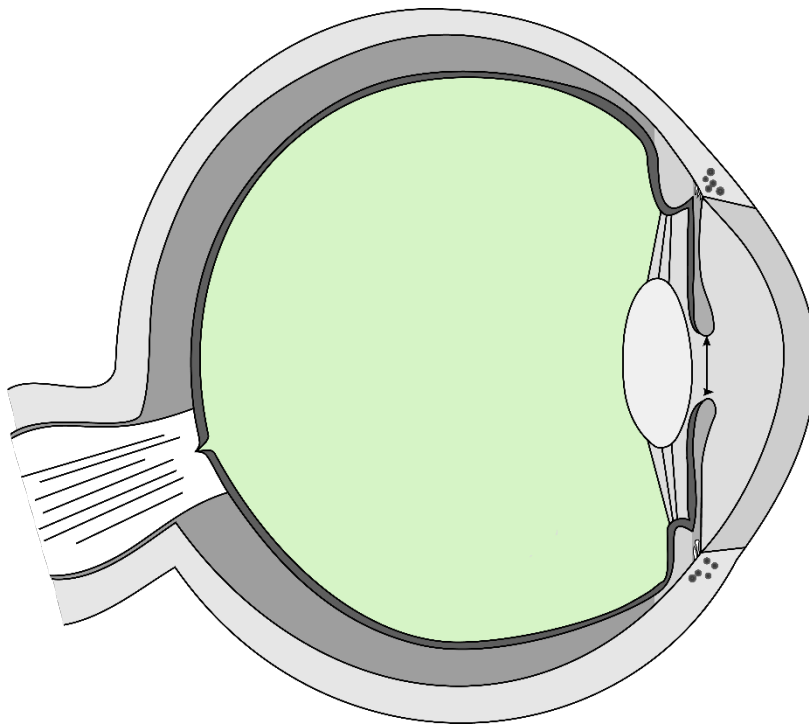
hintere Augenkammer



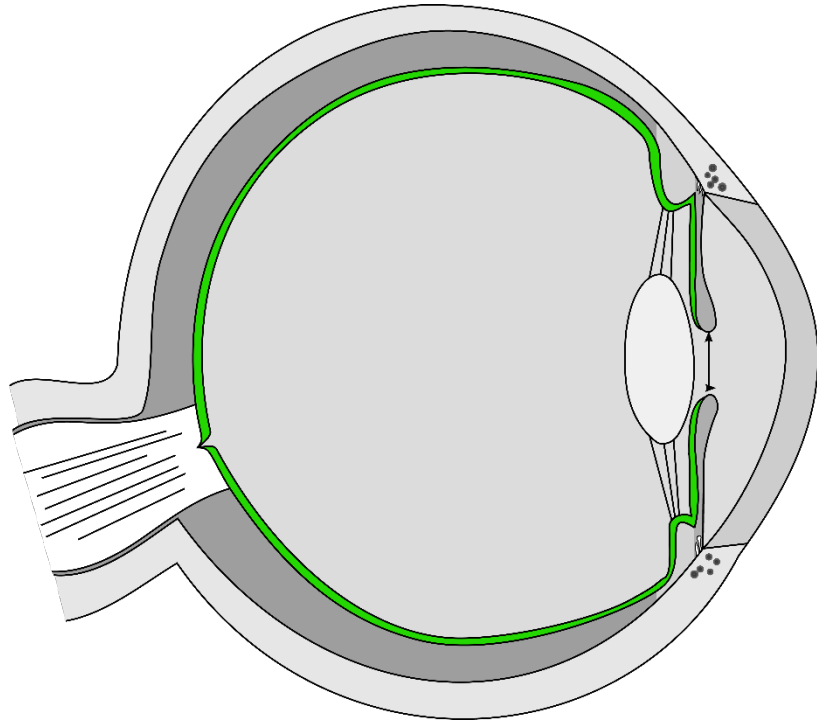
Ziliarkörper



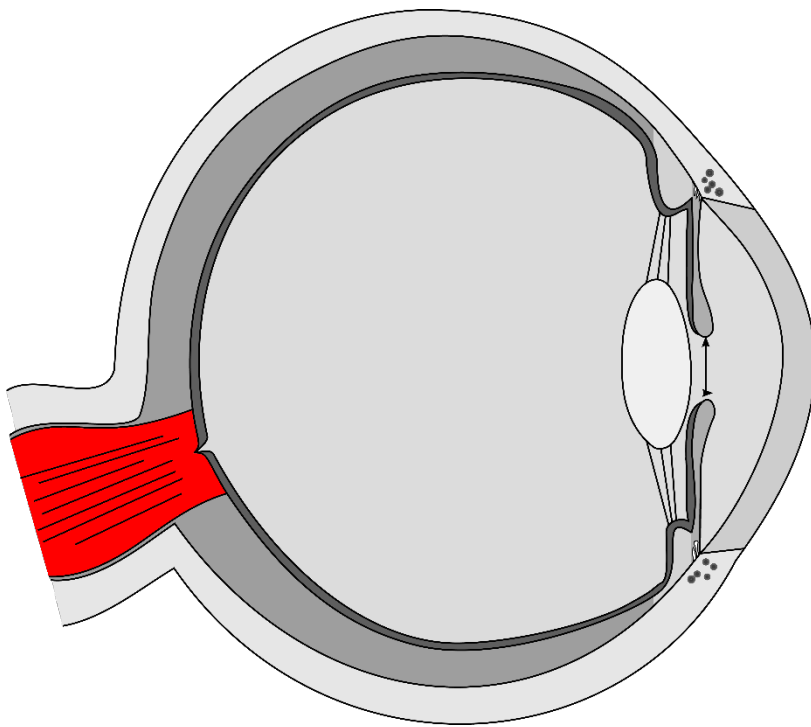
Linse



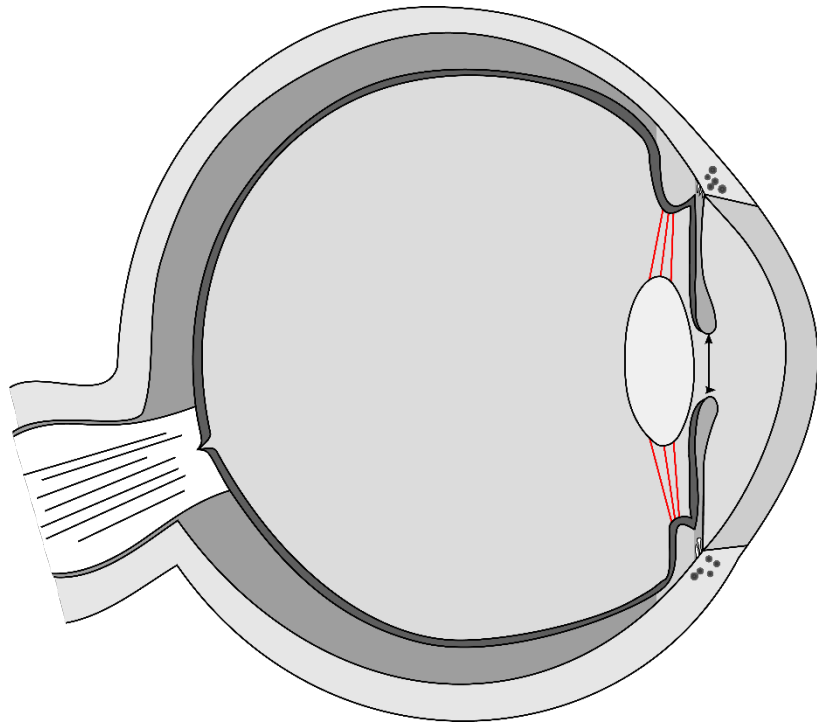
Glaskörper



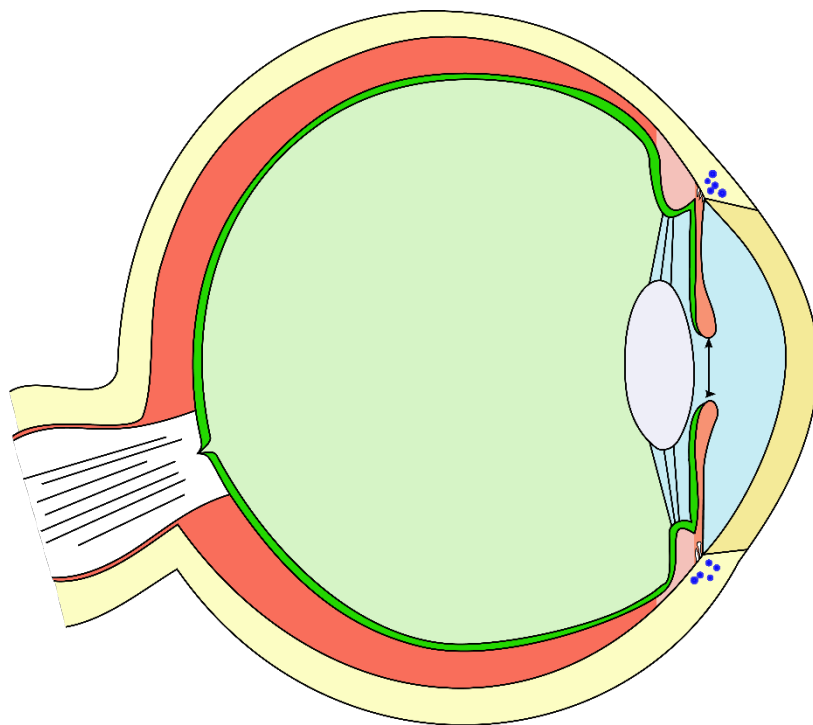
Netzhaut



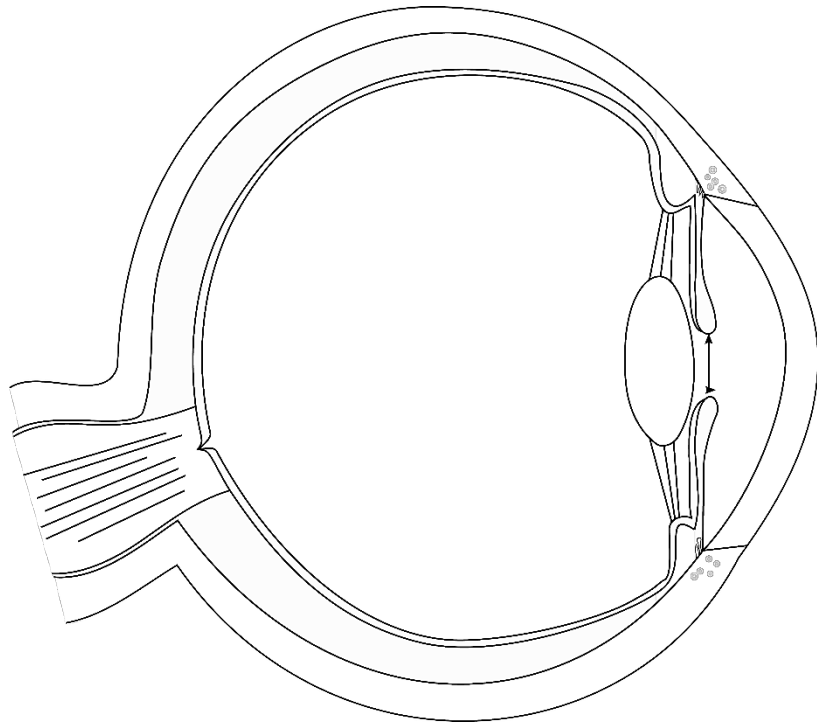
Sehnerv



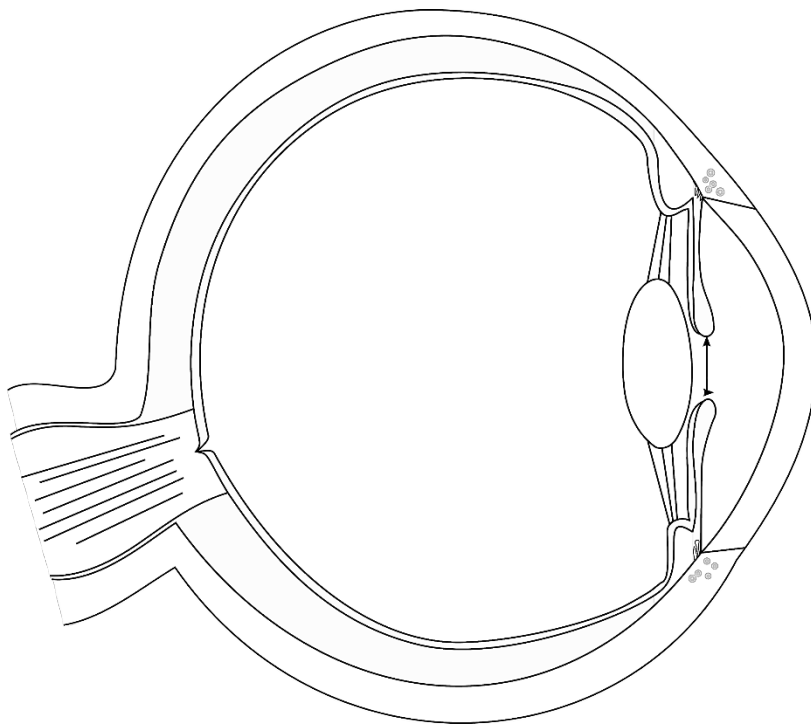
Zonulafasern



menschliches Auge



menschliches Auge



menschliches Auge

Quellen

[Talos](#), colored by [Jakov](#), [Eye scheme multilingual](#), Beschriftung entfernt, [CC BY-SA 3.0](#)

[Talos](#), colored by [Jakov](#), [Eye scheme multilingual](#), Beschriftung entfernt, schwarz/weiß eingefärbt, [CC BY-SA 3.0](#)

[Talos](#), colored by [Jakov](#), [Eye scheme multilingual](#), Bild schwarz/weiß eingefärbt, einzelne anatomische Teile farbig hervorgehoben, [CC BY-SA 3.0](#)