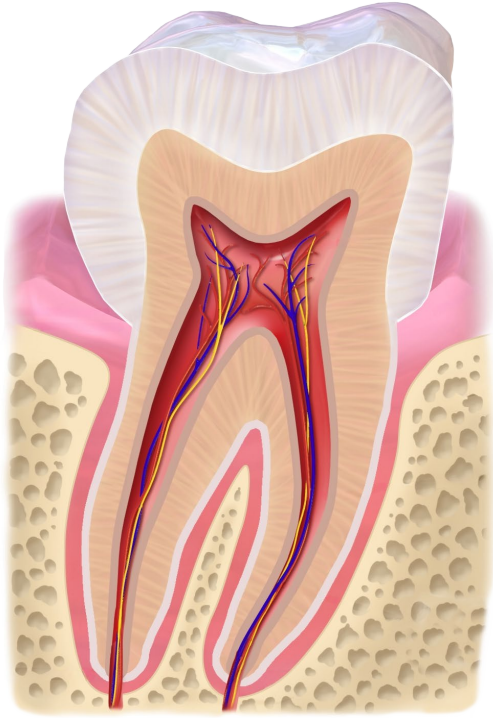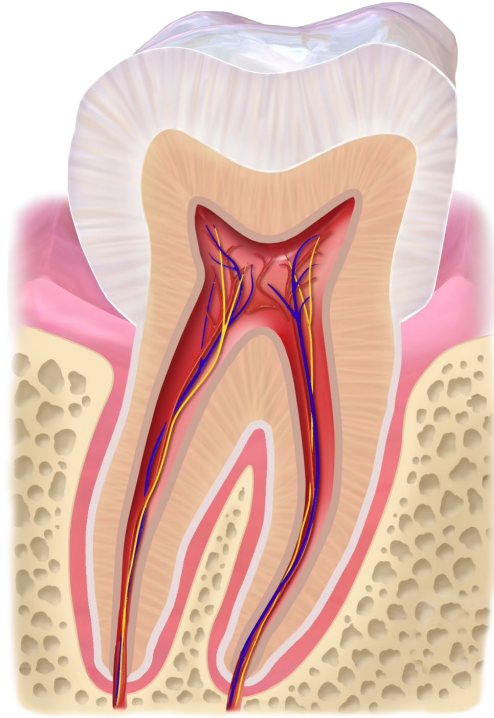
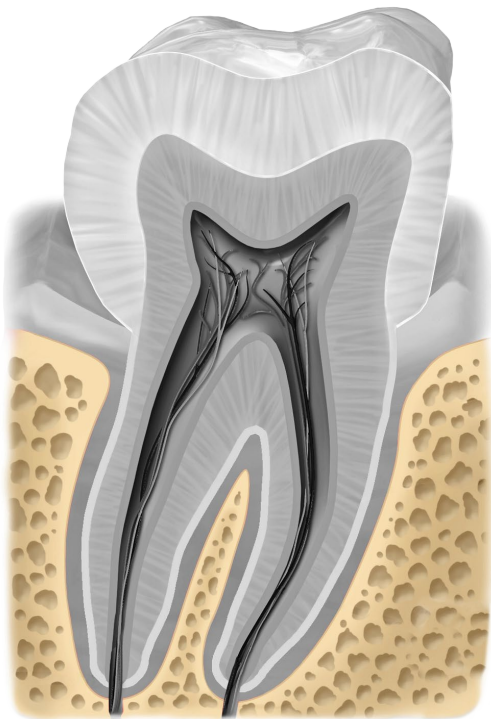


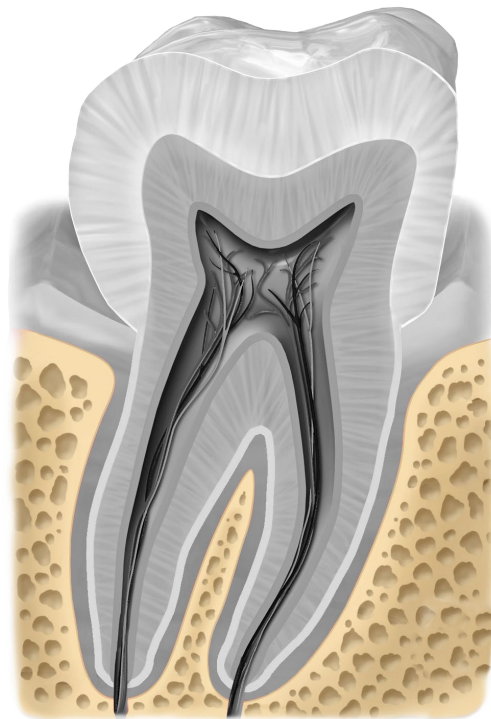
**Backenzahn**



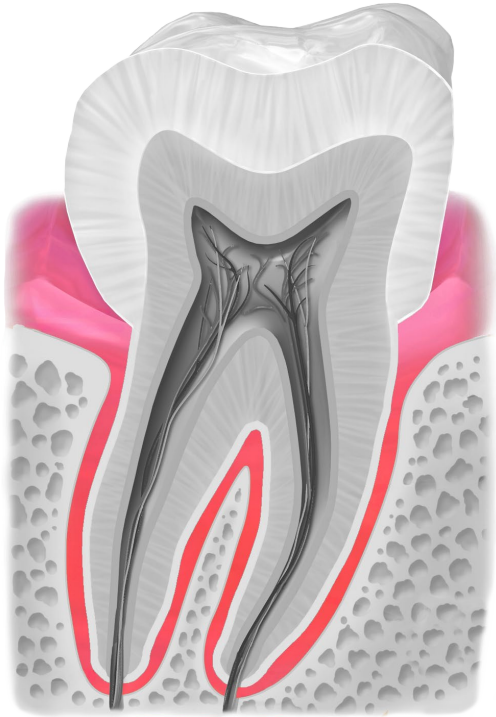
**Backenzahn**



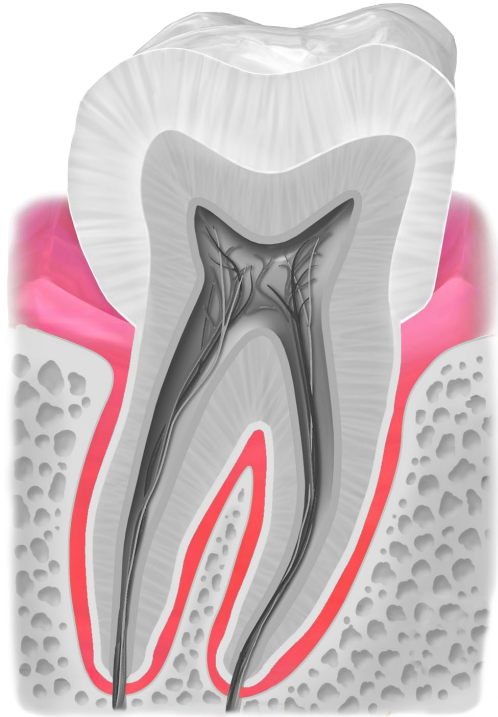
**Kieferknochen**



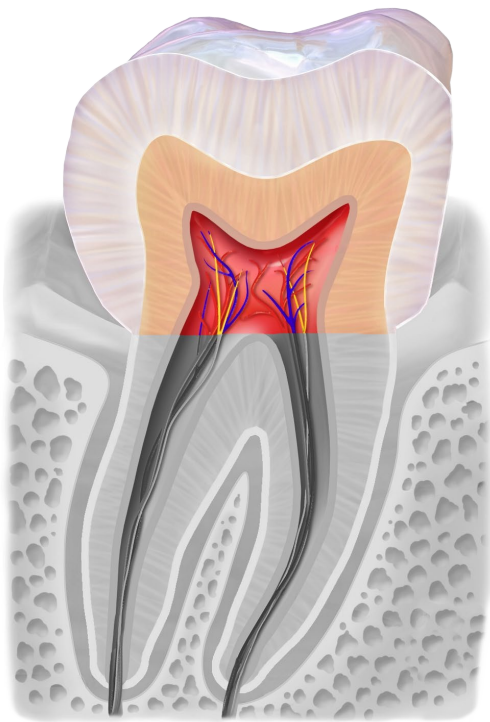
**Kieferknochen**



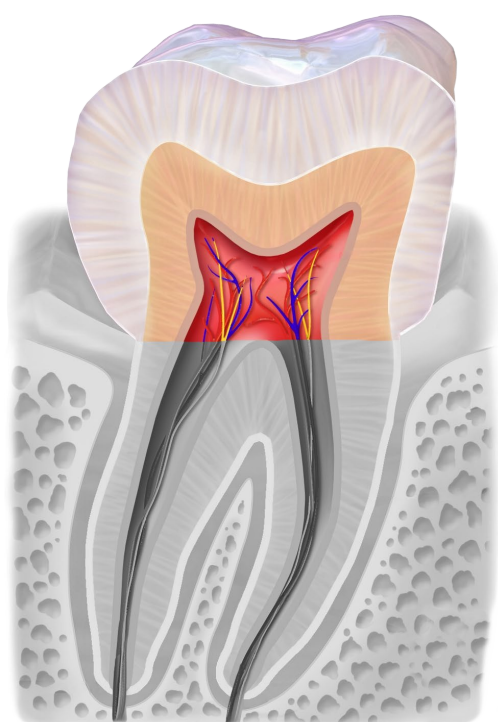
**Zahnfleisch**



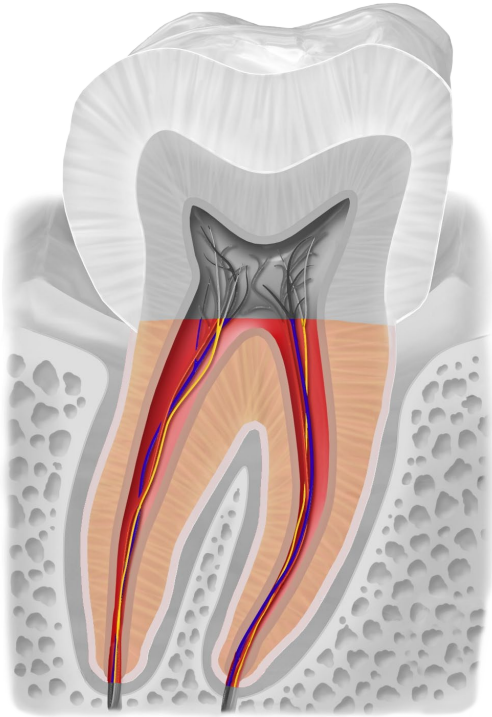
**Zahnfleisch**



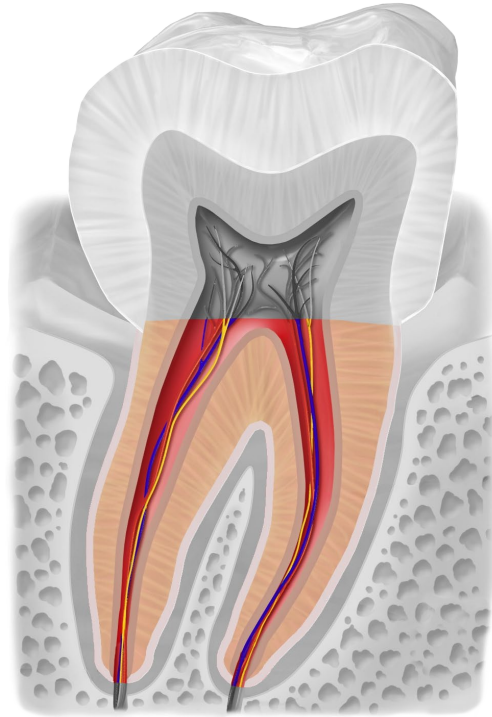
**Zahnkrone**



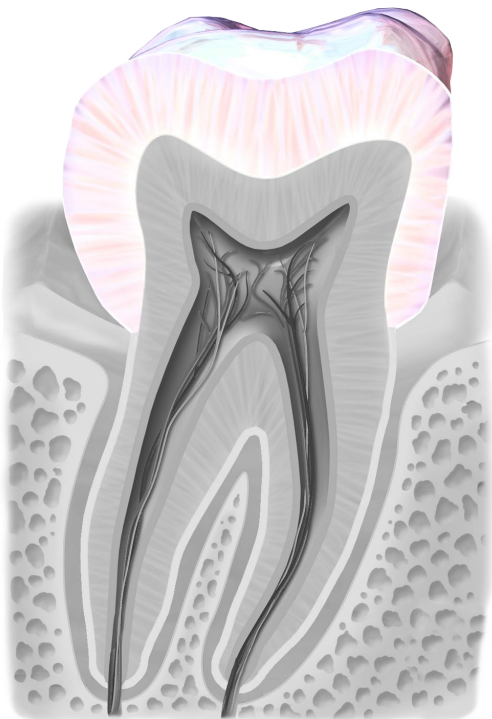
**Zahnkrone**



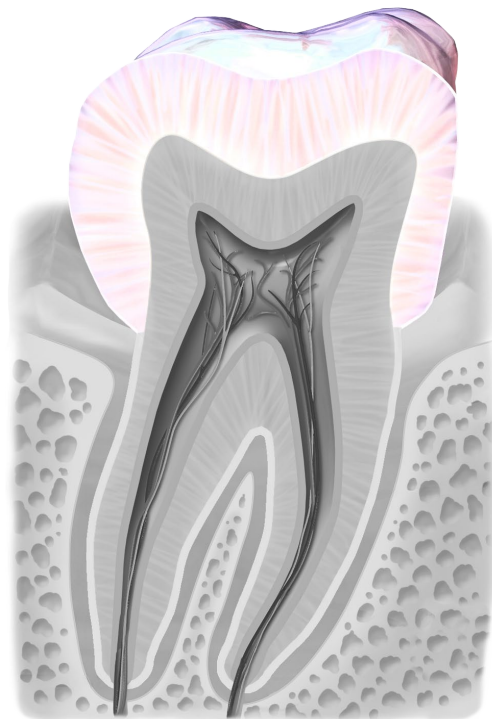
Zahnwurzel



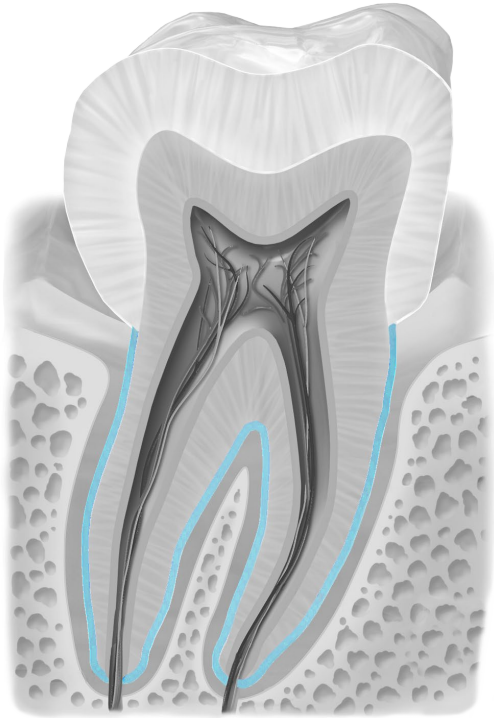
Zahnwurzel



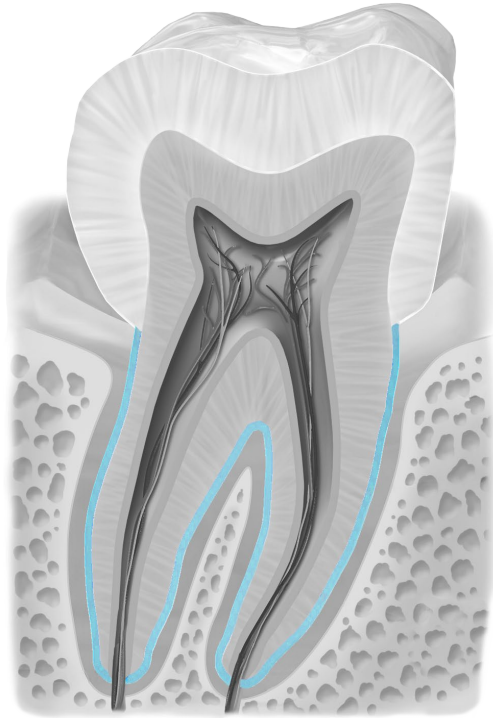
Zahnschmelz



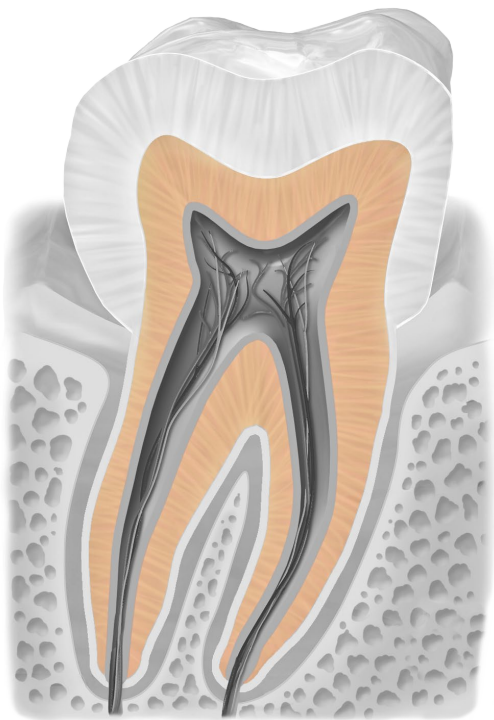
Zahnschmelz



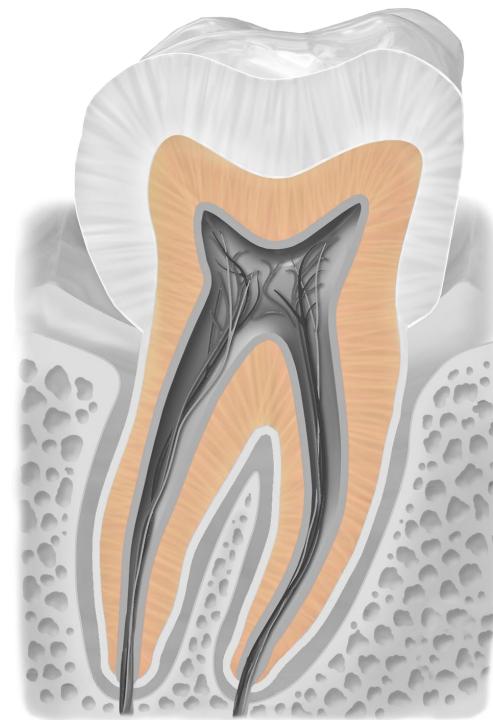
**Zahnzement**



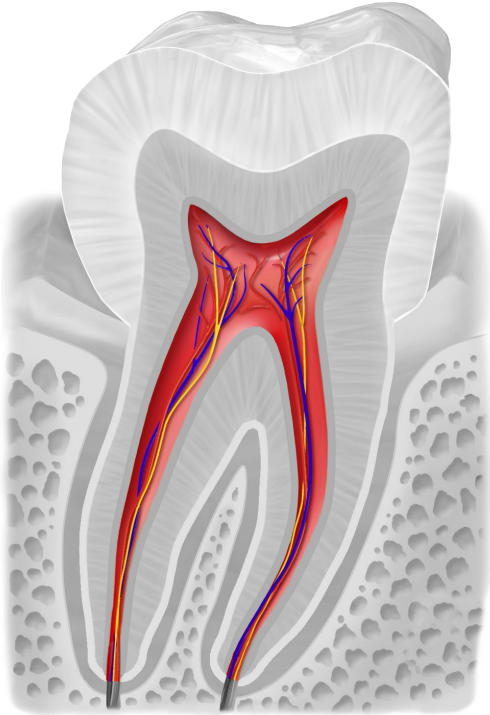
**Zahnzement**



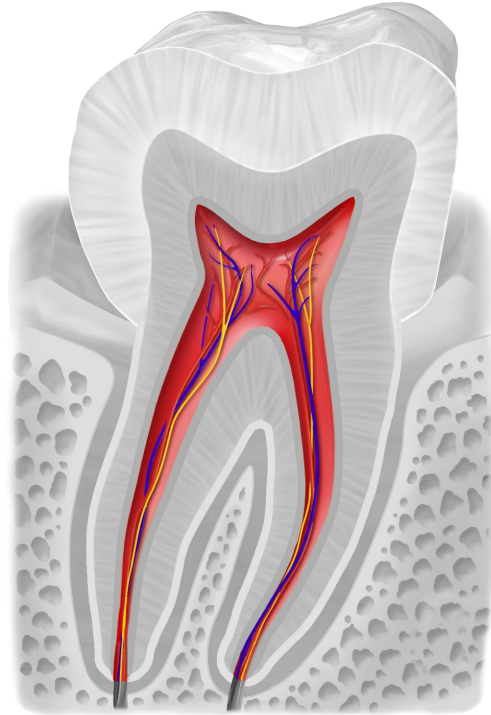
**Zahnbein**



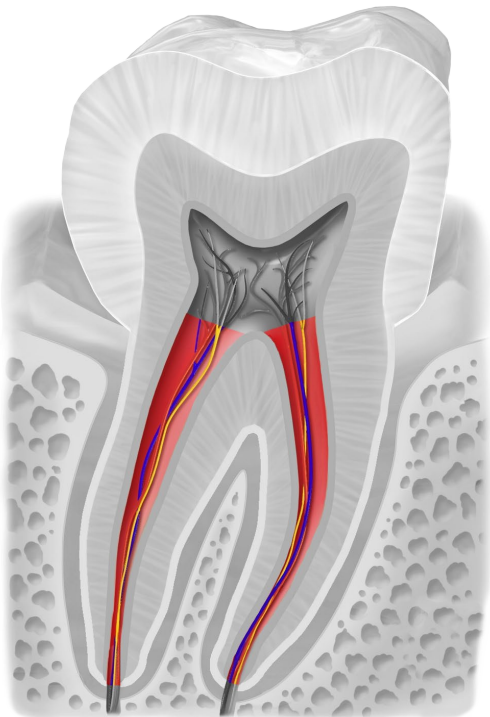
**Zahnbein**



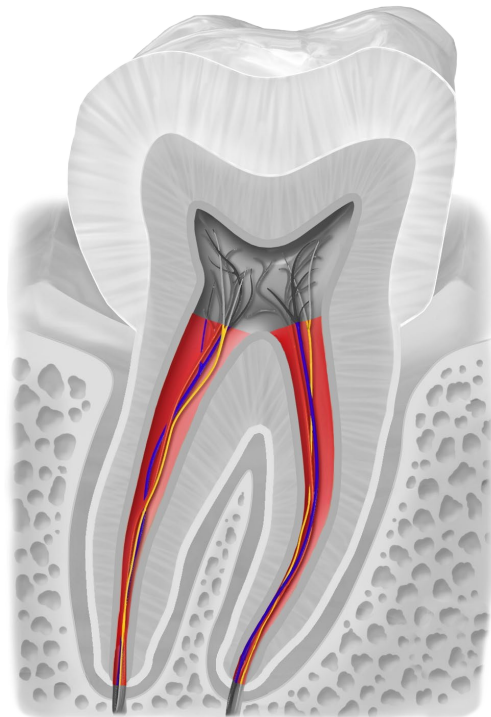
Zahnmark mit Blutgefäßen und Nerven



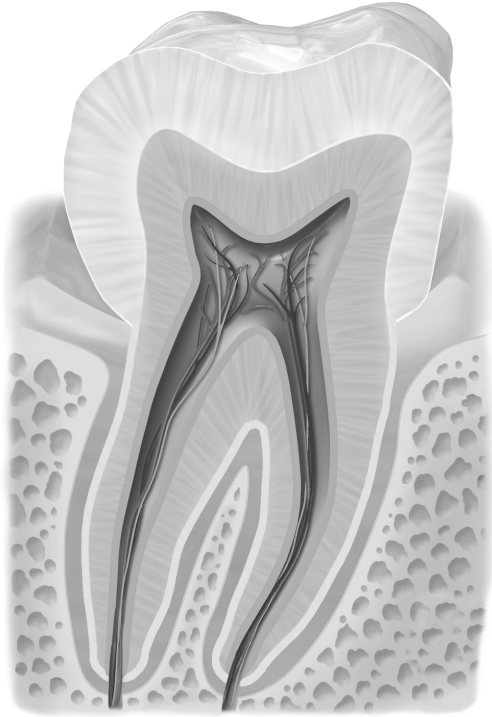
Zahnmark mit Blutgefäßen und Nerven



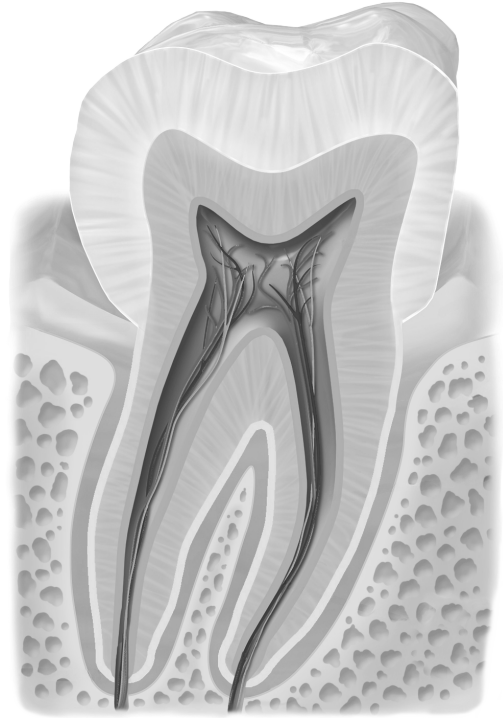
Wurzelkanal



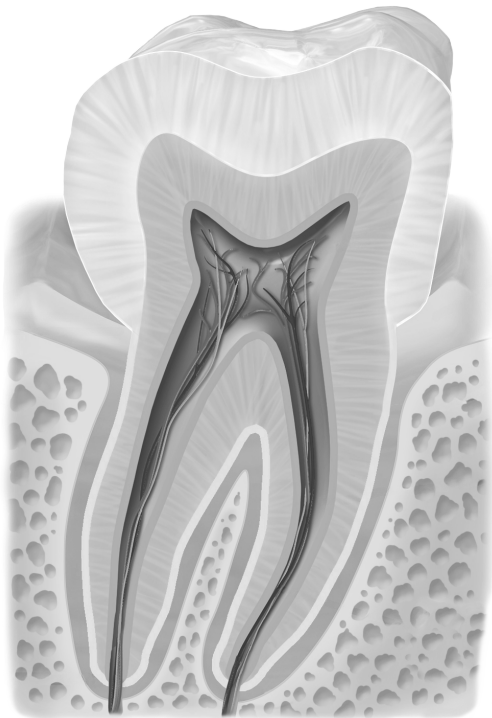
Wurzelkanal



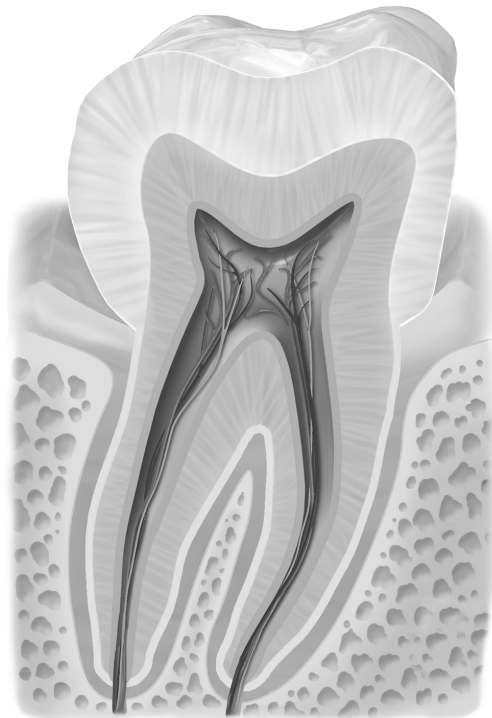
Zahn schwarz/weiß



Zahn schwarz/weiß



Zahn schwarz/weiß



Zahn schwarz/weiß

## Quellen

[BruceBlas](#). When using this image in external sources it can be cited as: Blausen.com staff (2014). "[Medical gallery of Blausen Medical 2014](#)". WikiJournal of Medicine 1 (2). [DOI:10.15347/wjm/2014.010](#). [ISSN 2002-4436](#)., [Blausen 0863 ToothAnatomy 02](#), Beschriftung entfernt, Zahn schwarz/weiß eingefärbt und einzelne anatomische Teile farbig draufgelegt, [CC BY 3.0](#)