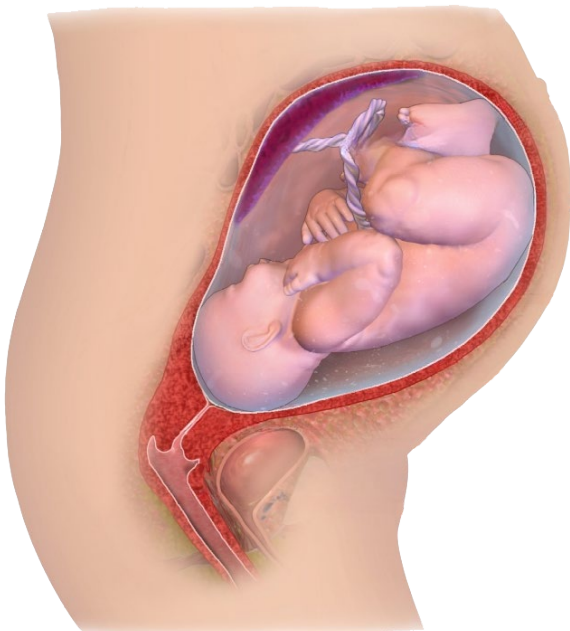




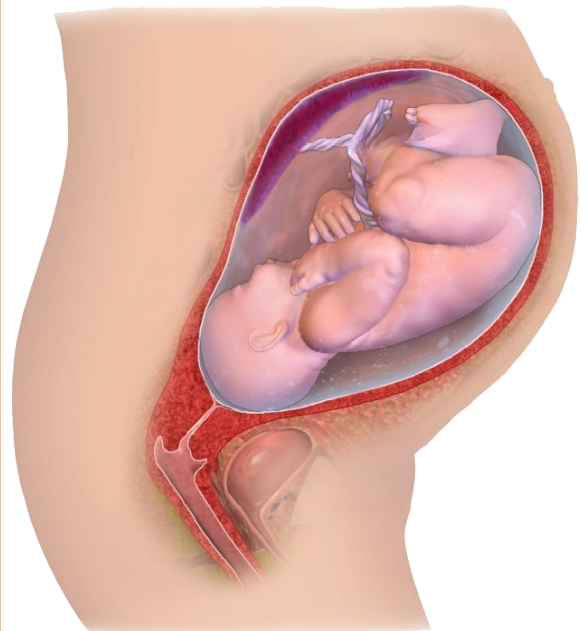
pregnant woman



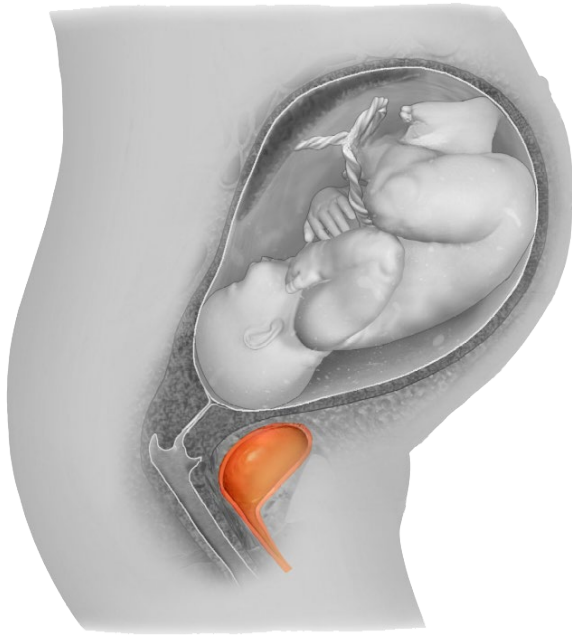
pregnant woman



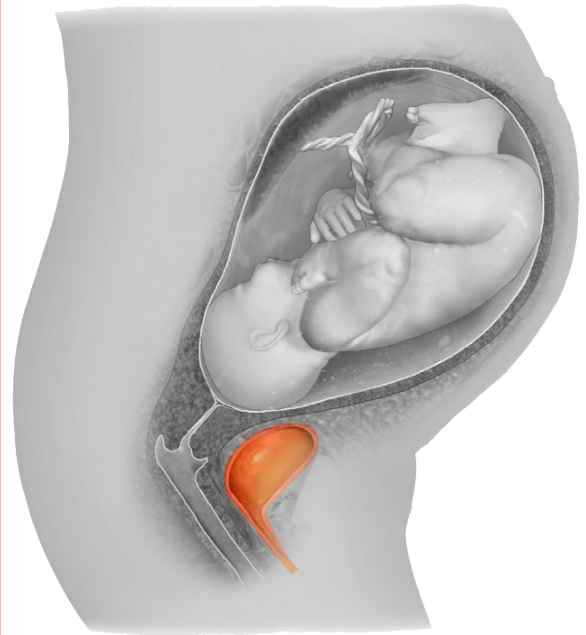
fetus in the uterus



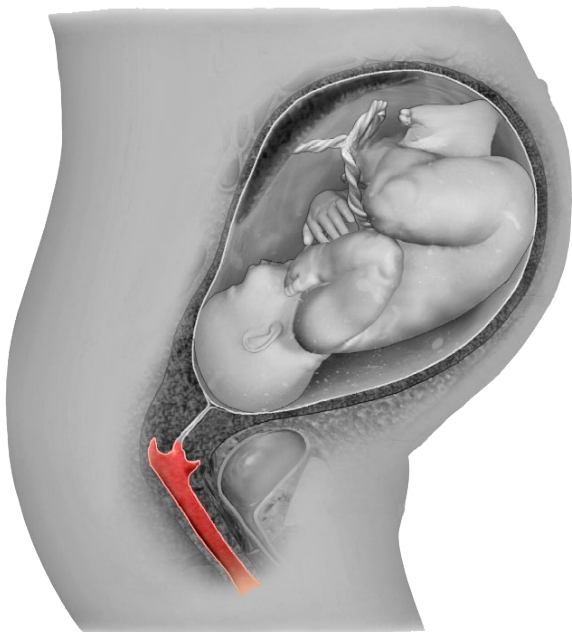
fetus in the uterus



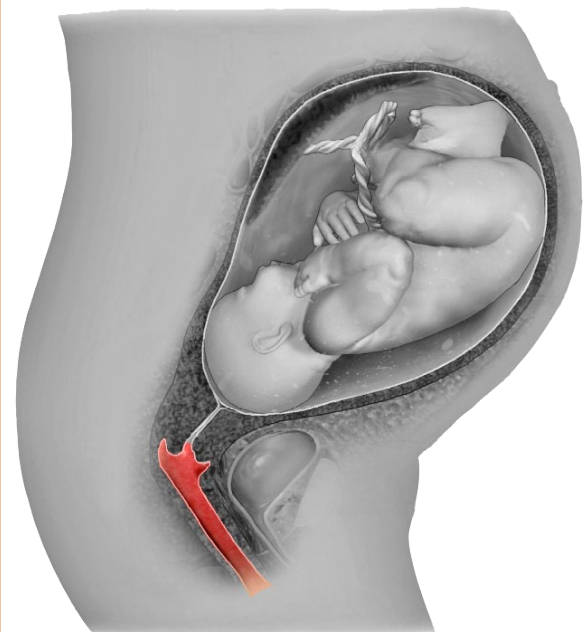
urinary bladder and
urethra



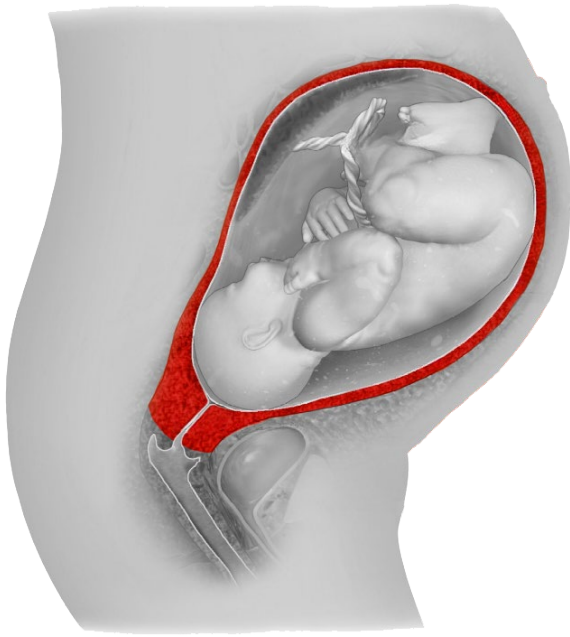
urinary bladder and
urethra



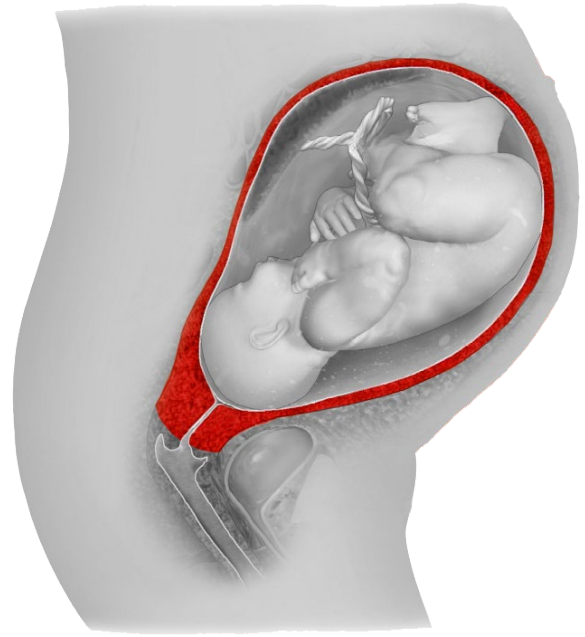
vagina



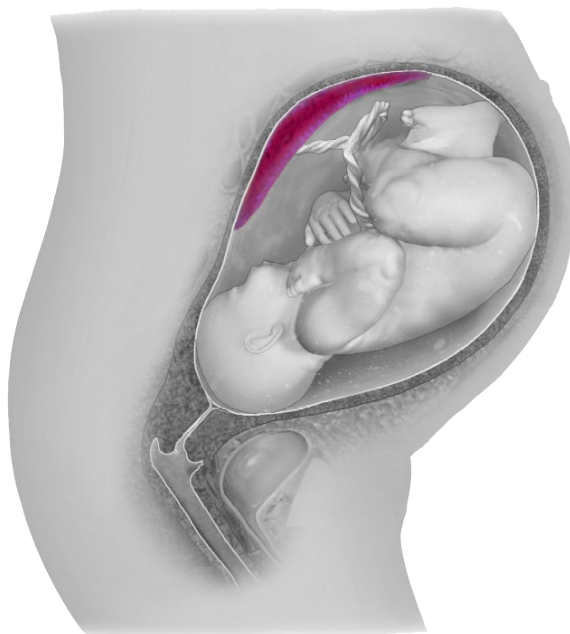
vagina



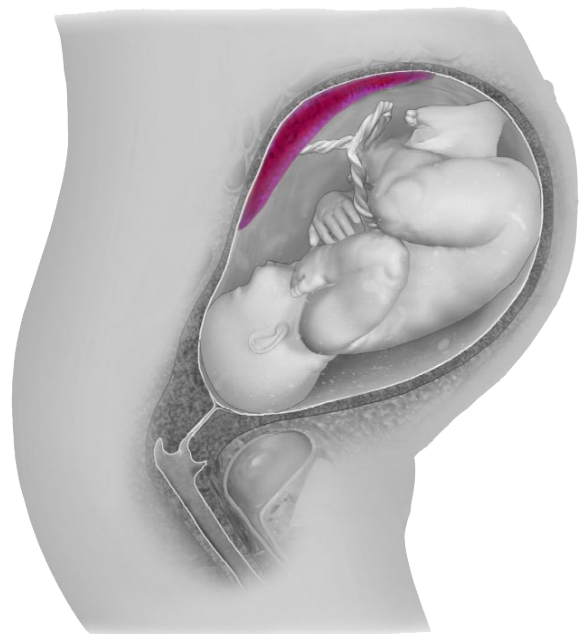
uterus



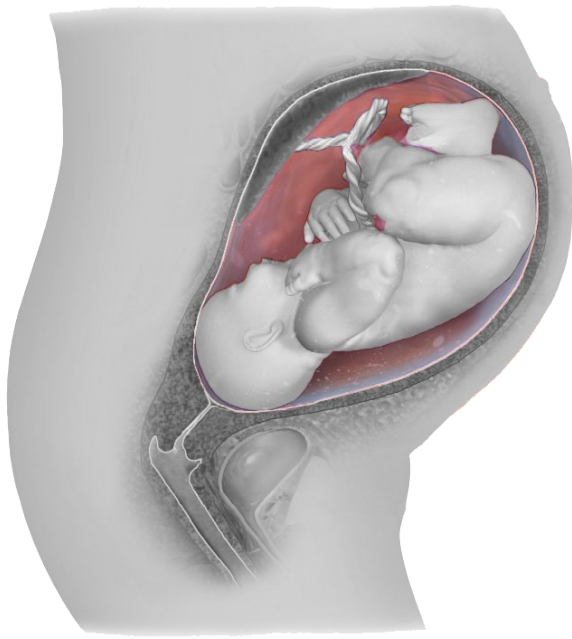
uterus



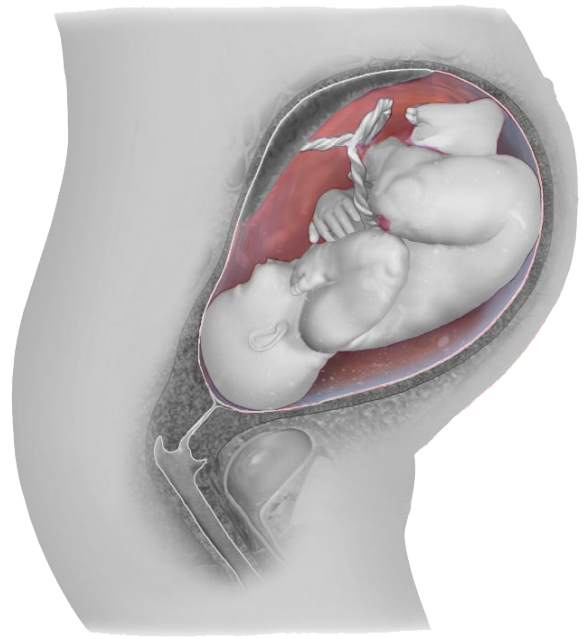
placenta



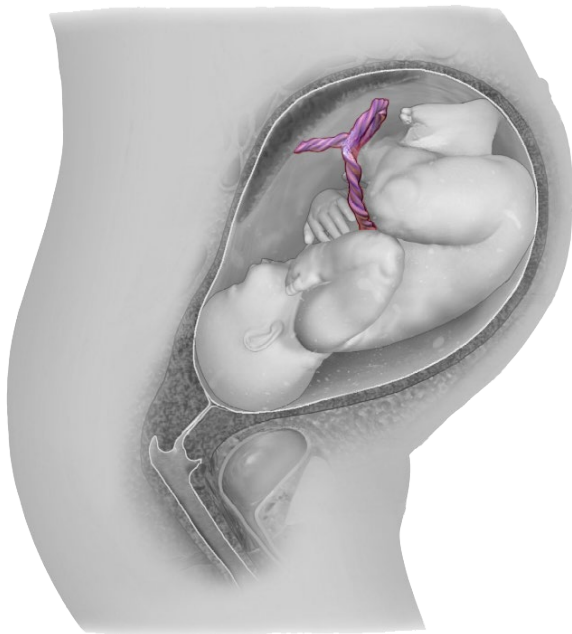
placenta



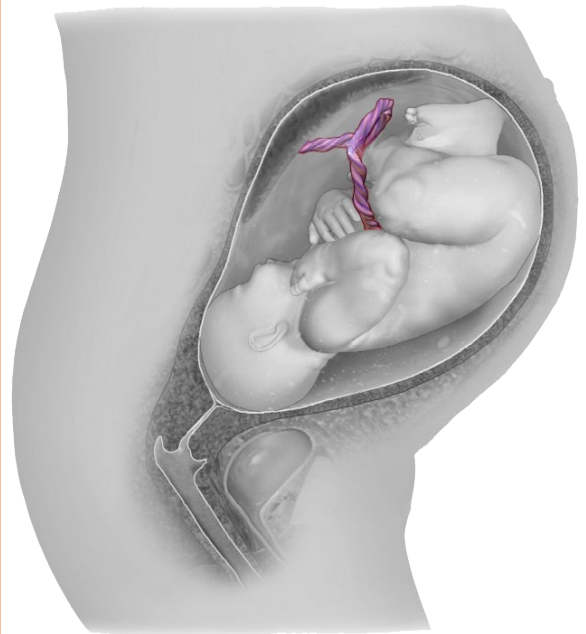
amniotic sac with
amniotic fluid



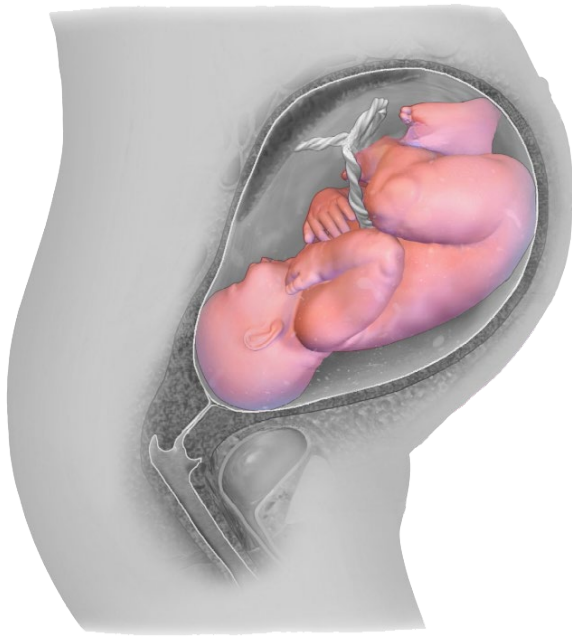amniotic sac with
amniotic fluid



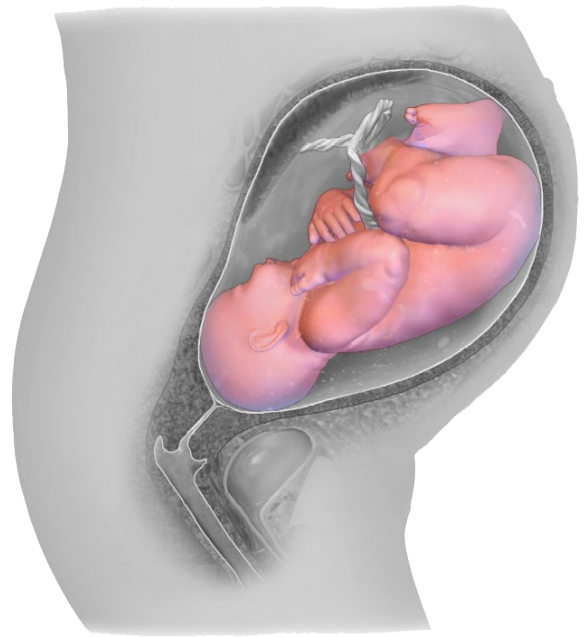umbilical cord



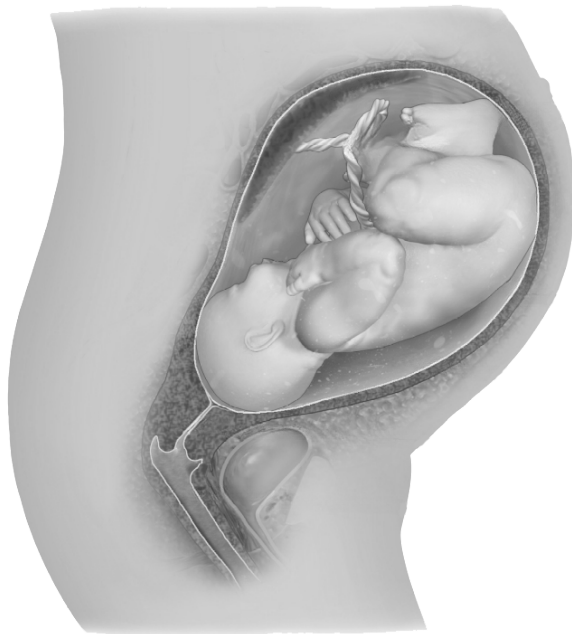umbilical cord



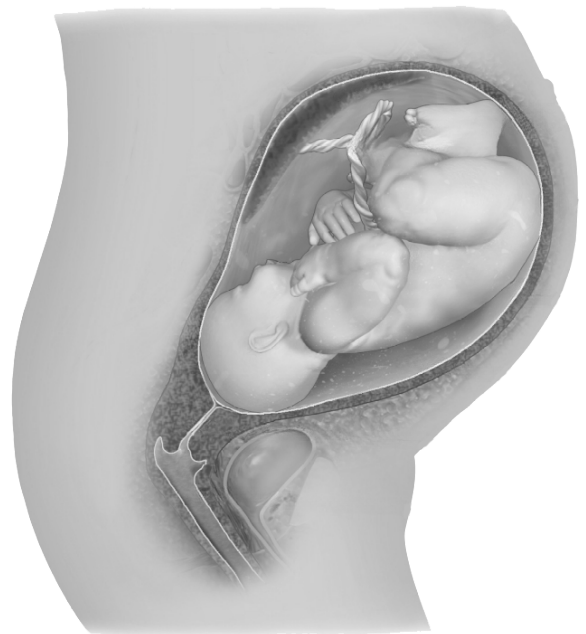fetus



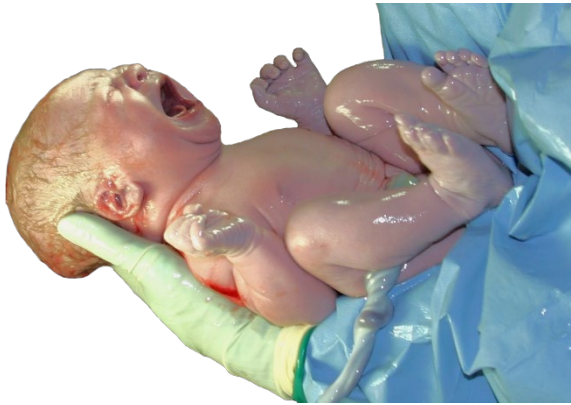fetus



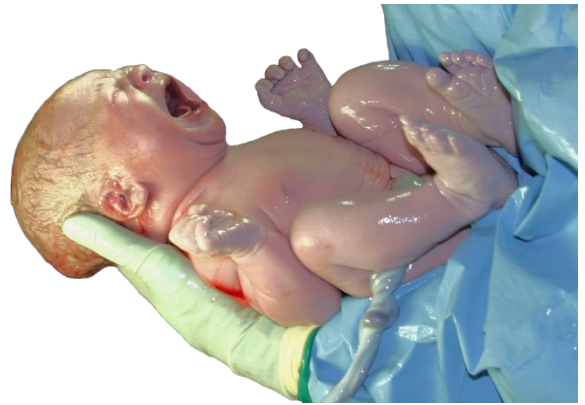fetus in the uterus
(black/white)



fetus in the uterus
(black/white)



newborn



newborn



slightly older baby



slightly older baby

Quellen

[A Pregnant Woman in Long Dress Standing on Green Grass Field · Free Stock Photo \(pexels.com\)](#)

[BruceBlas](#). When using this image in external sources it can be cited as: Blausen.com staff (2014).

"[Medical gallery of Blausen Medical 2014](#)". WikiJournal of Medicine 1

(2). DOI:[10.15347/wjm/2014.010](#). ISSN [2002-4436](#)., [Blausen 0747 Pregnancy](#), Bild gedreht, Beschriftung entfernt, schwarz/weiß eingefärbt, einzelne anatomische Teile farbig draufgelegt, [CC BY 3.0](#)

Ernest F, [HumanNewborn](#), Hintergrund teilweise entfernt, [CC BY-SA 3.0](#)

[Foto zum Thema baby in blauen unterteilen, die auf weißer oberfläche liegen – Kostenloses Bild zu Grau auf Unsplash](#)