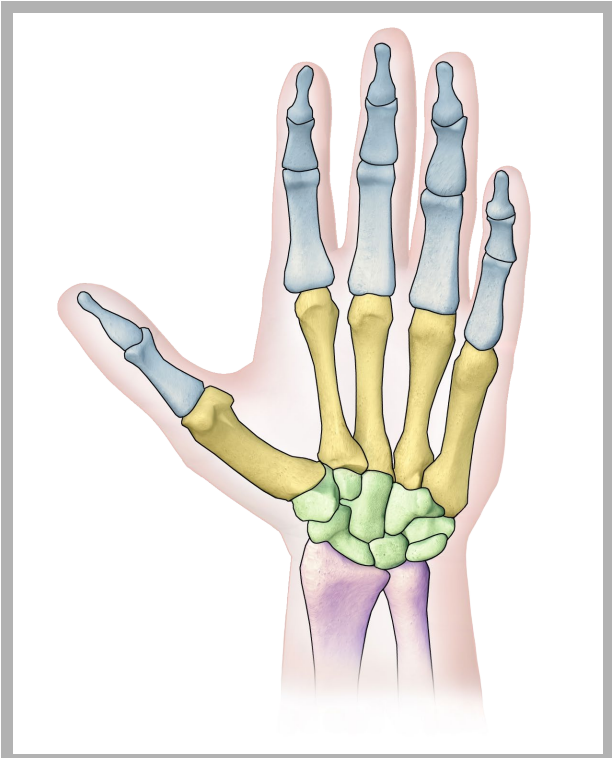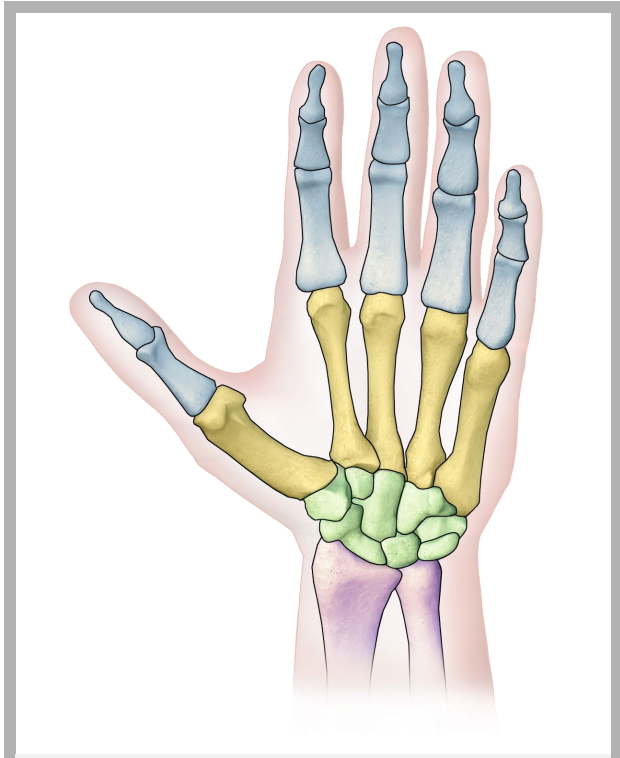
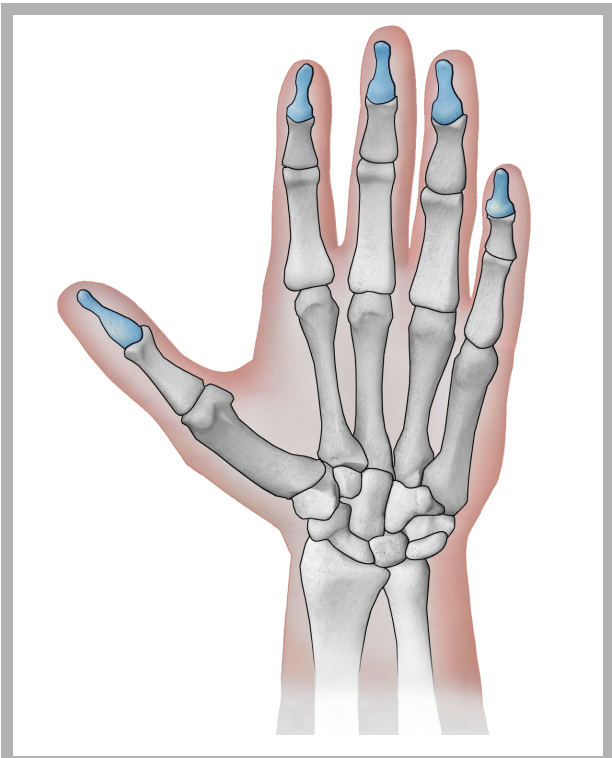


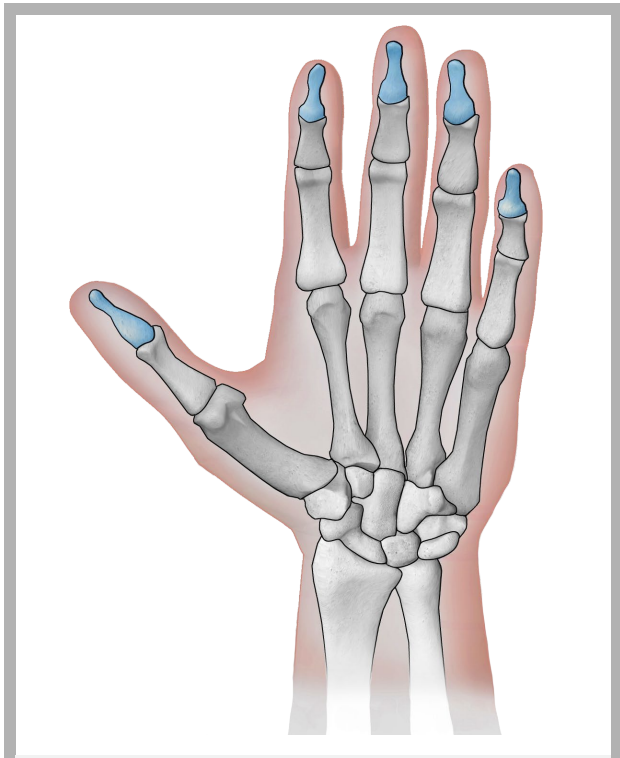
Handknochen



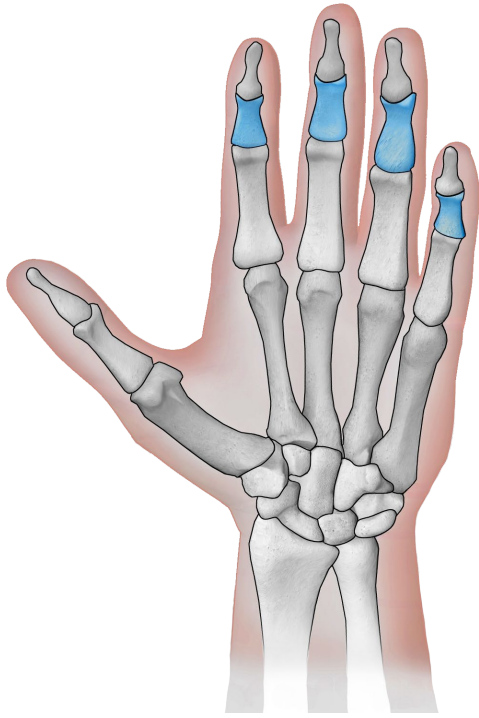
Handknochen



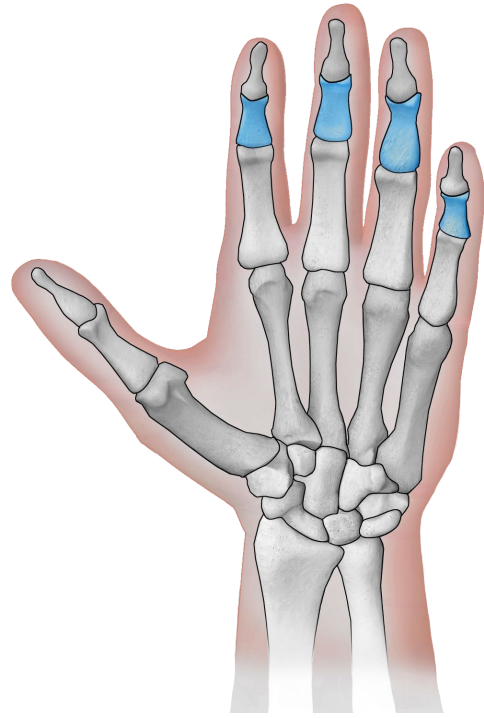
Finger Endglieder



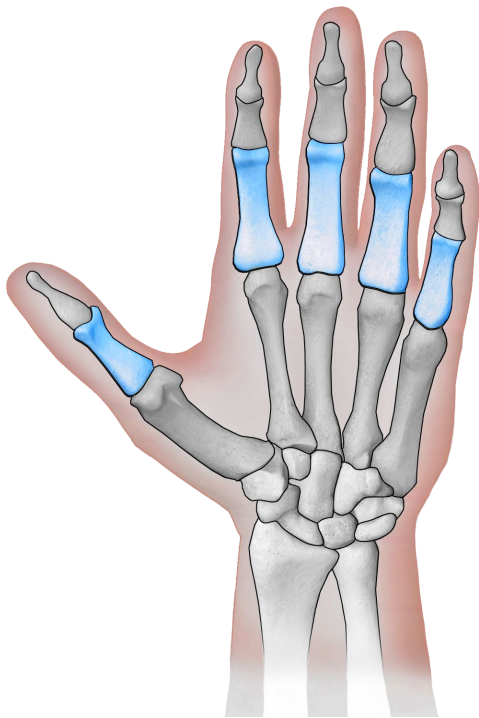
Finger Endglieder



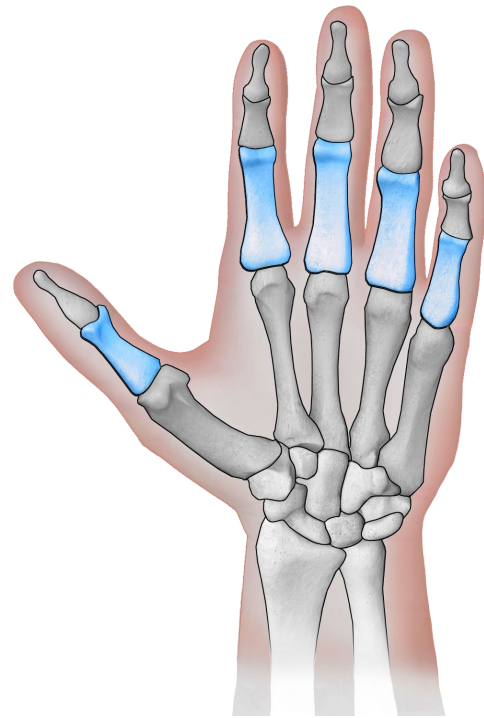
Finger Mittelglieder



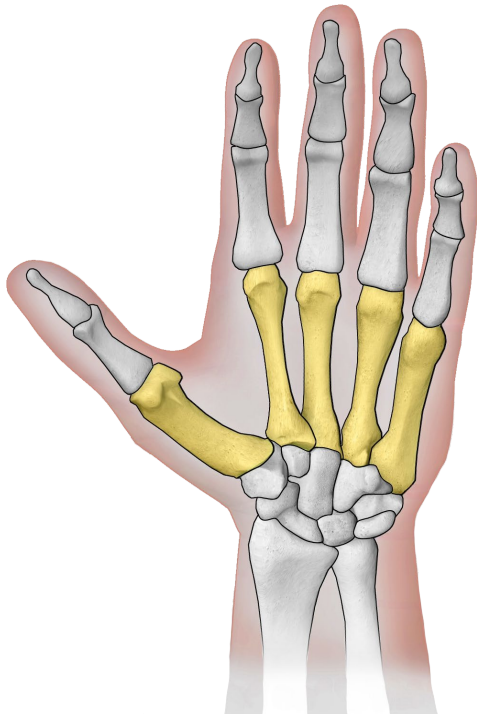
Finger Mittelglieder



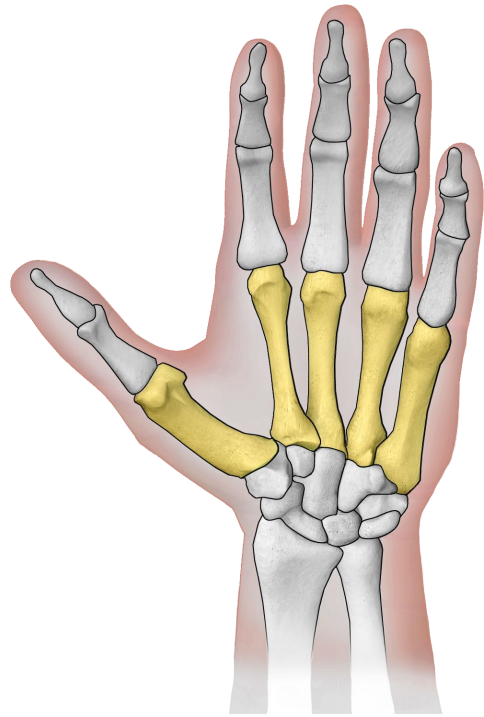
Finger Grundglieder



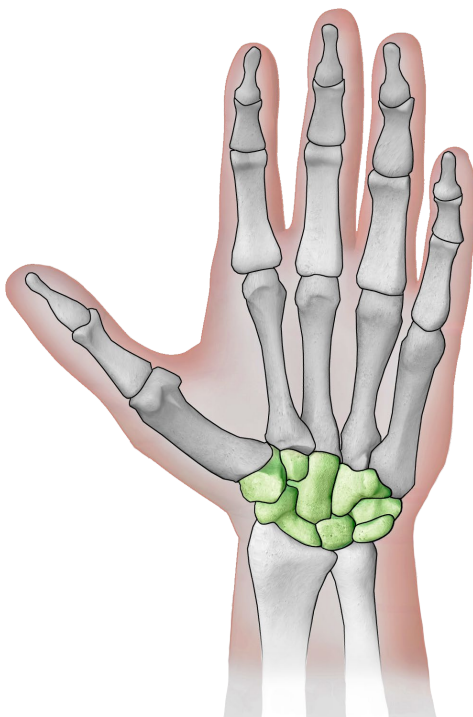
Finger Grundglieder



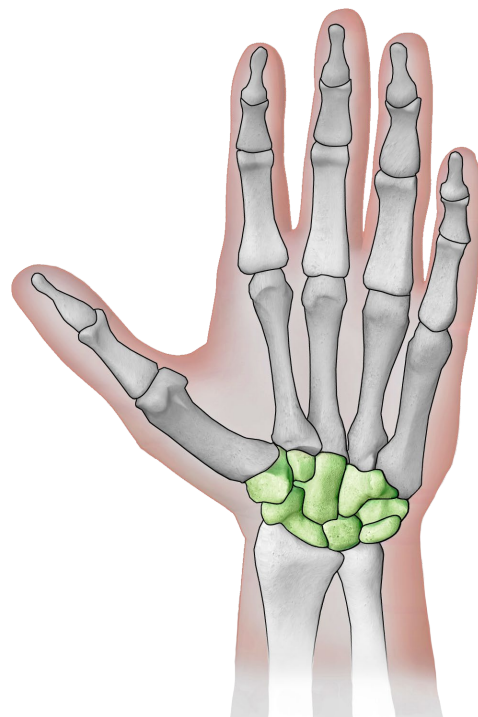
Mittelhandknochen



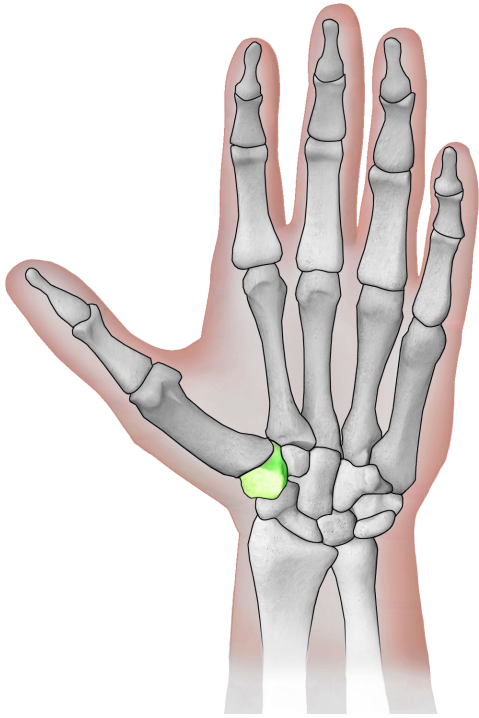
Mittelhandknochen



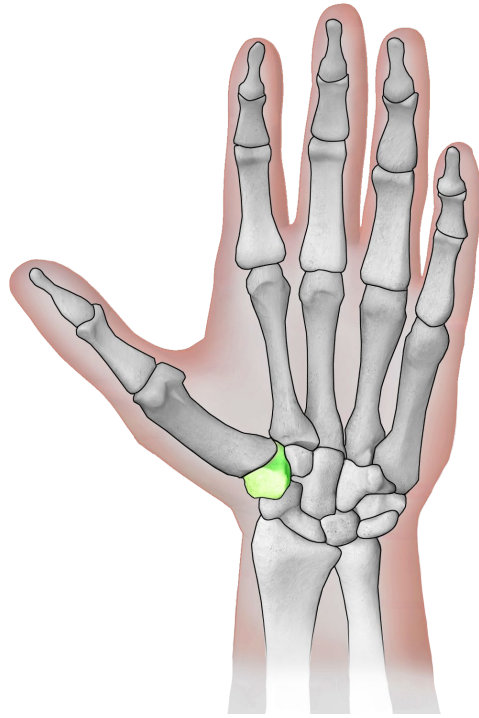
Handwurzelknochen



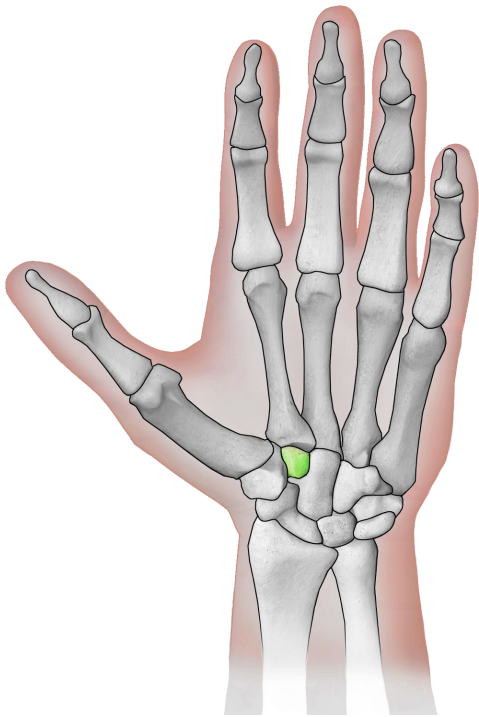
Handwurzelknochen



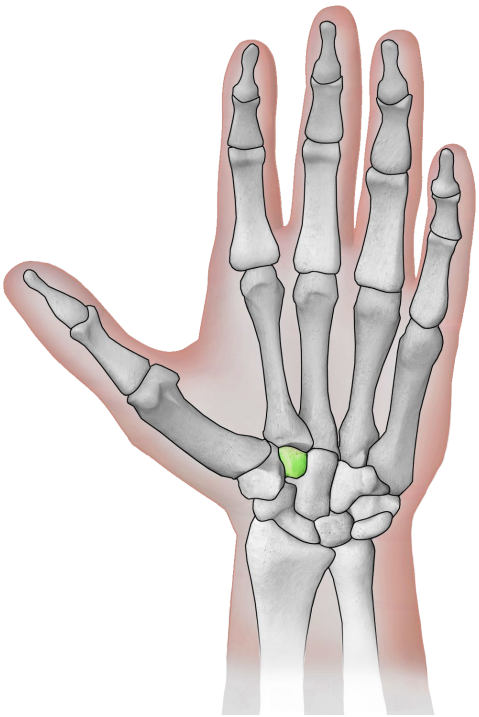
großes Vieleckbein



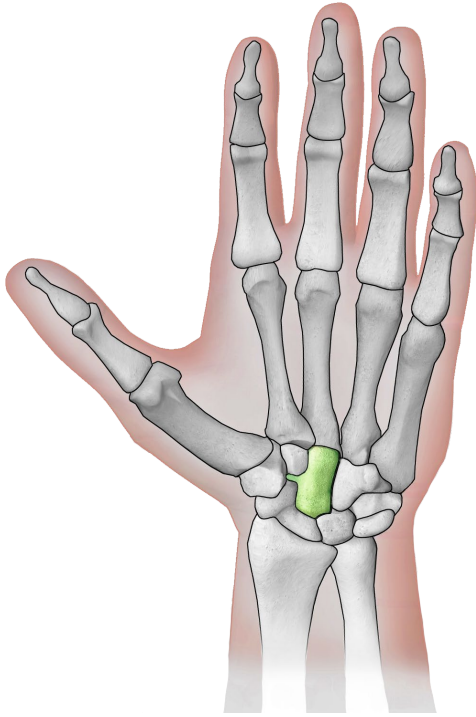
großes Vieleckbein



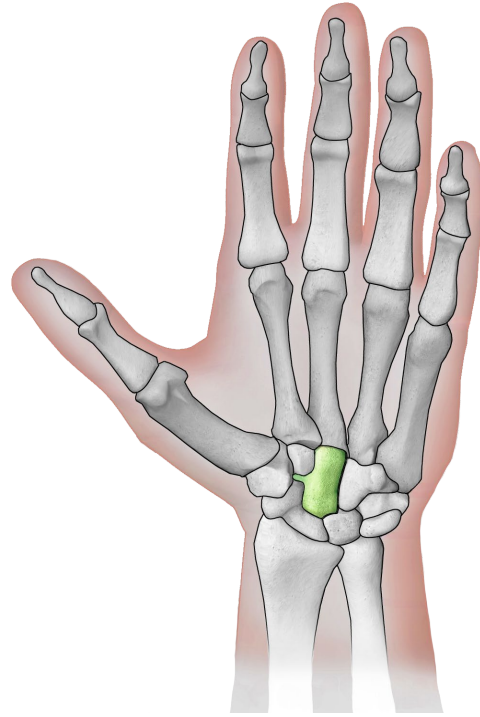
kleines Vieleckbein



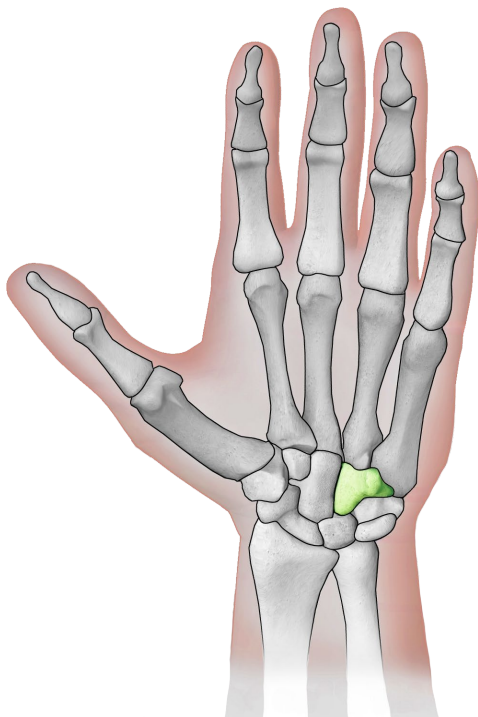
kleines Vieleckbein



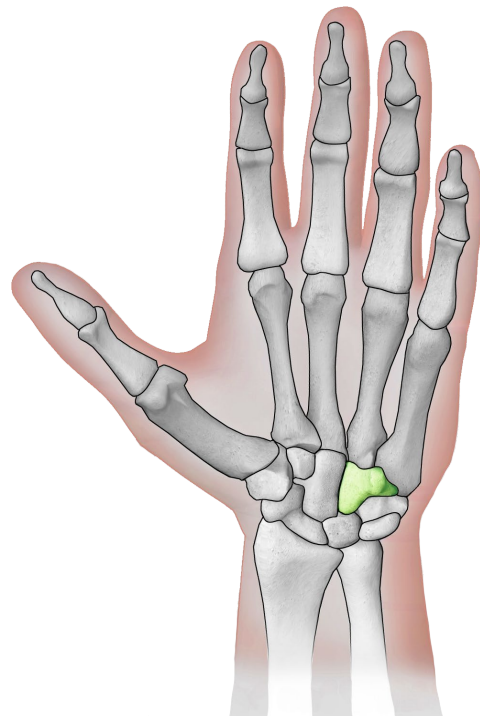
Kopfbein



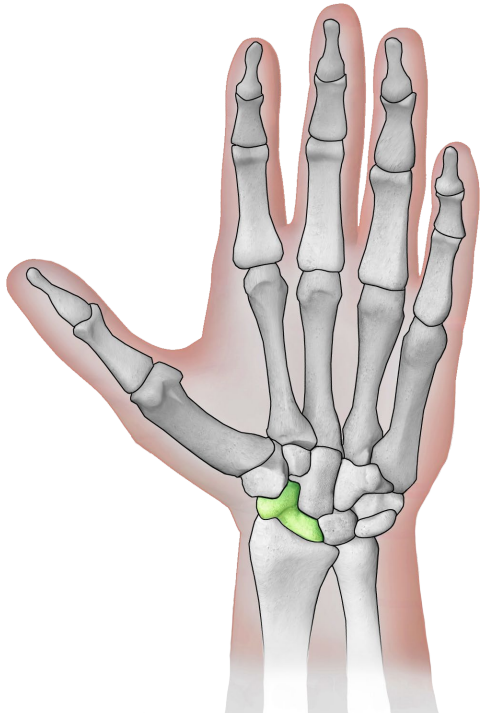
Kopfbein



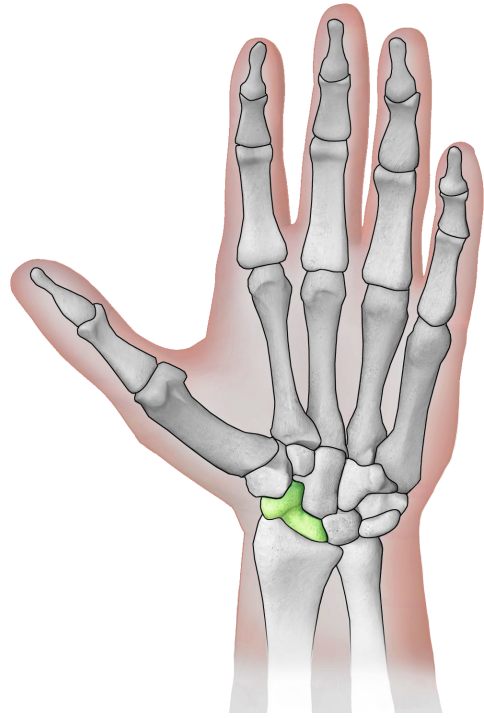
Hakenbein



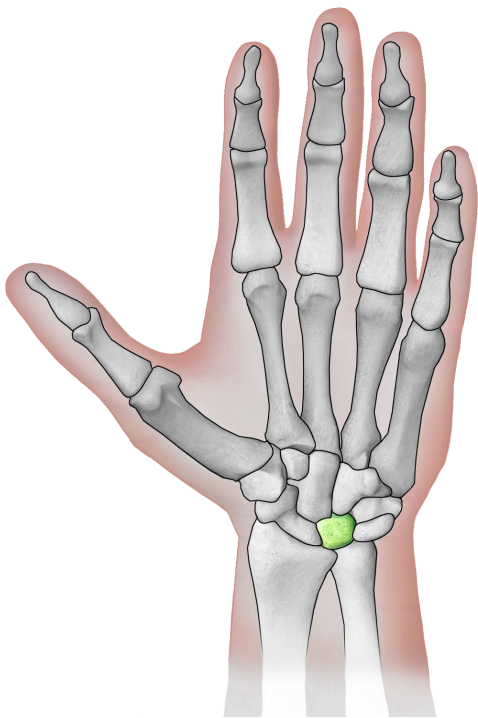
Hakenbein



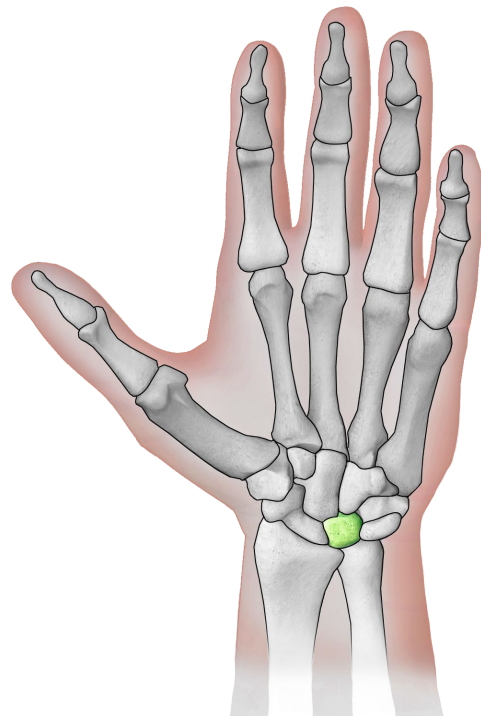
Kahnbein



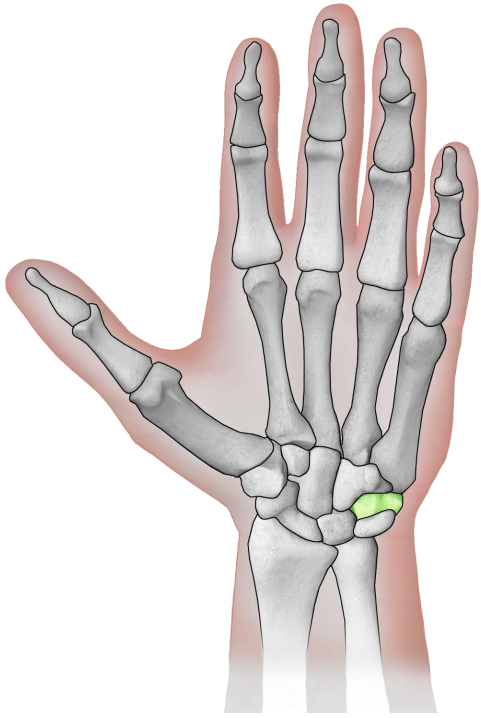
Kahnbein



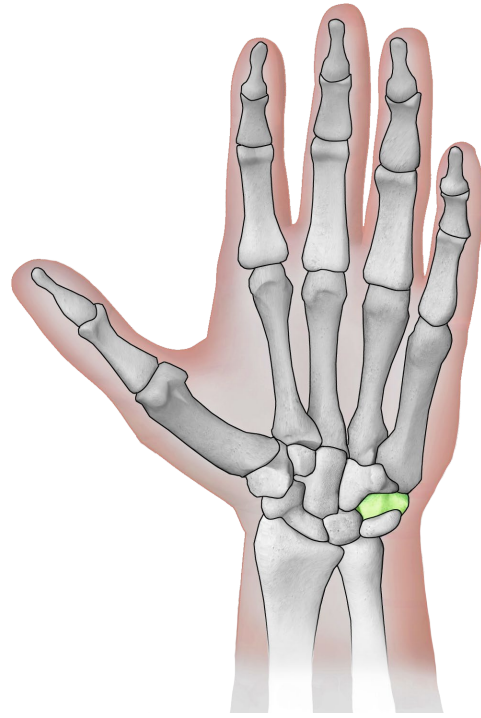
Mondbein



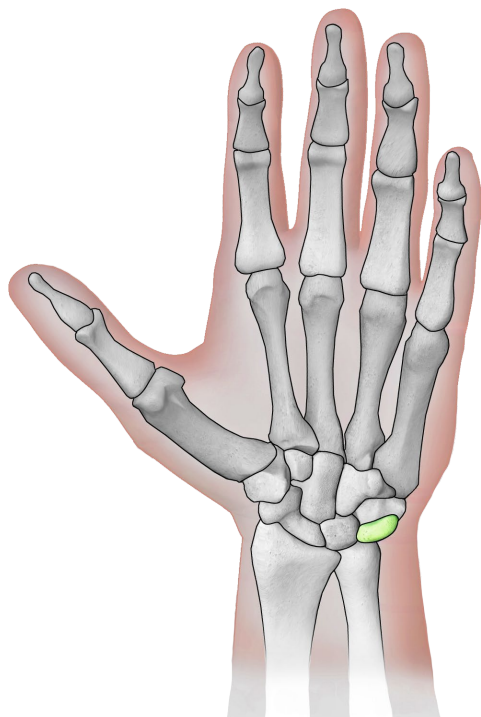
Mondbein



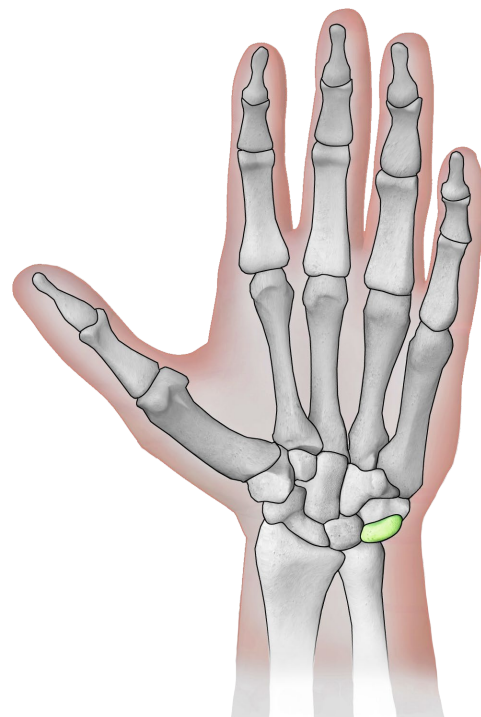
Erbsenbein



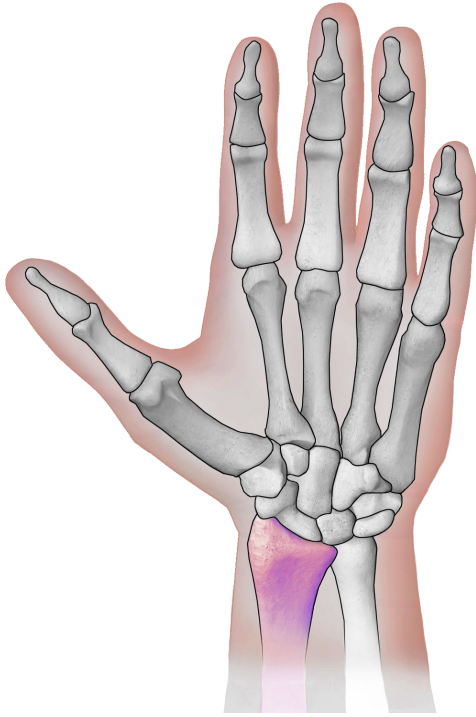
Erbsenbein



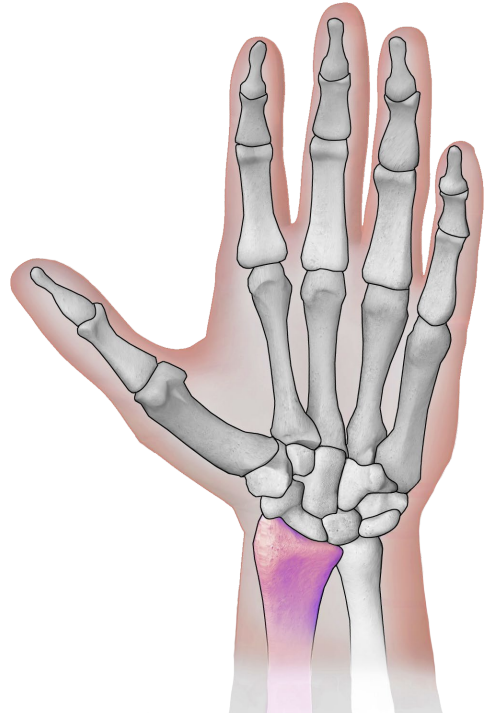
Dreiecksbein



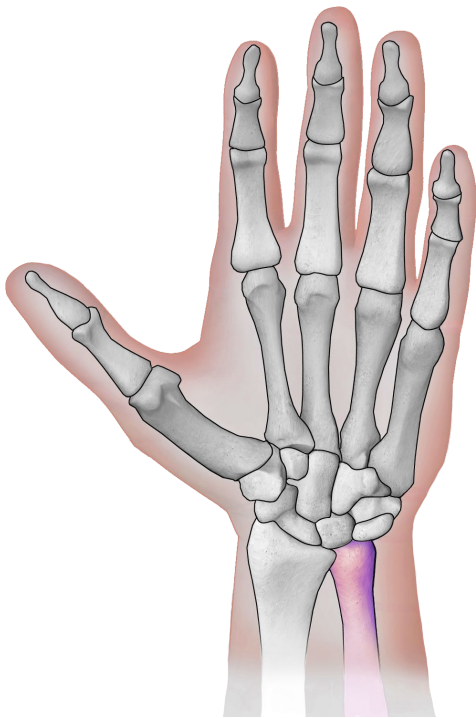
Dreiecksbein



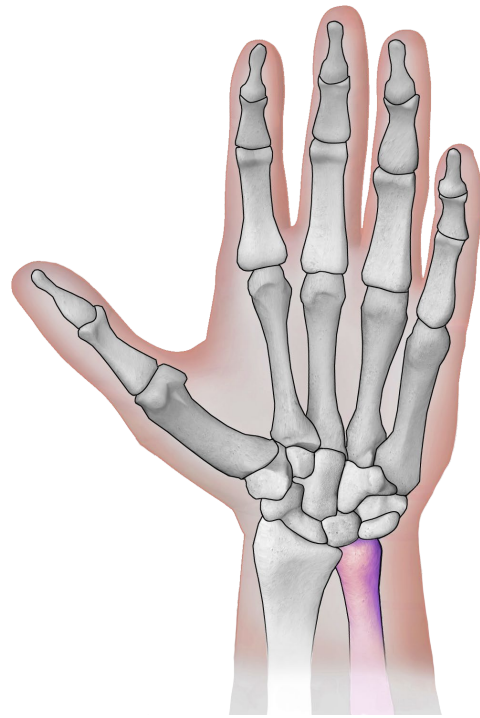
Speiche



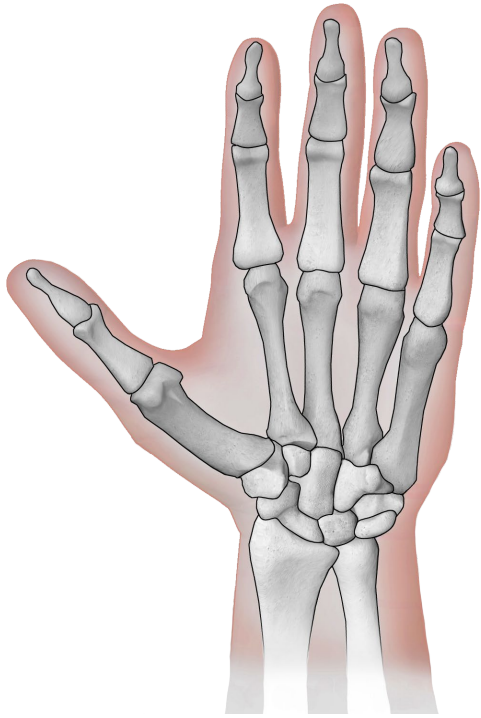
Speiche



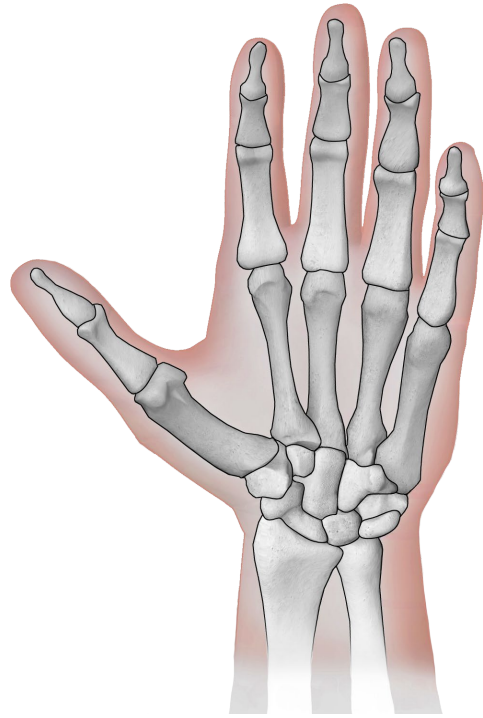
Elle



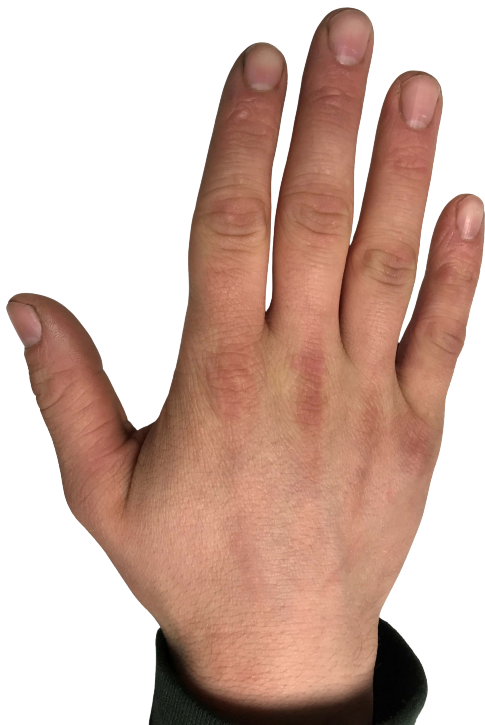Elle



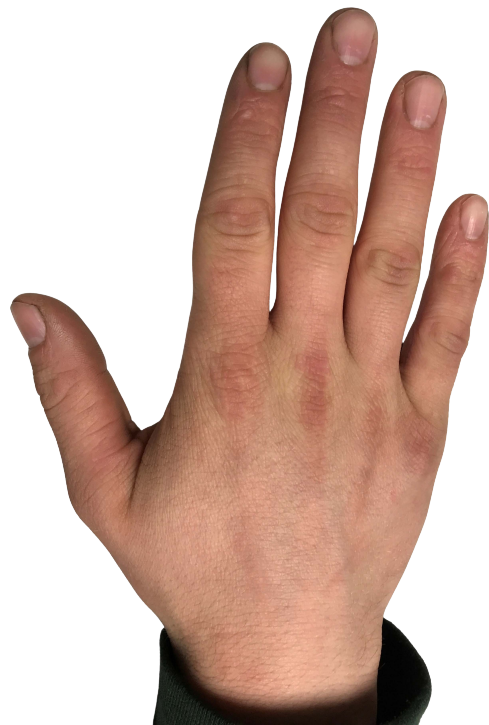Hand mit Knochen
(schwarz/weiß)



Hand mit Knochen
(schwarz/weiß)



Hand eines Teenagers



Hand eines Teenagers

Quellen

[BruceBlaus](#). When using this image in external sources it can be cited as:
Blausen.com staff (2014). "[Medical gallery of Blausen Medical 2014](#)". WikiJournal of
Medicine 1 (2). DOI:[10.15347/wjm/2014.010](#). ISSN [2002-4436](#)., [Blausen 0440](#)
[HandBones](#), Hand schwarz/weiß eingefärbt, einzelne anatomische Teile farbig drauf
gelegt., [CC BY 3.0](#)

[Eyefive45](#), [Hand of a Teenage Boy](#), Bild gedreht und Hintergrund entfernt, [CC BY-SA 4.0](#)