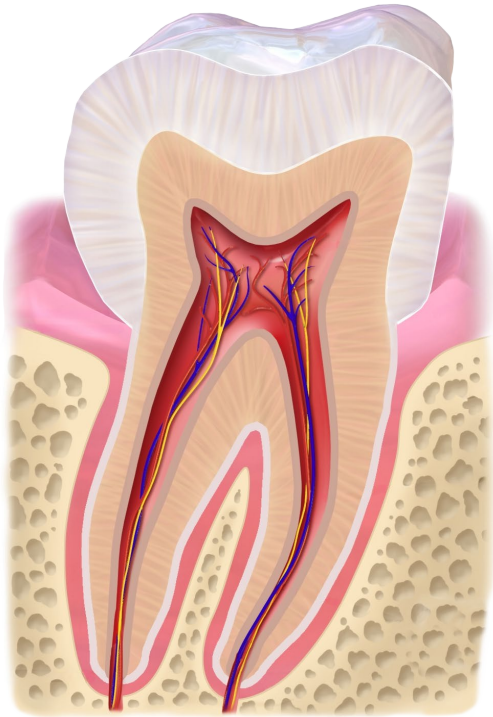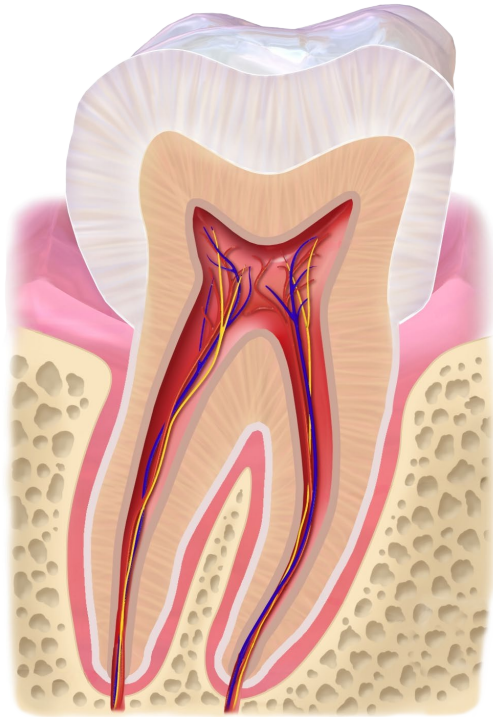
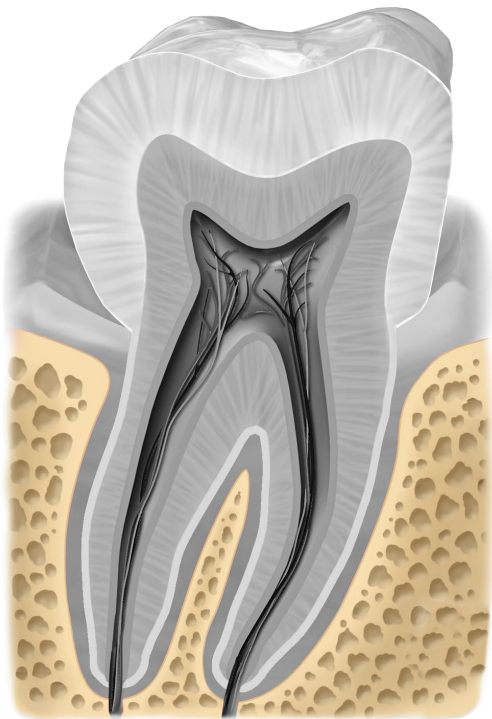


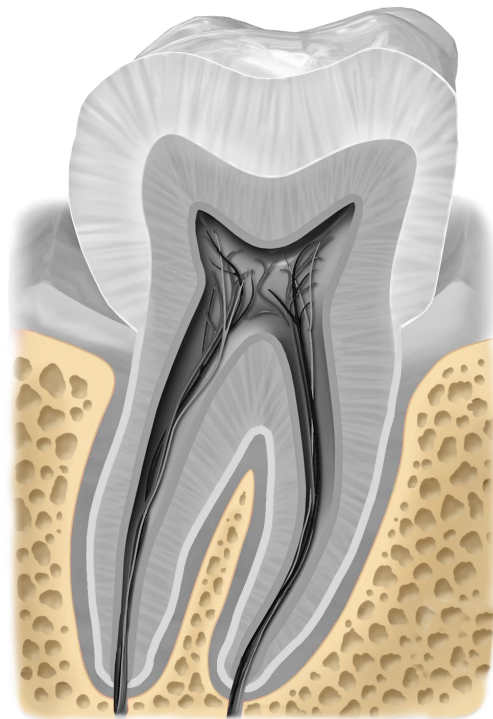
molare



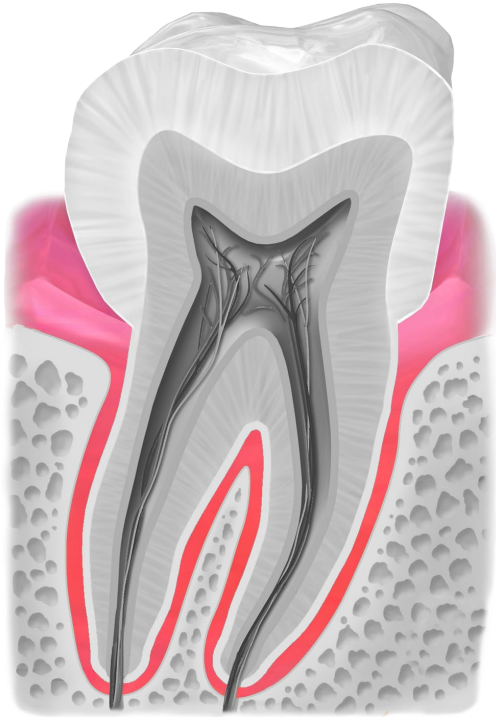
molare



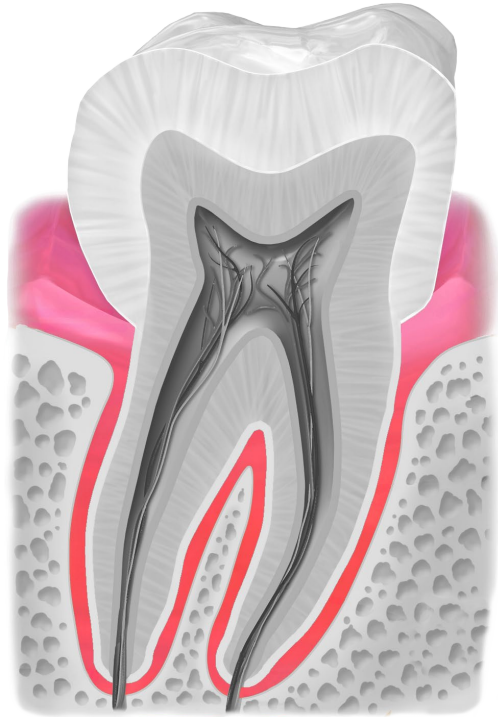
OSSO



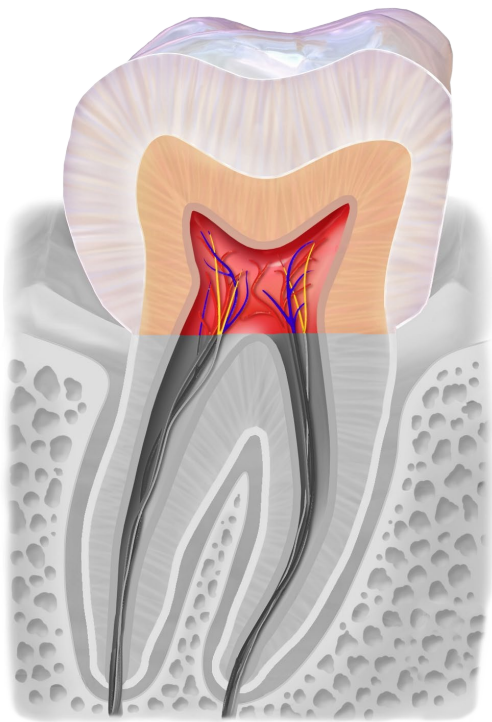
OSSO



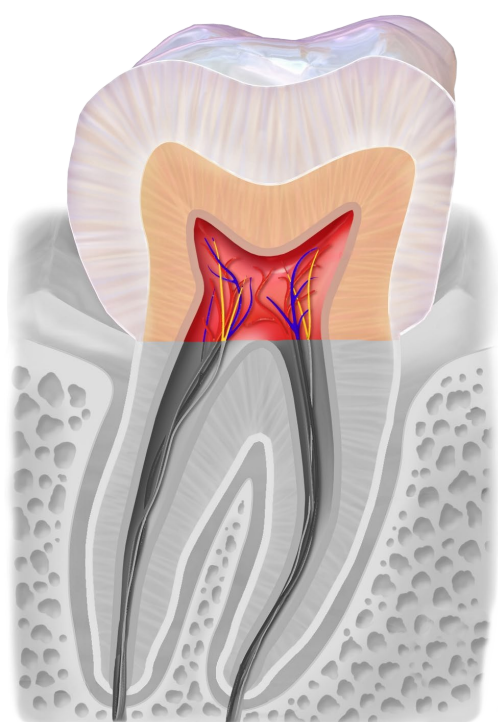
gingiva



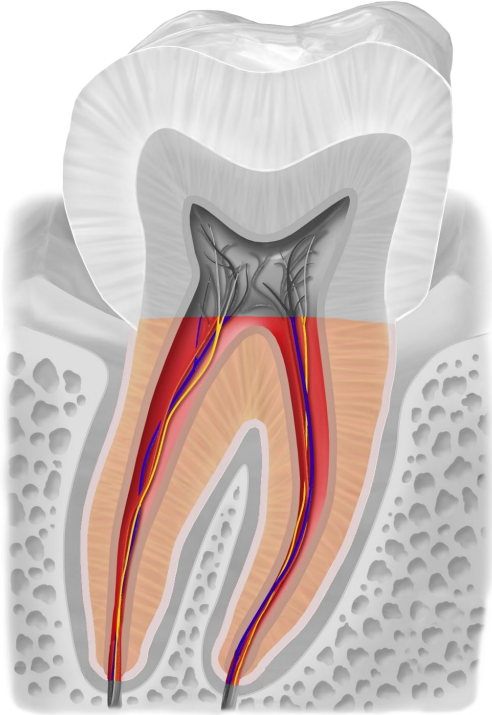
gingiva



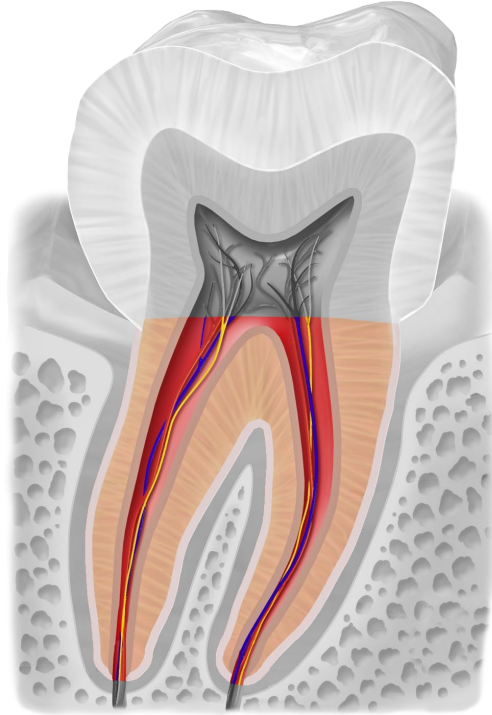
corona



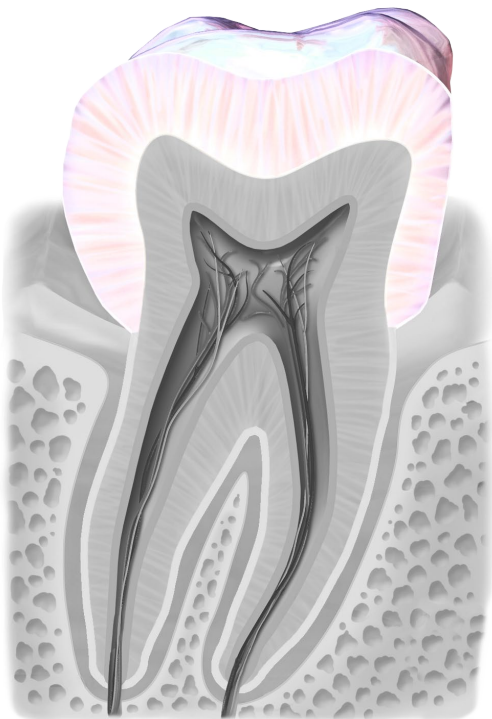
corona



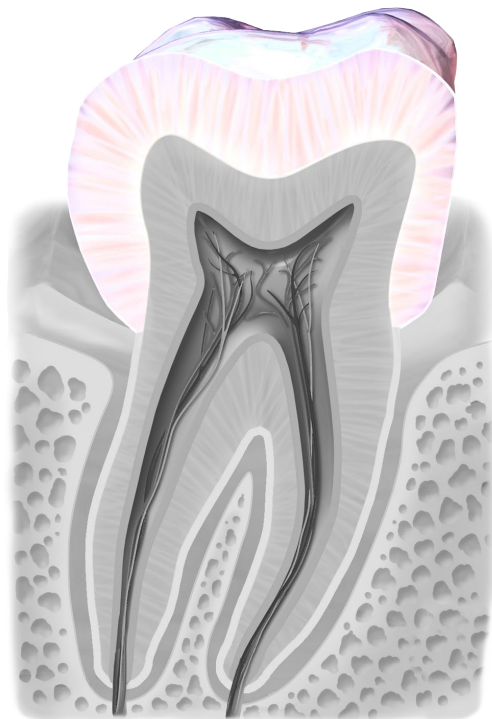
radice



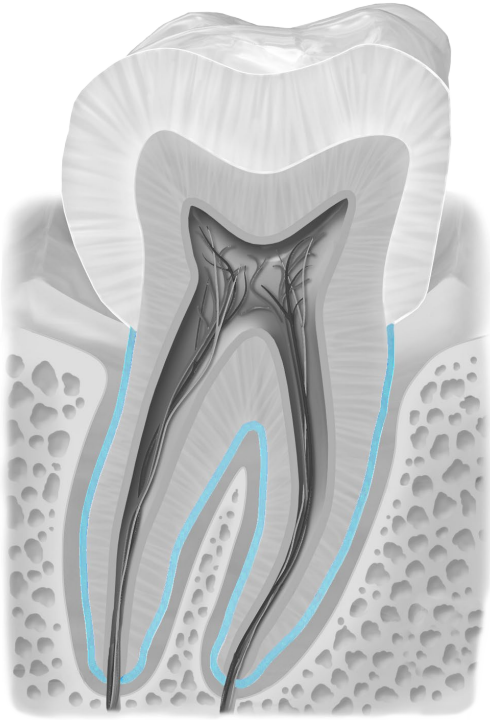
radice



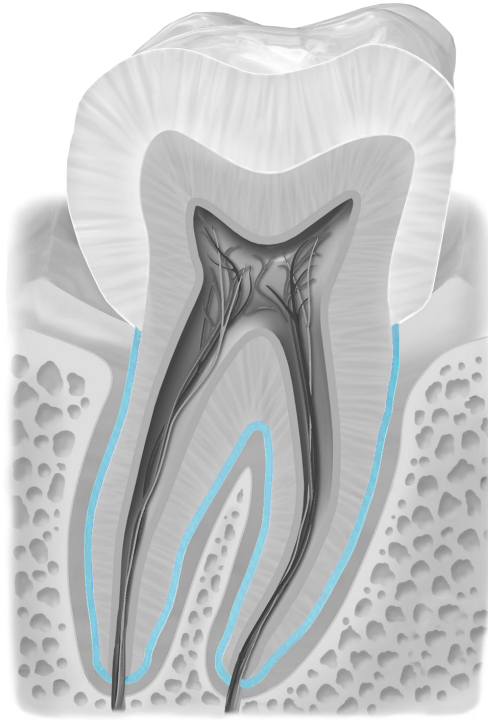
smalto



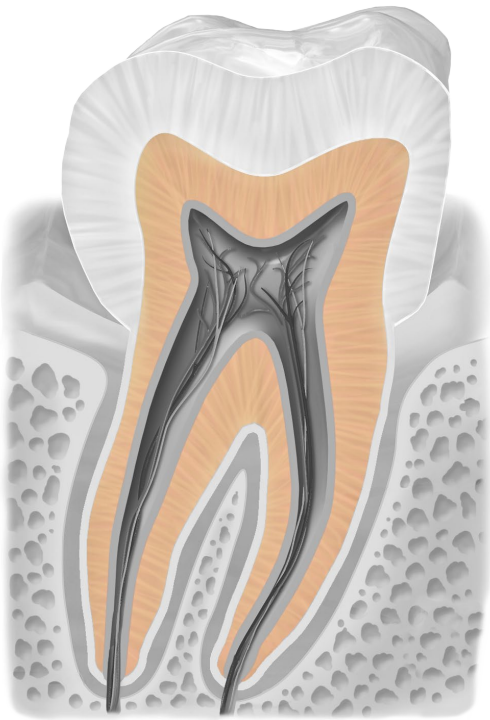
smalto



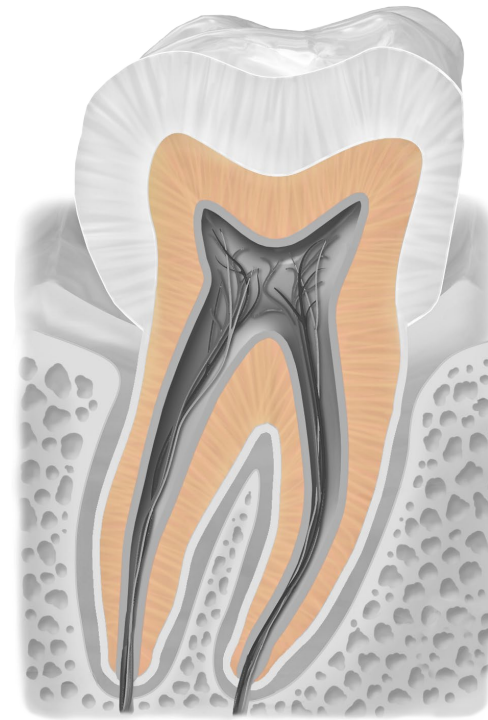
cemento



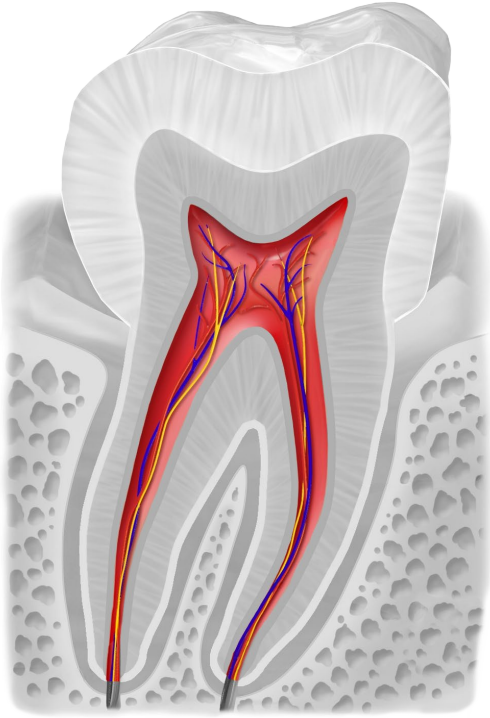
cemento



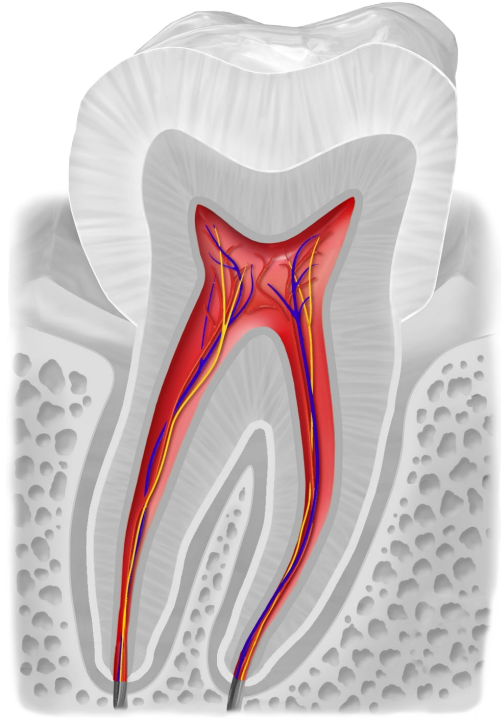
dentina



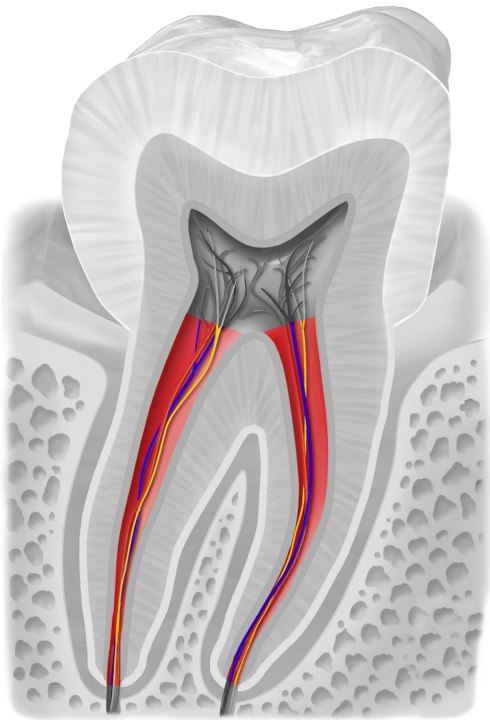
dentina



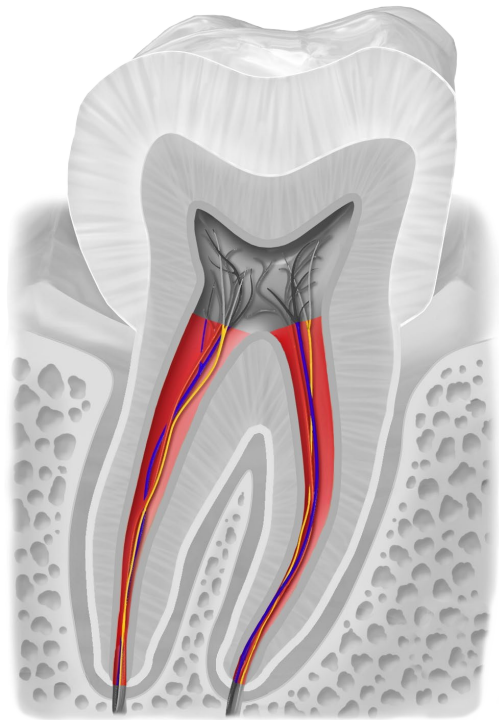
polpa con vasi sanguigni e nervi



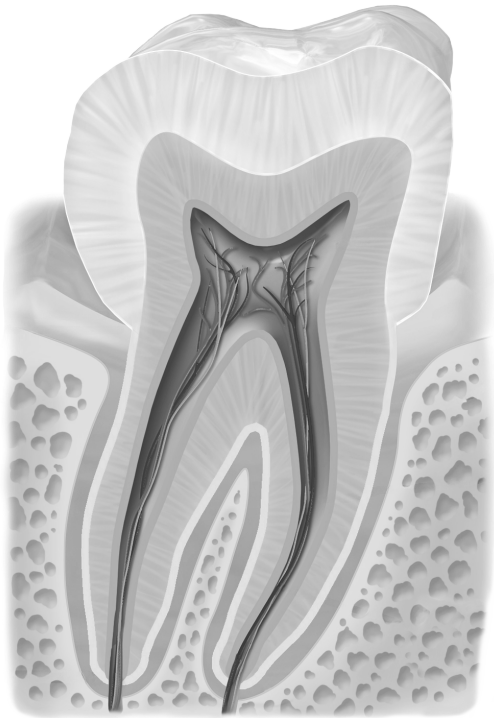
polpa con vasi sanguigni e nervi



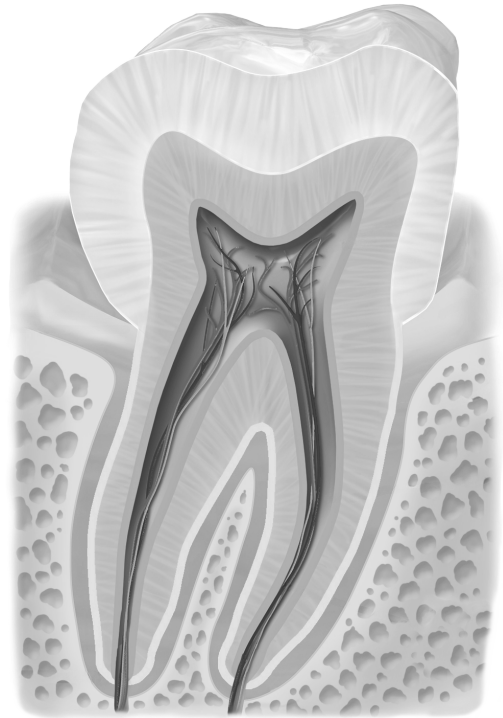canale radicolare



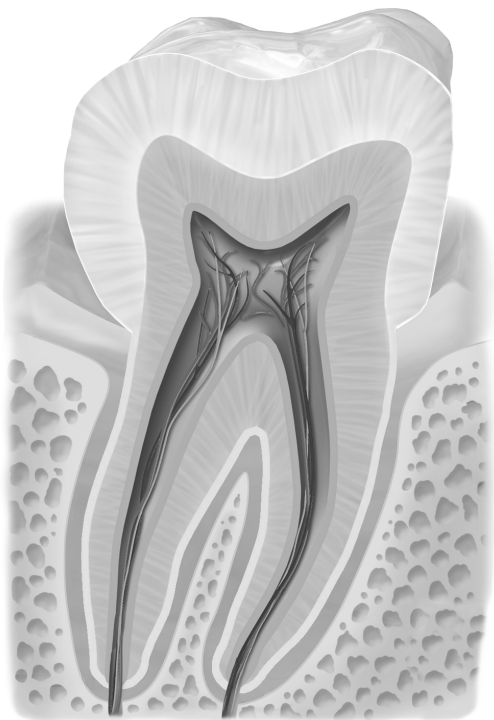
canale radicolare



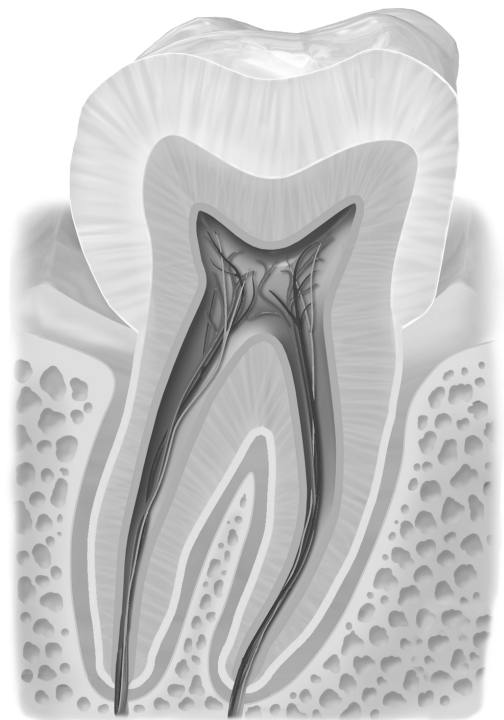
dente bianco/nero



dente bianco/nero



dente bianco/nero



dente bianco/nero

Quellen

[BruceBlaus](#). When using this image in external sources it can be cited as:
Blausen.com staff (2014). "[Medical gallery of Blausen Medical 2014](#)". WikiJournal of
Medicine 1 (2). [DOI:10.15347/wjm/2014.010](#). [ISSN 2002-4436](#)., [Blausen 0863](#)
[ToothAnatomy 02](#), Beschriftung entfernt, Zahn schwarz/weiß eingefärbt und einzelne
anatomische Teile farbig draufgelegt, [CC BY 3.0](#)