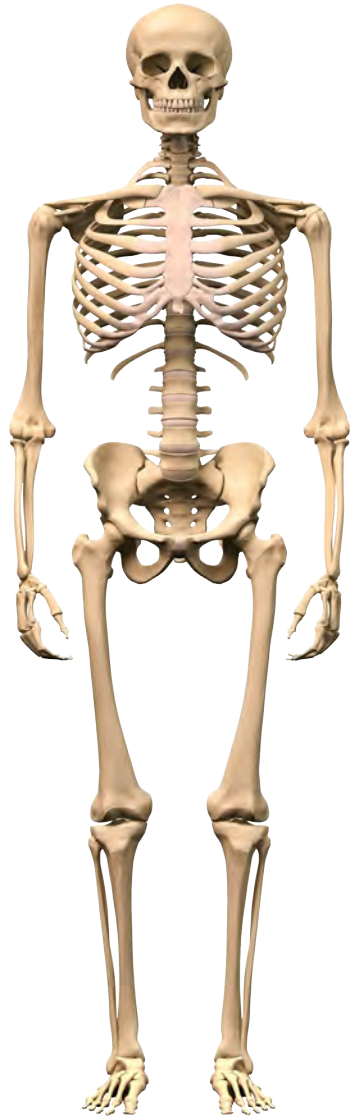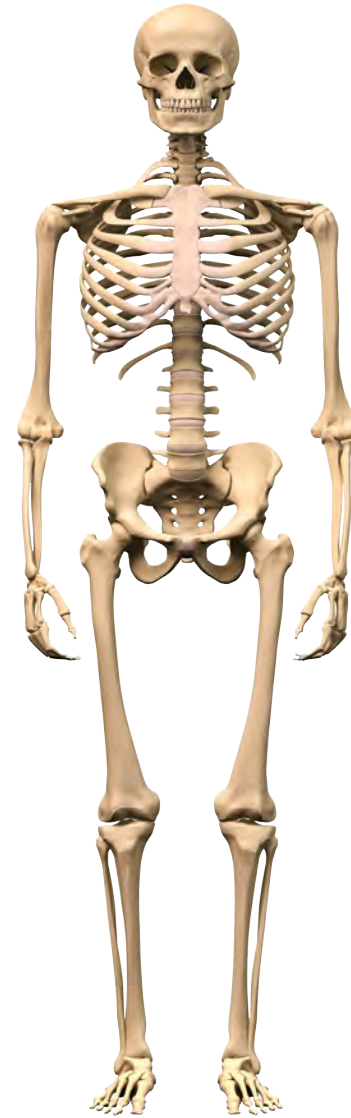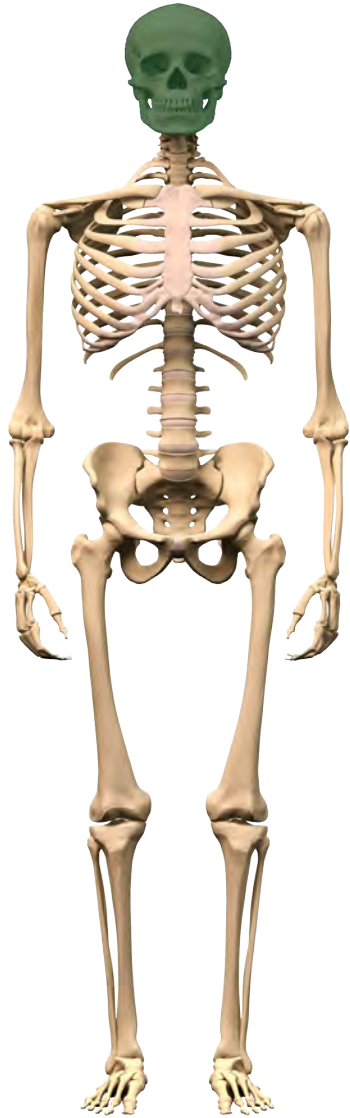


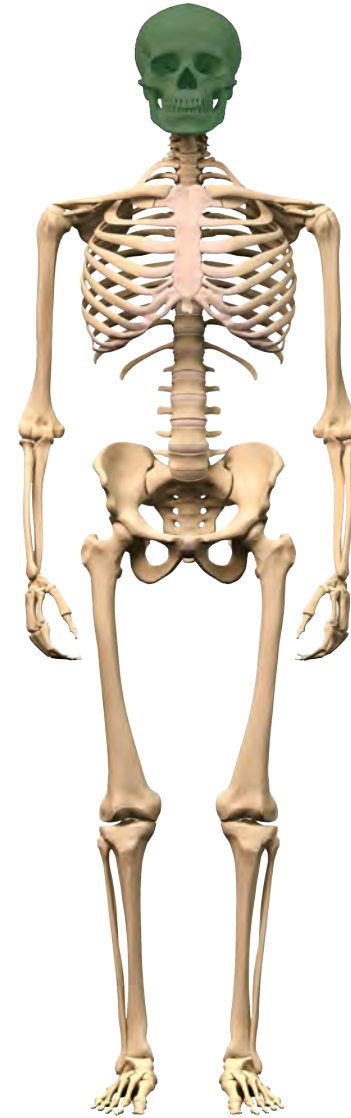le squelette



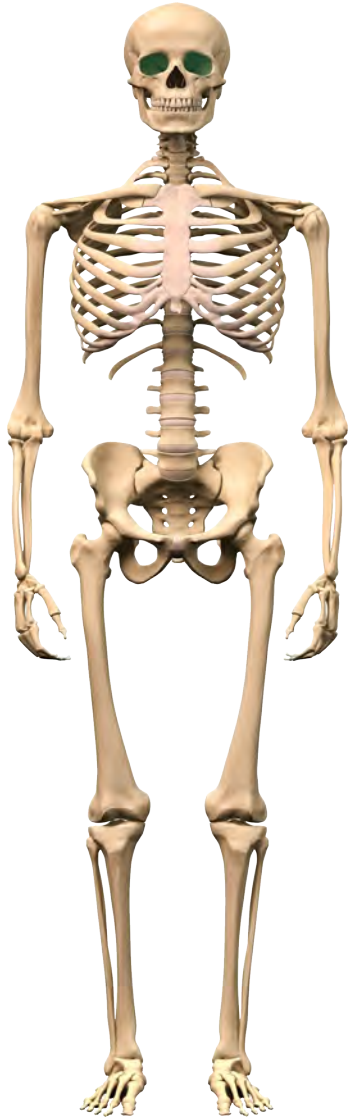
le squelette



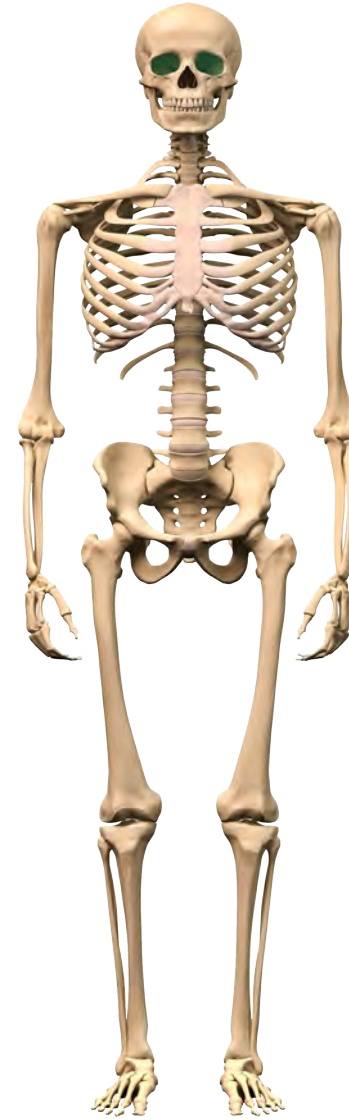le crâne



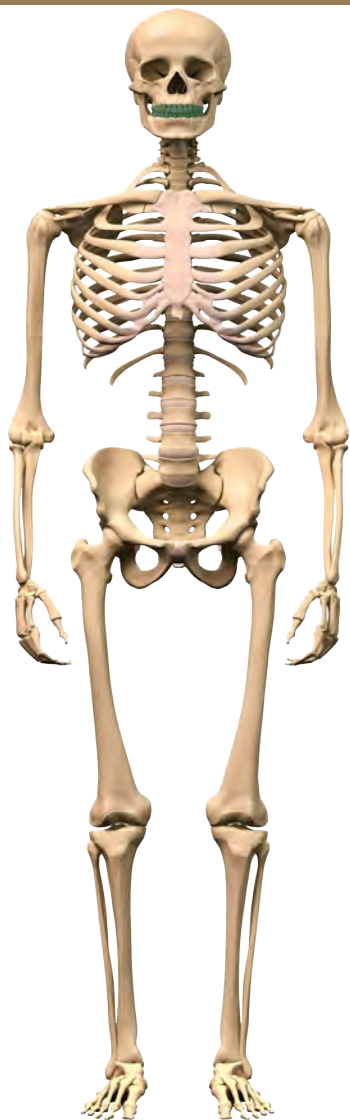
le crâne



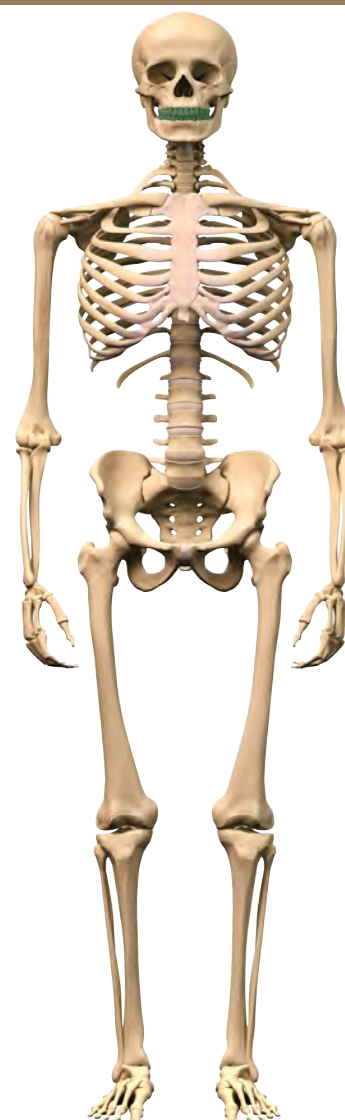
les orbites des yeux



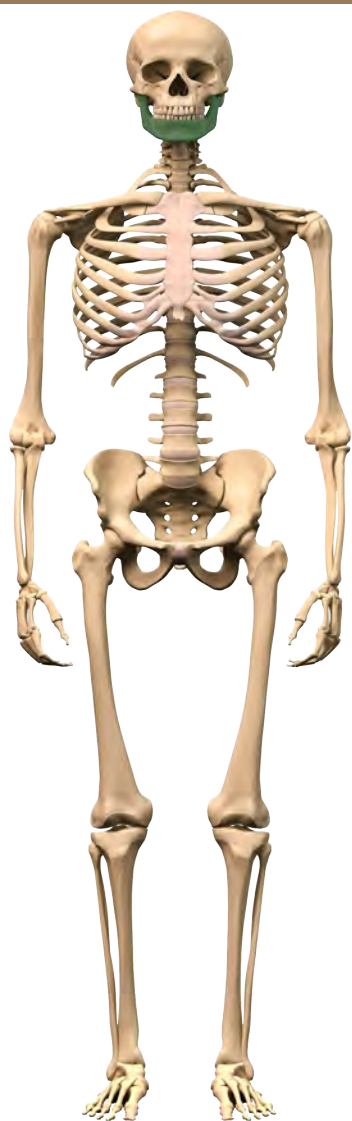
les orbites des yeux



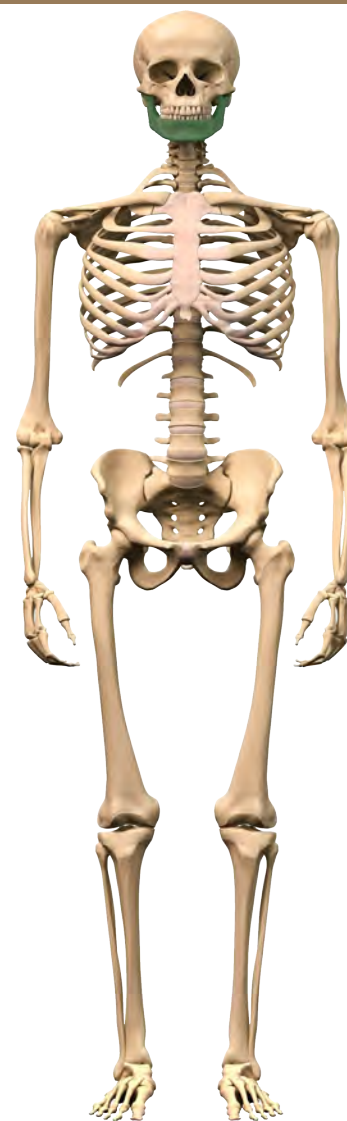les dents



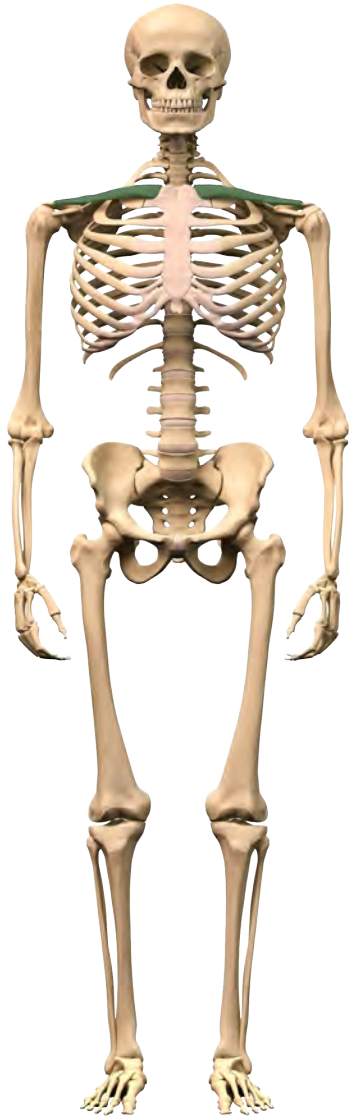
les dents



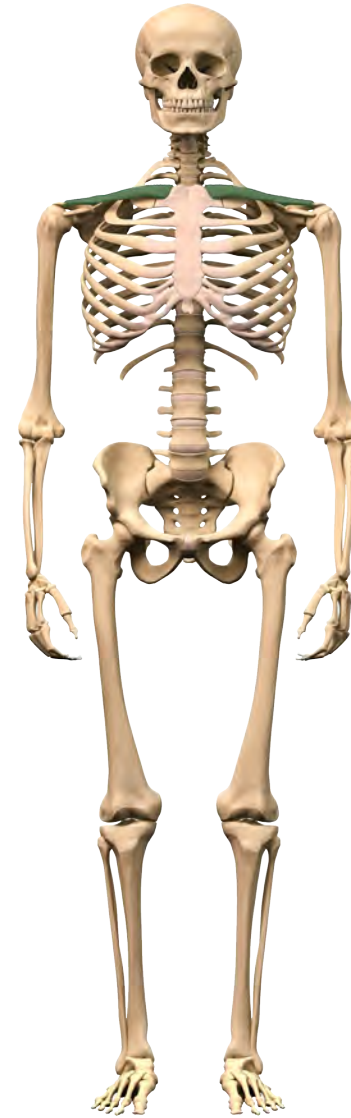la mandibule



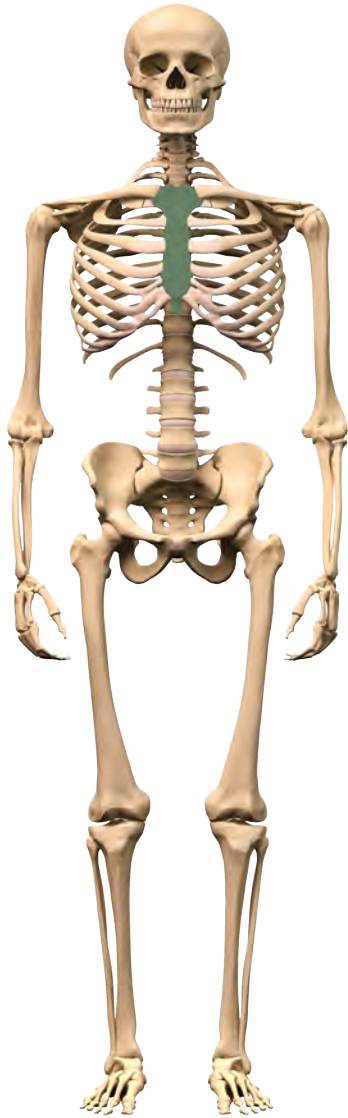
la mandibule



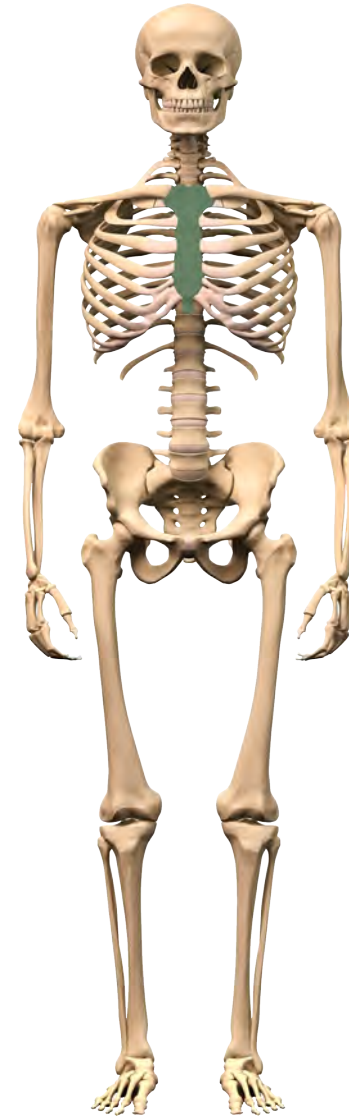la clavicule



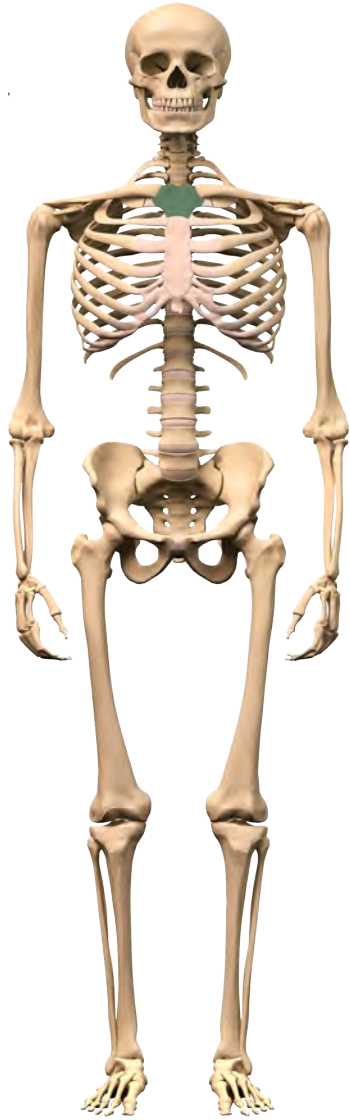
la clavicule



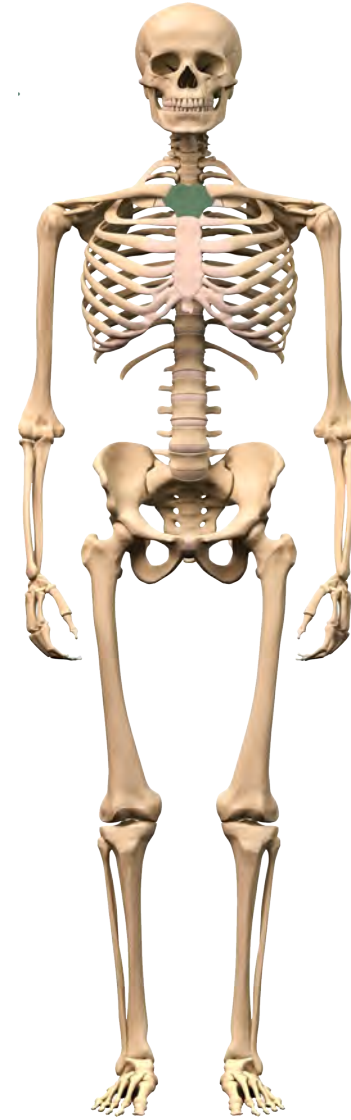le sternum



le sternum

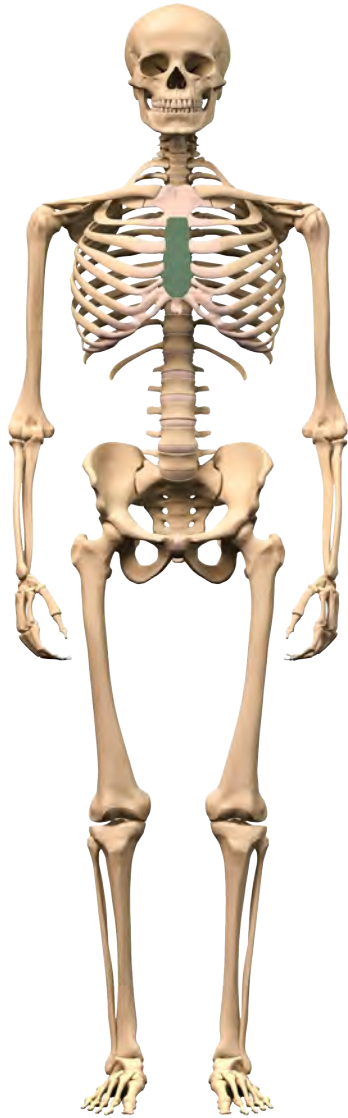


le manubrium

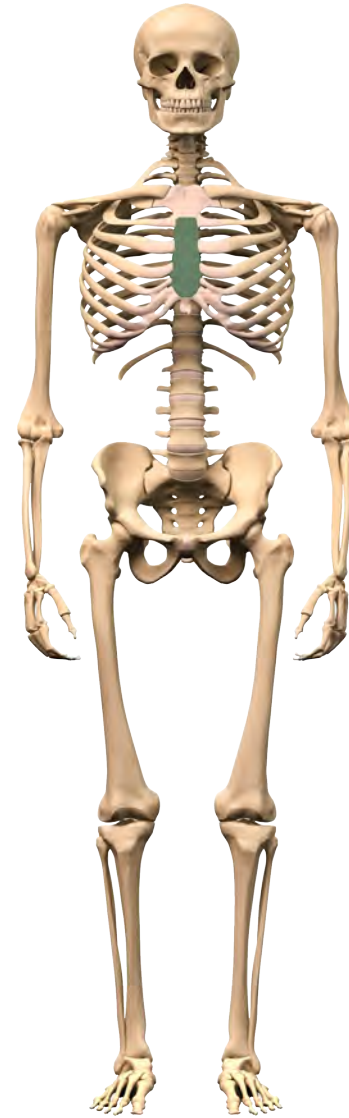

le manubrium

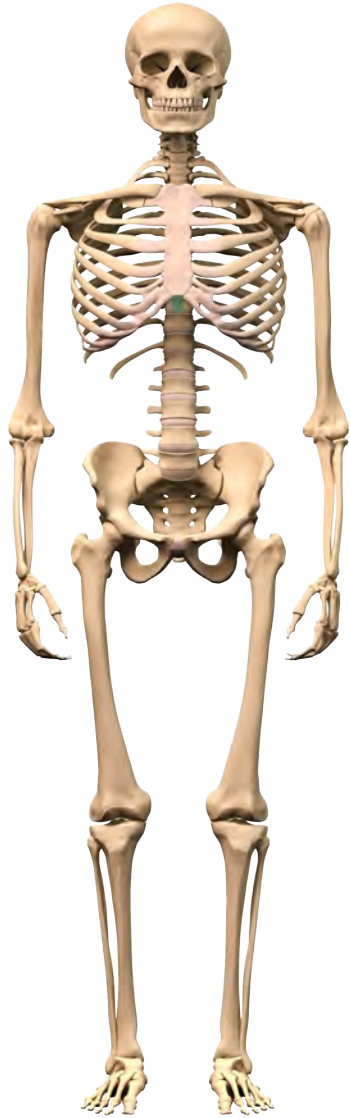




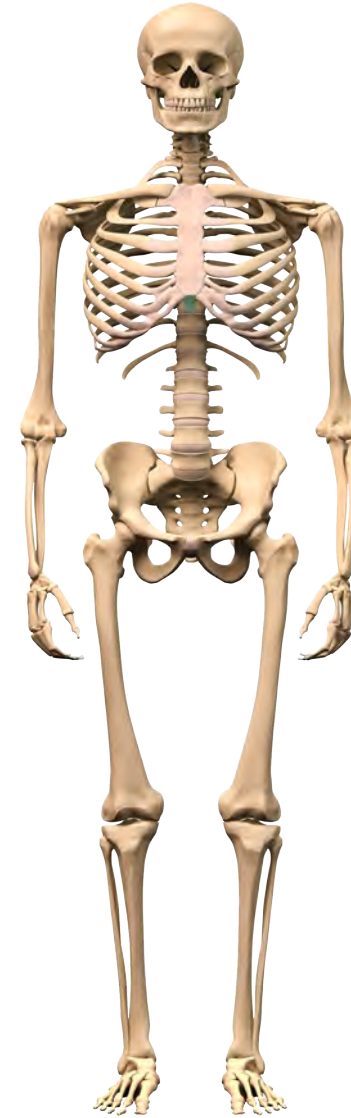le corpus sterni



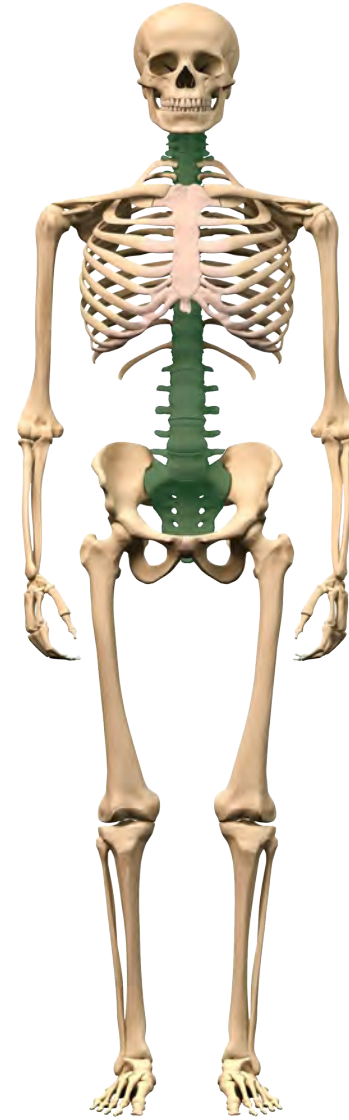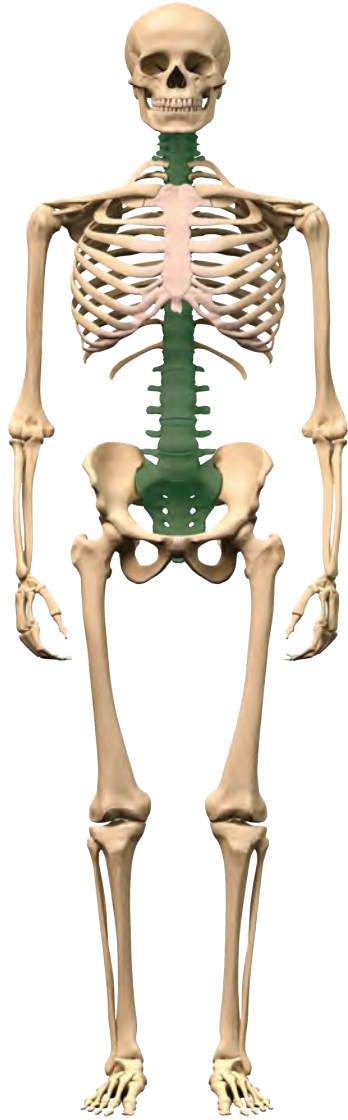
le corpus sterni

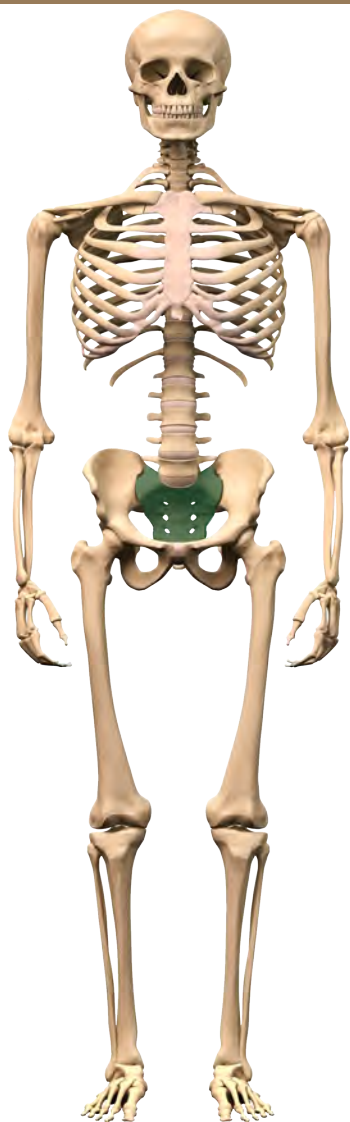


le processus xiphoideus

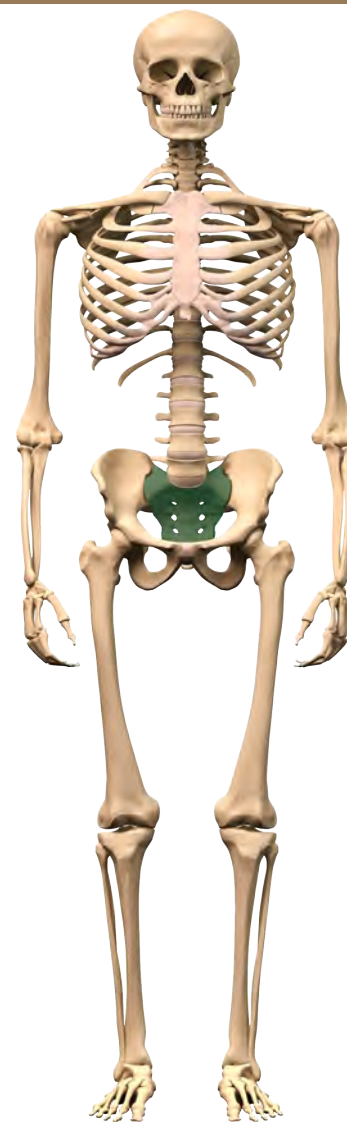


le processus xiphoideus

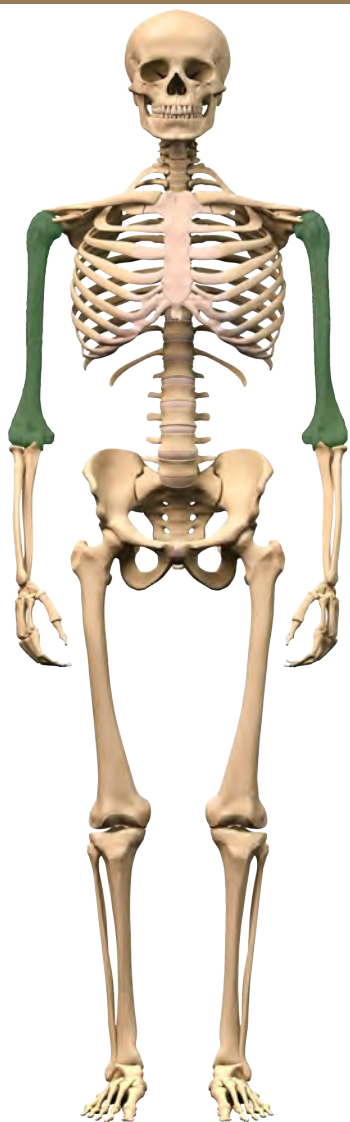




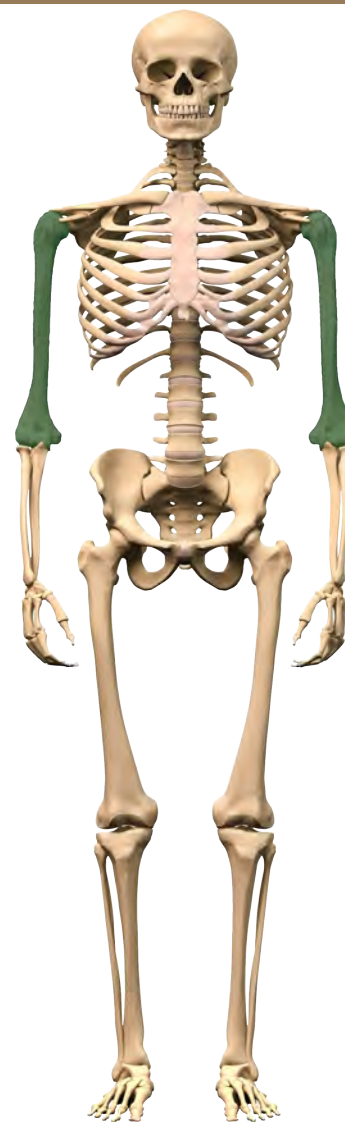
le sacrum



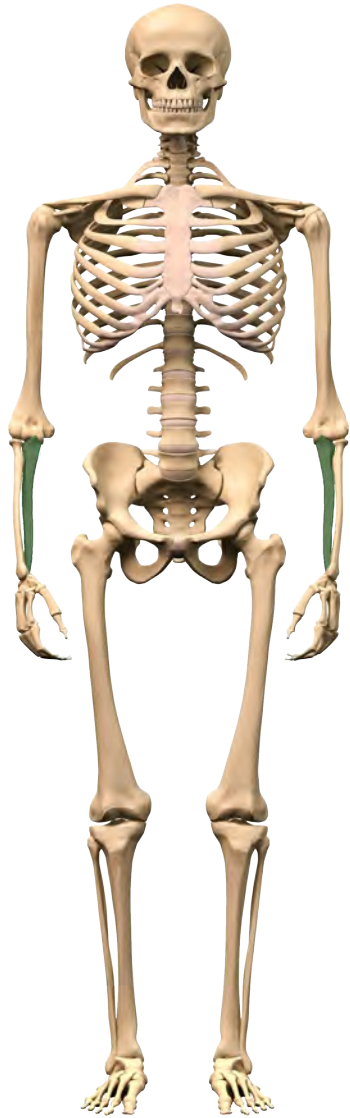
le sacrum



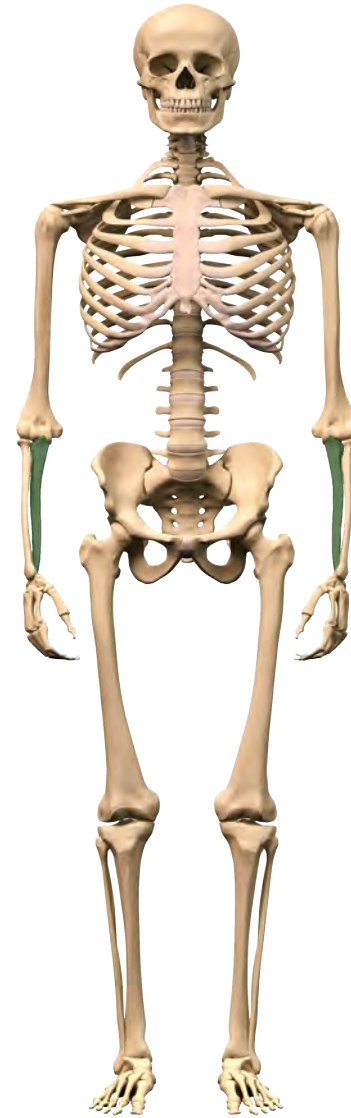
l'humérus



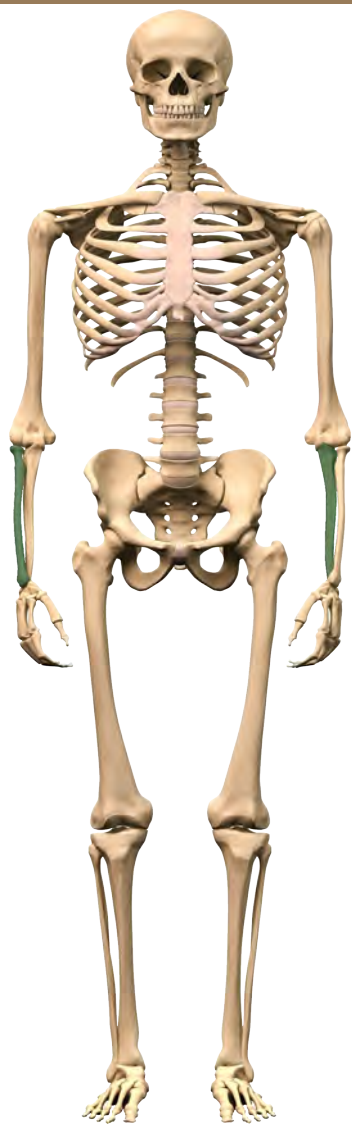
l'humérus



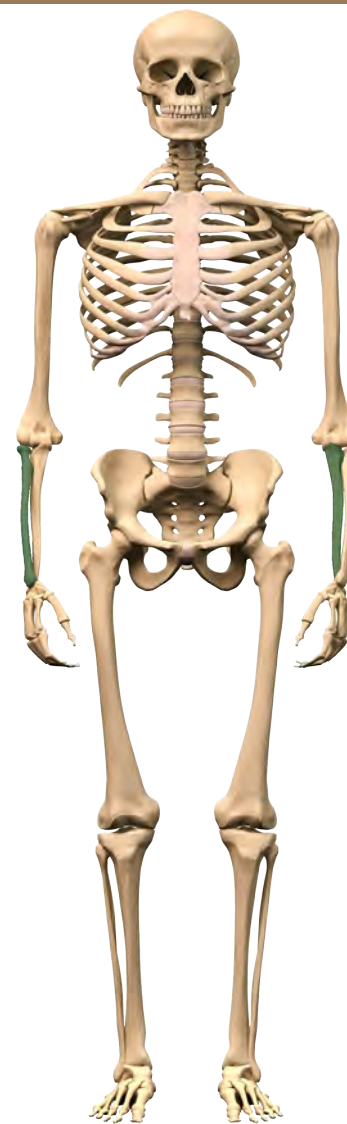l`ulna



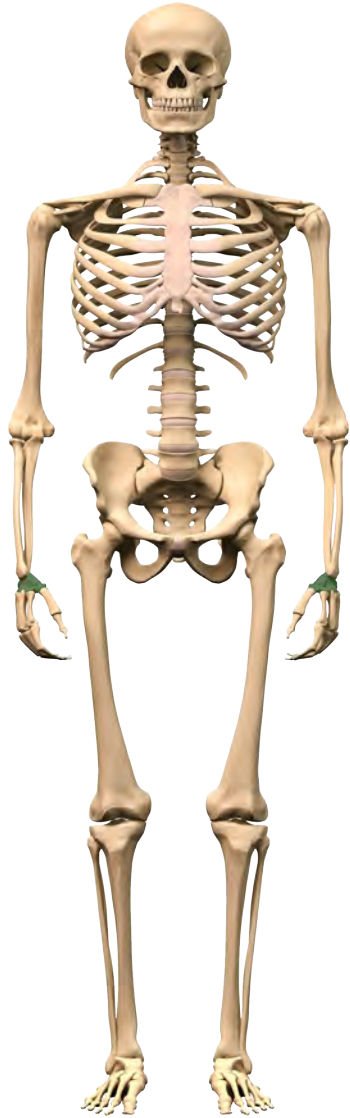
l`ulna



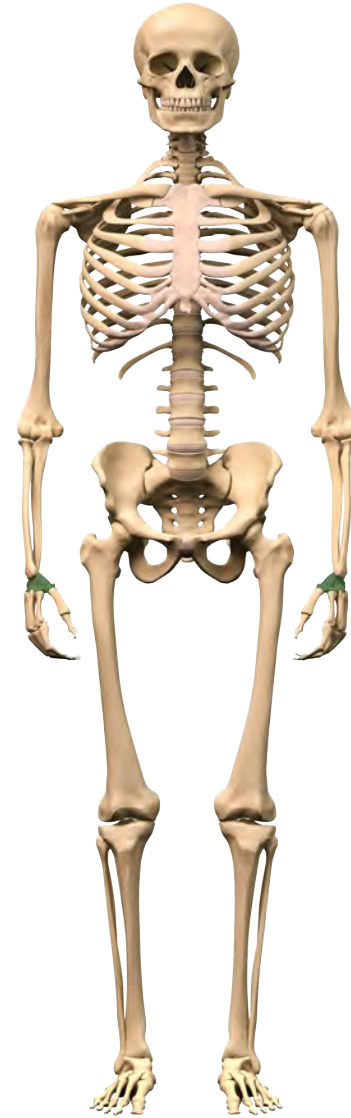le radius



le radius

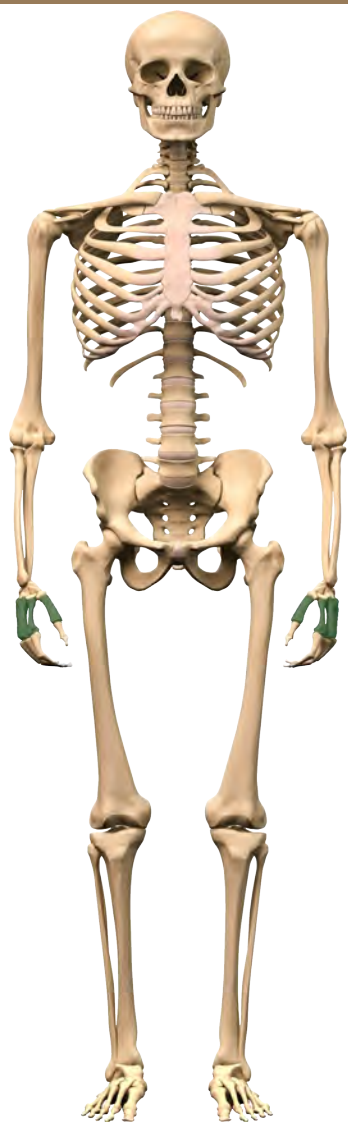


les os du carpe

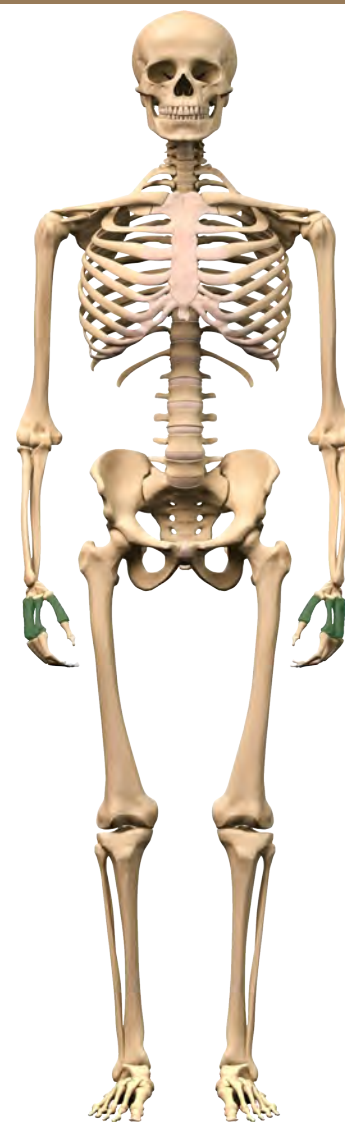


les os du carpe

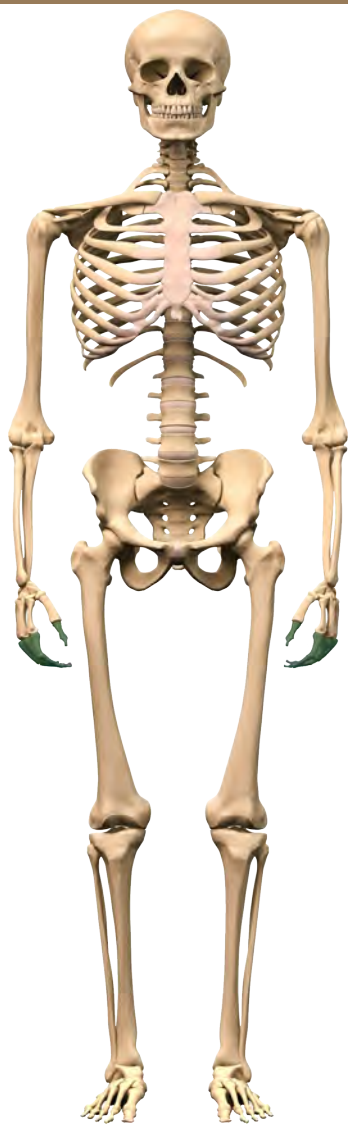




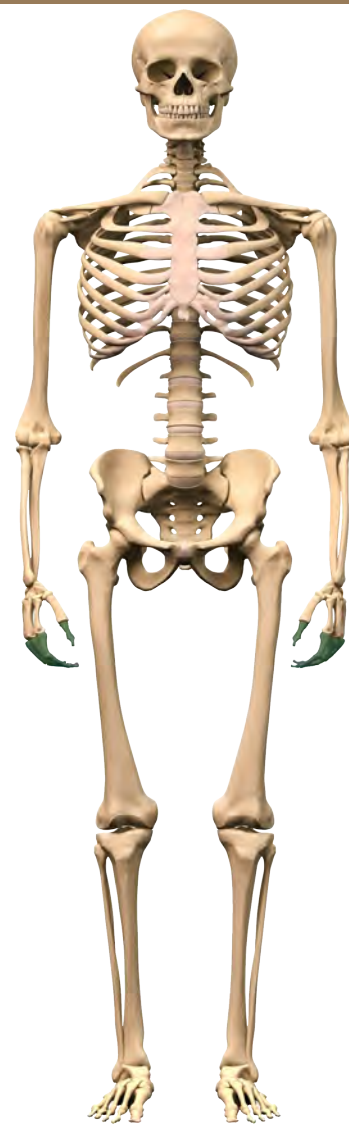
les métacarpes



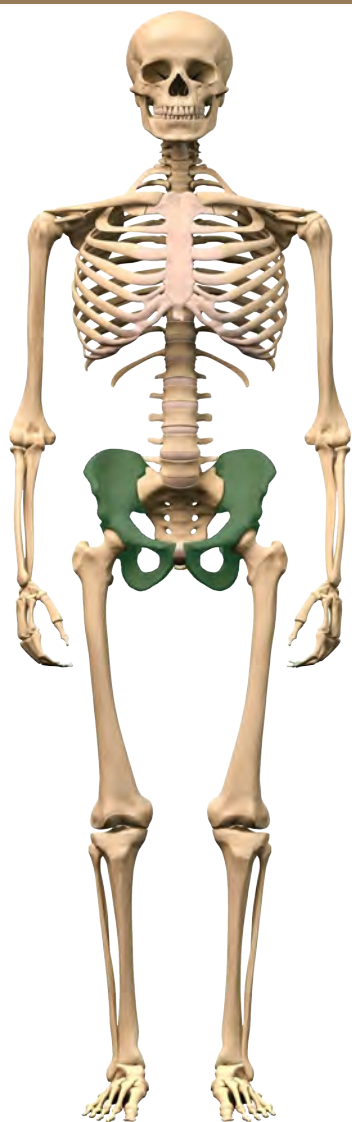
les métacarpes



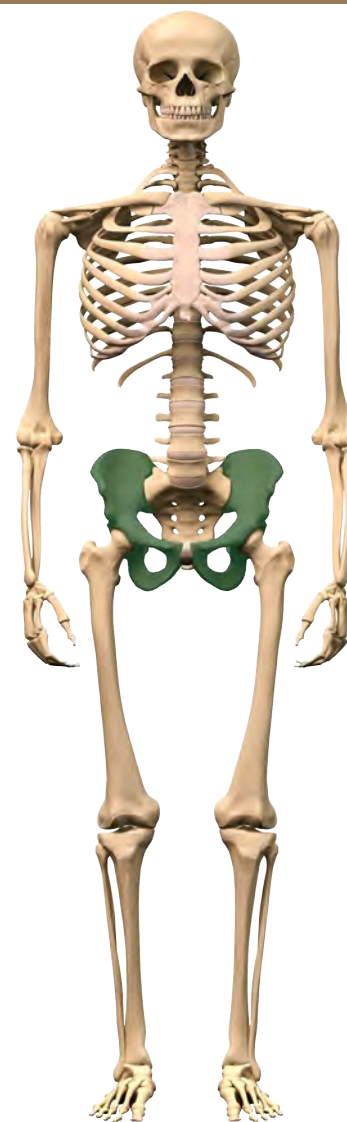les phalanges du main



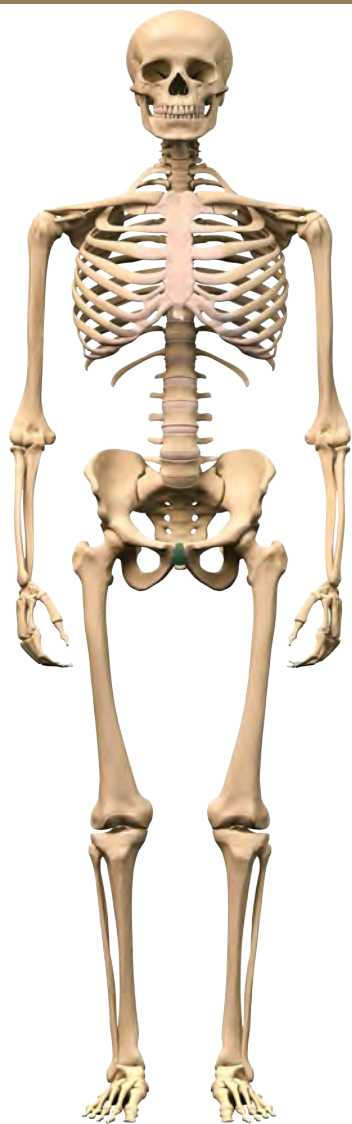
les phalanges du main



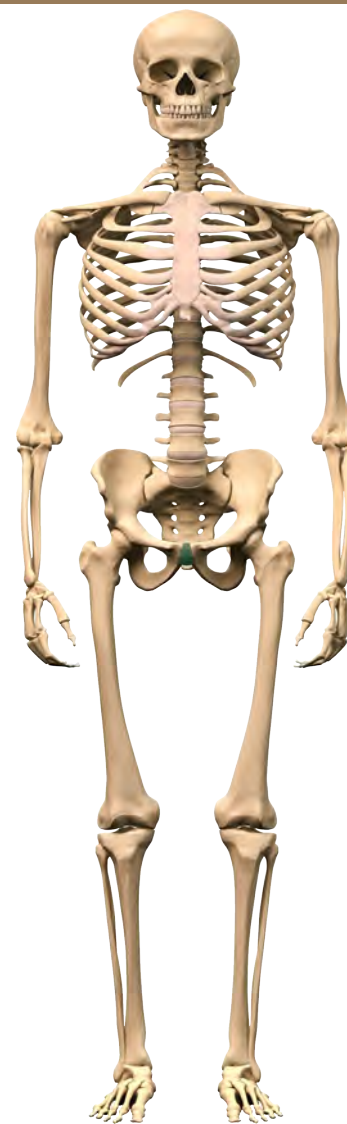le bassin



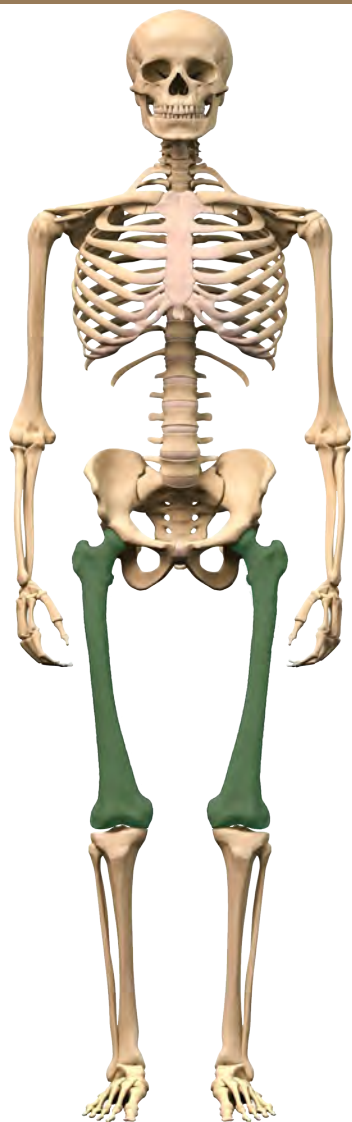
le bassin



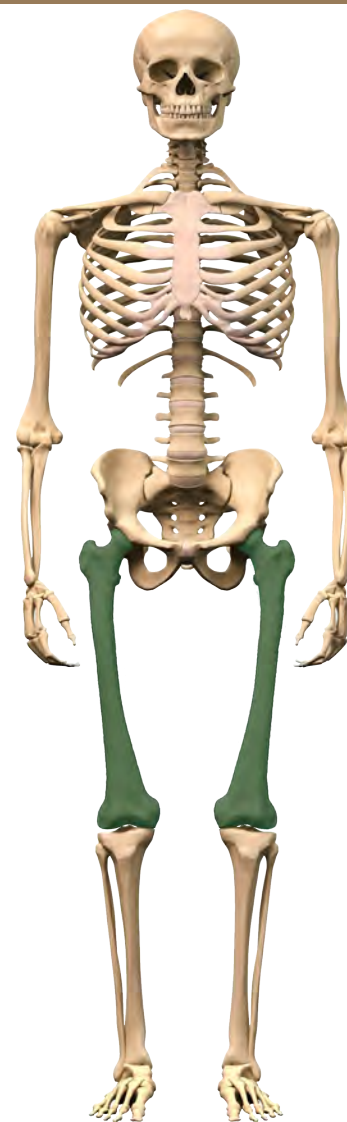
la symphyse pubienne



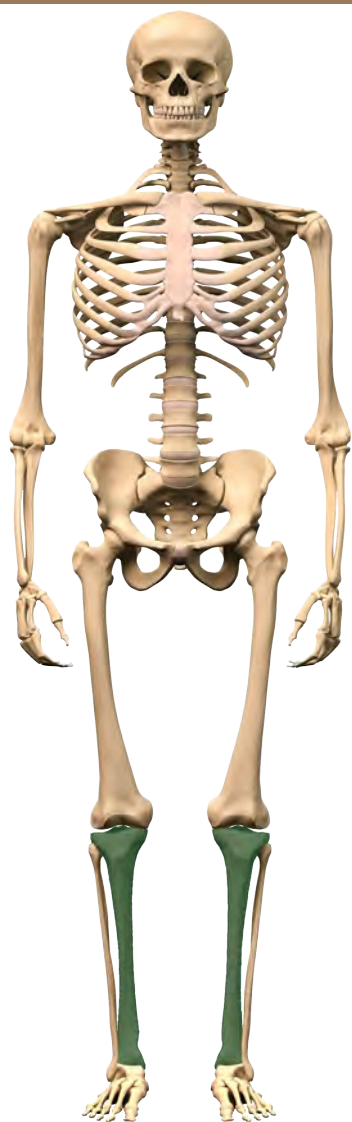
la symphyse pubienne



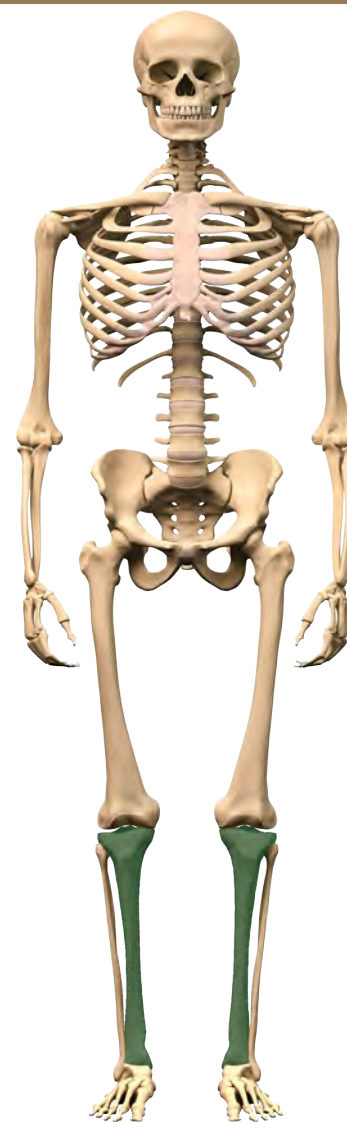le fémur



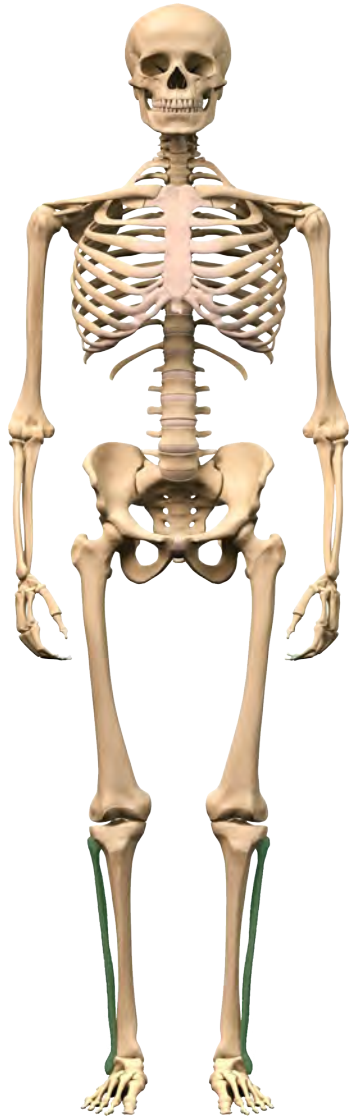
le fémur



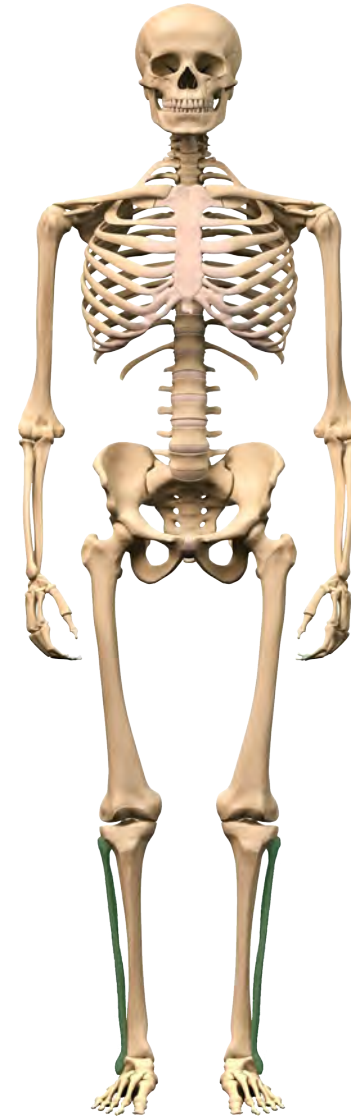le tibia



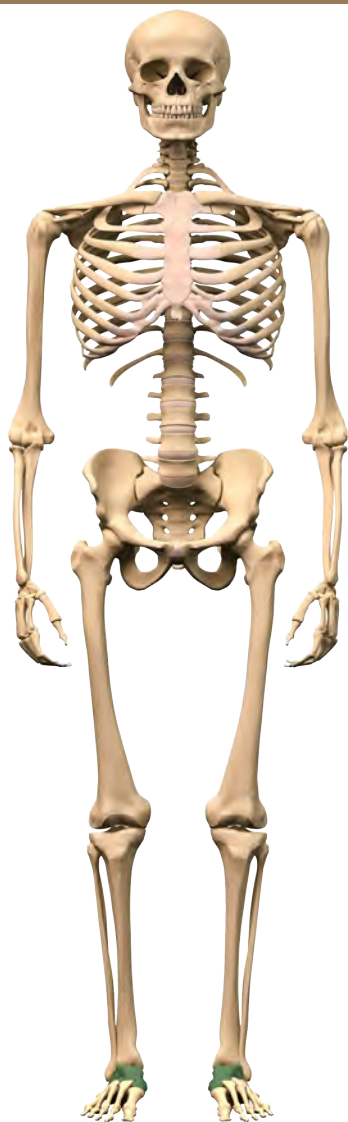
le tibia



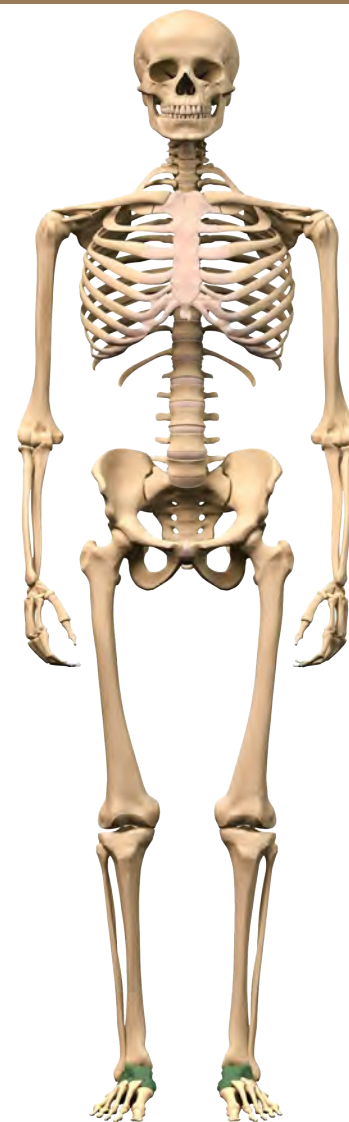la fibula



la fibula

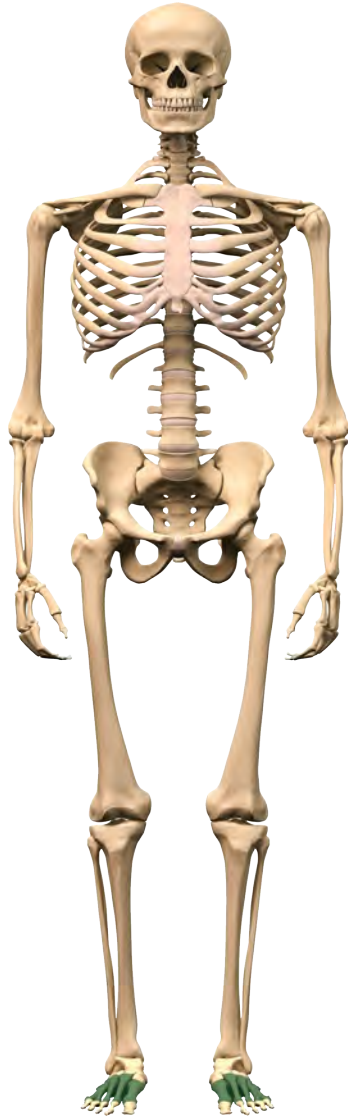


les os du tarse

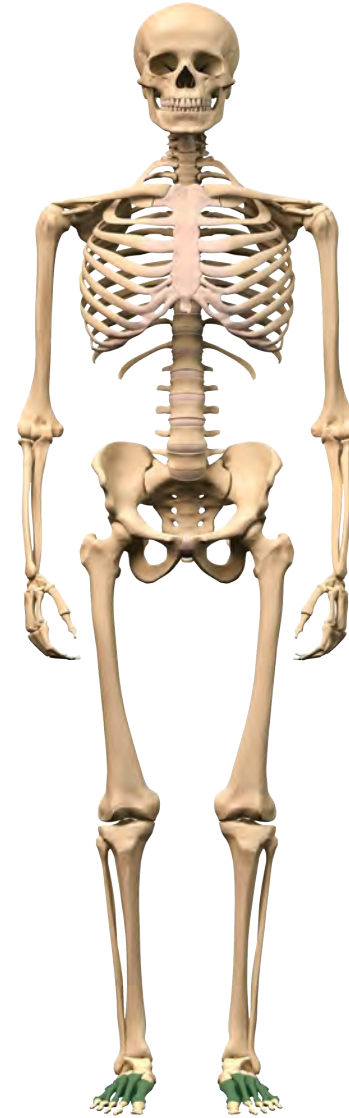

les os du tarse

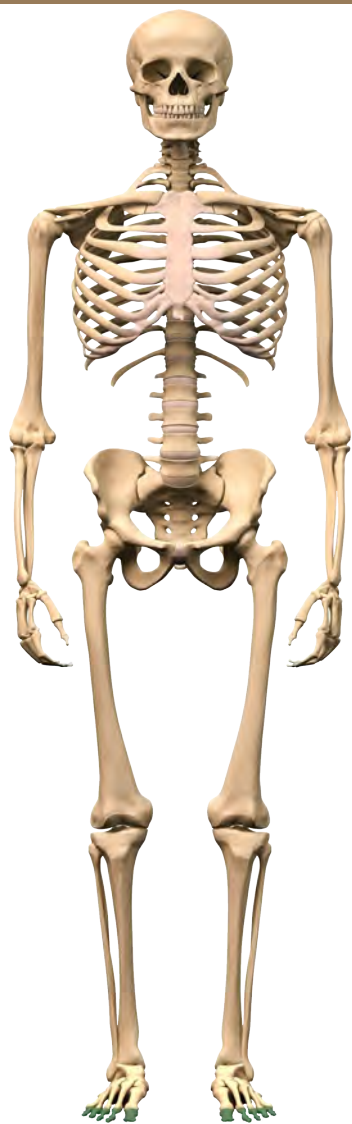




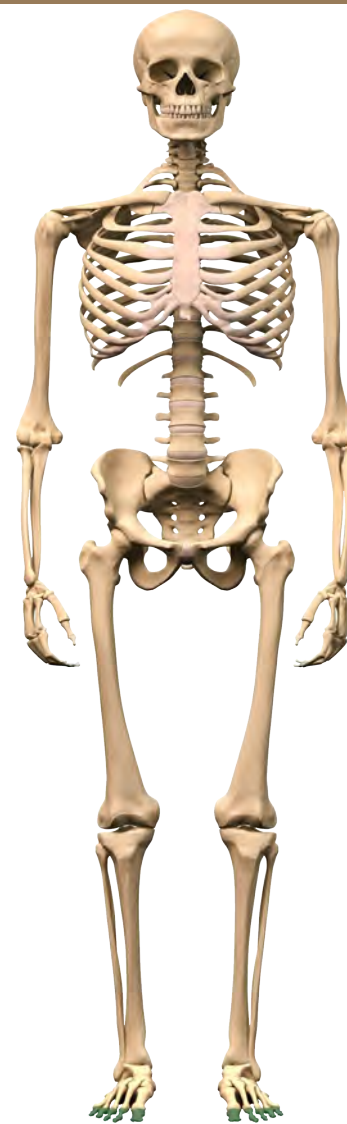les métatarses du pied



les métatarses du pied



les phalanges du pied



les phalanges du pied