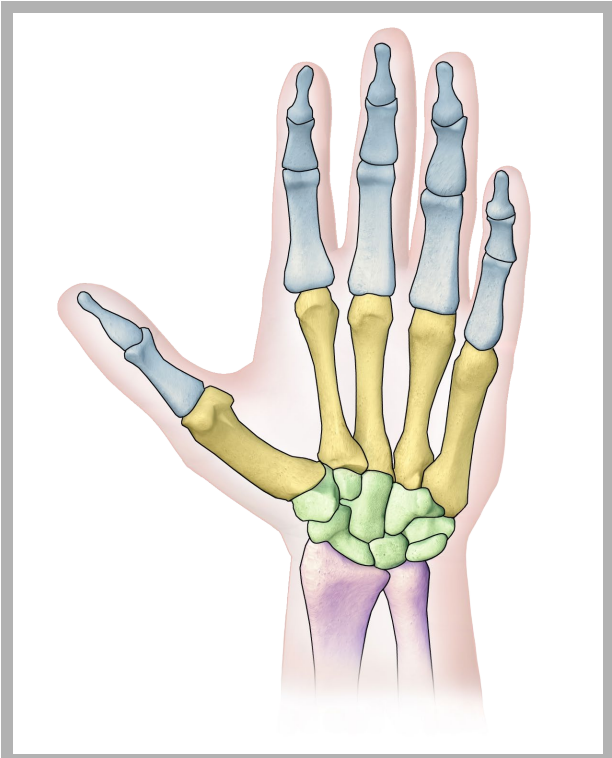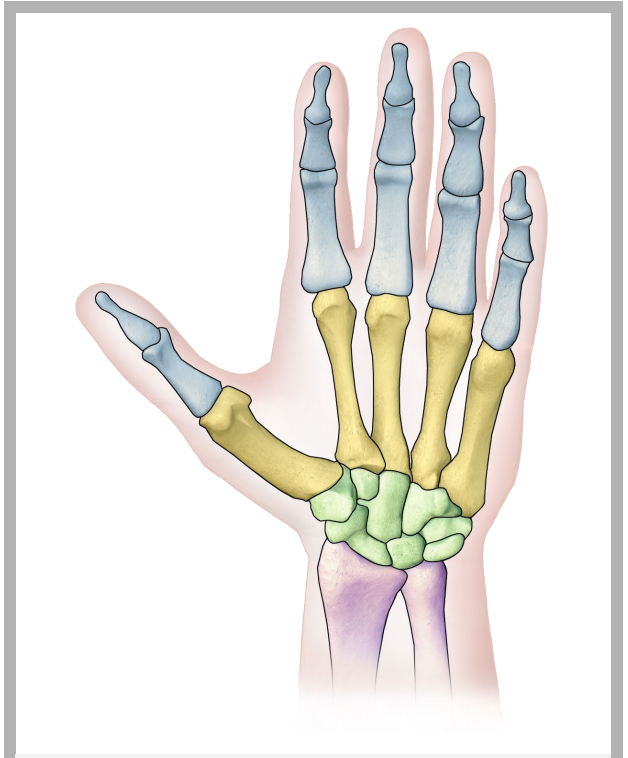
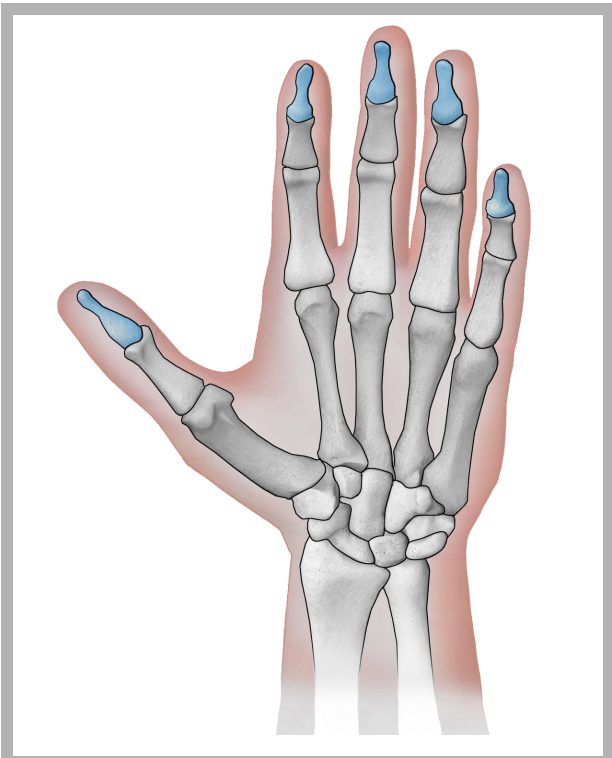


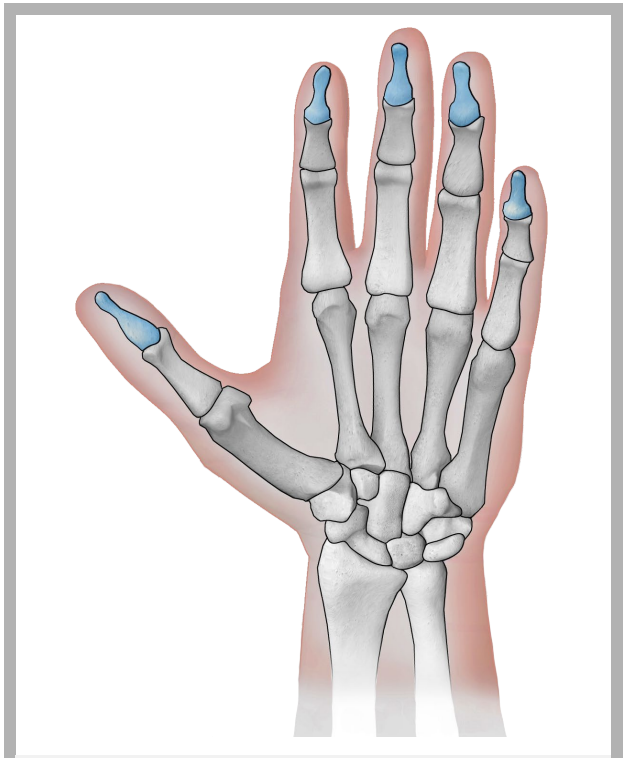
hand bones



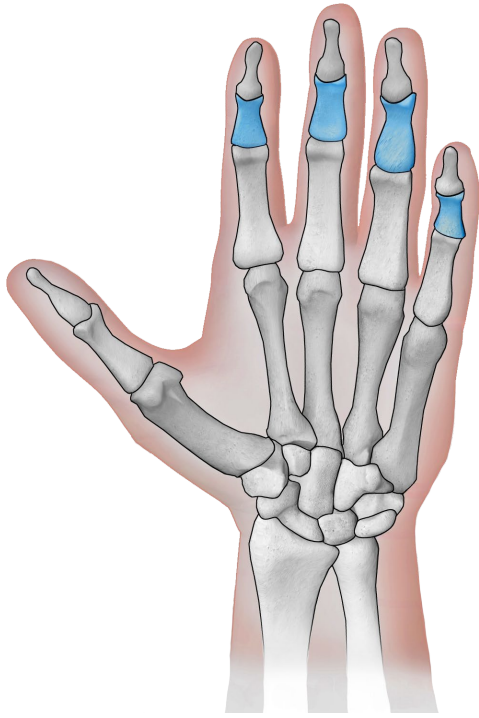
hand bones



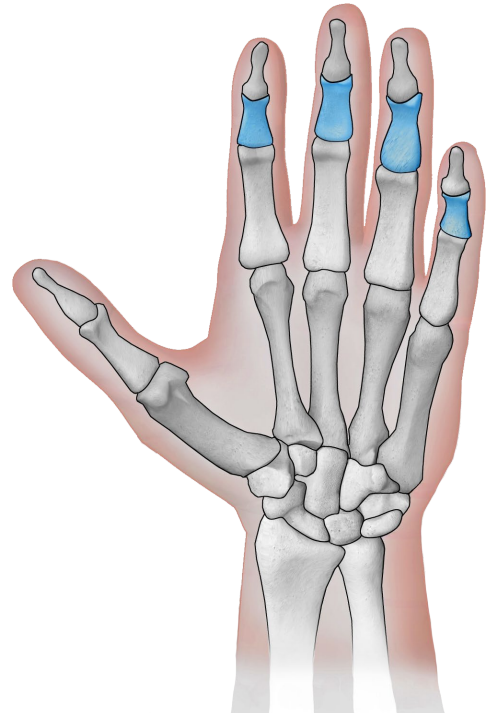
distal phalanges



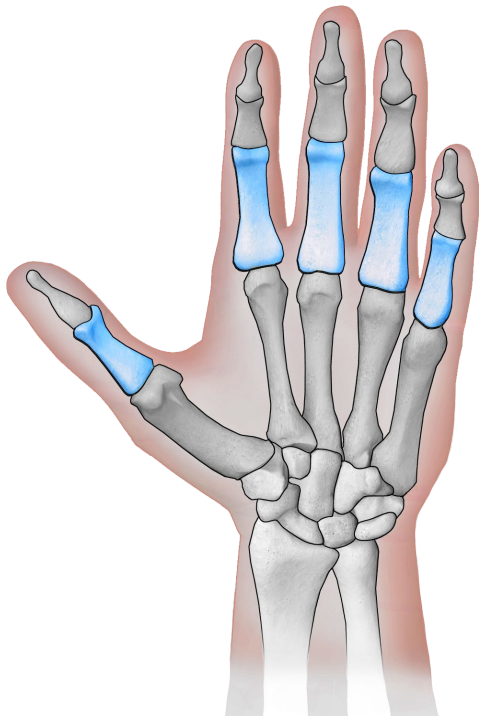
distal phalanges



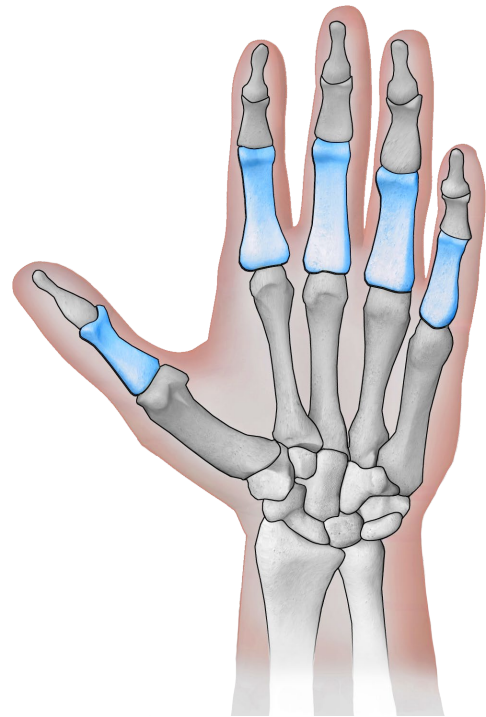
intermediate
phalanges



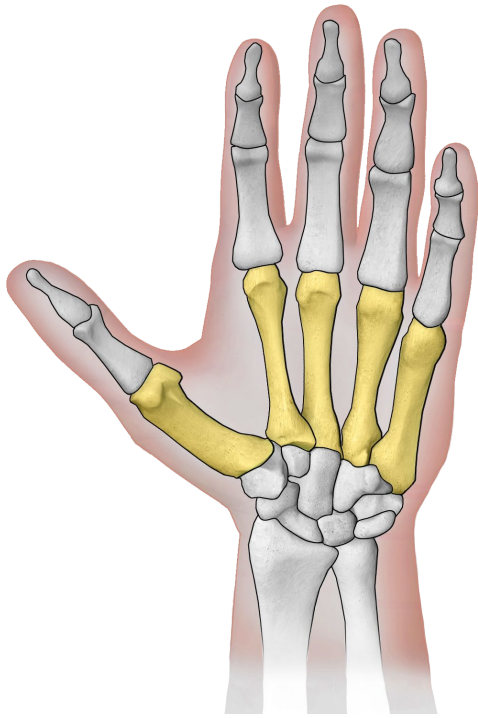
intermediate
phalanges



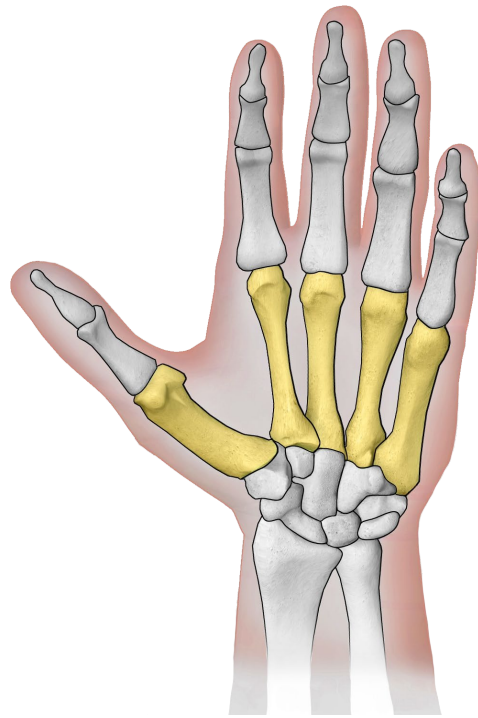
proximal phalanges



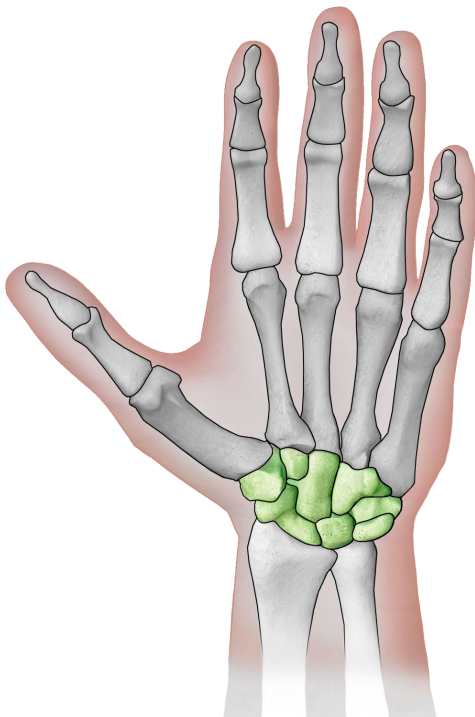
proximal phalanges



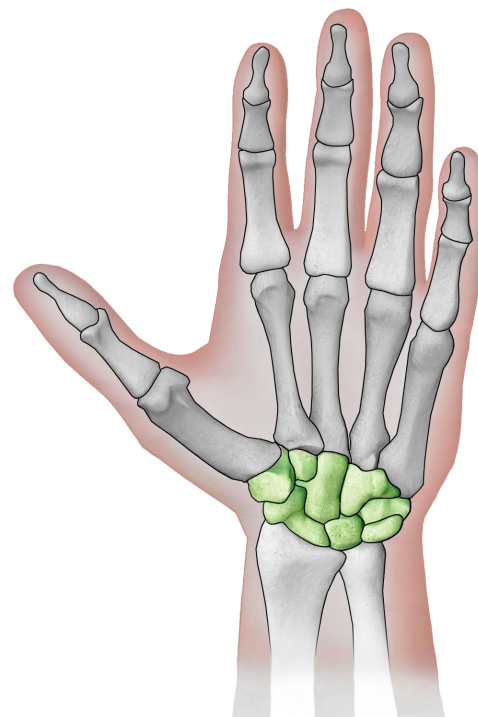
metacarpals



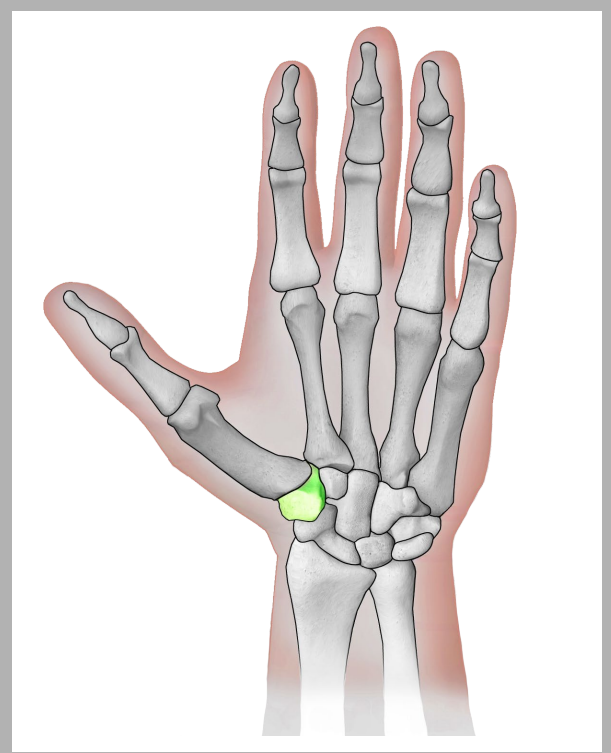
metacarpals



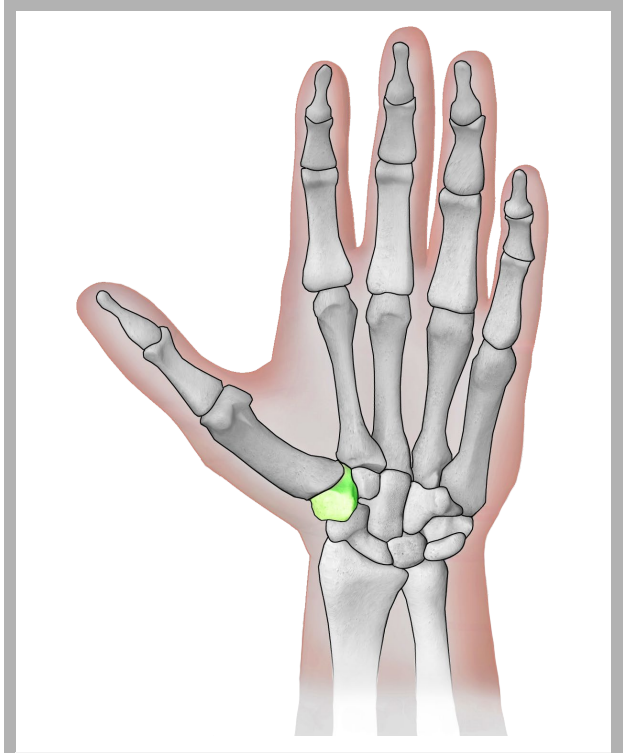
wrist bones (carpals)



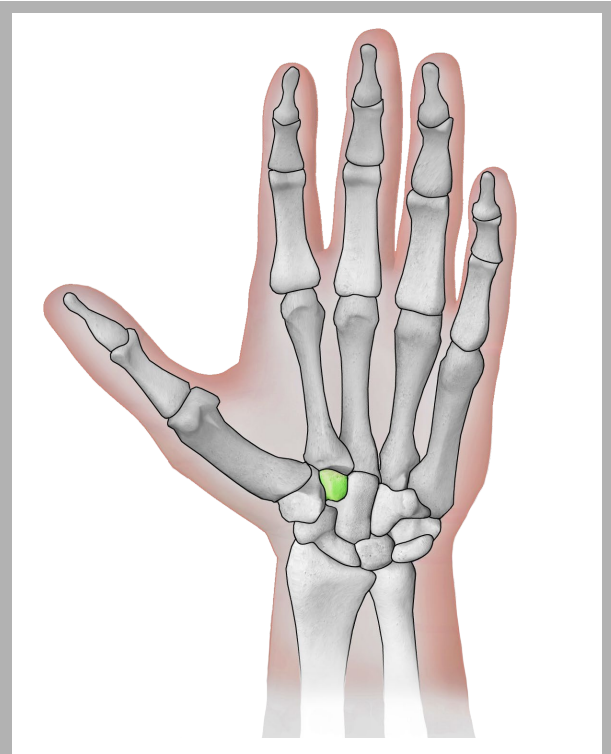
wrist bones (carpals)



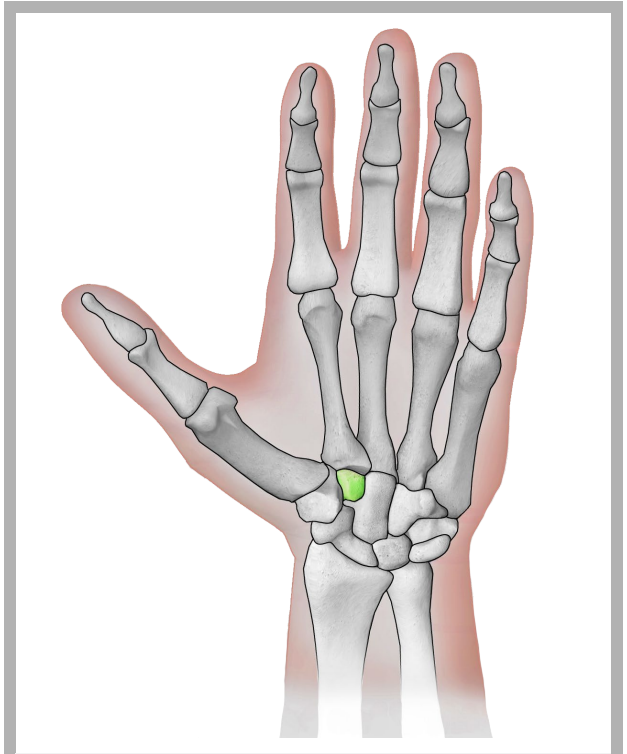
trapezium



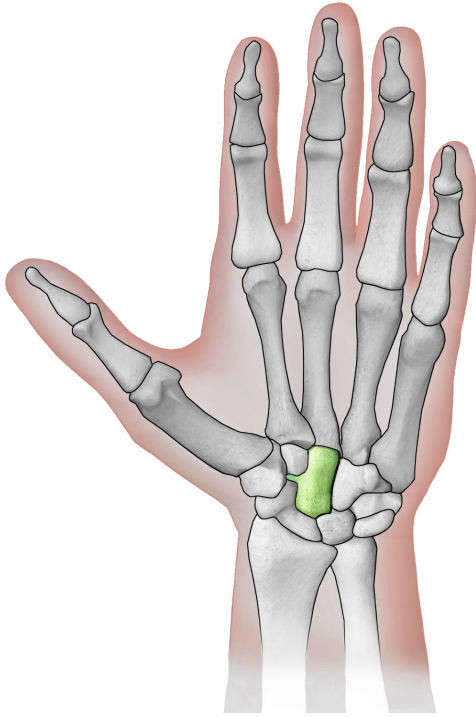
trapezium



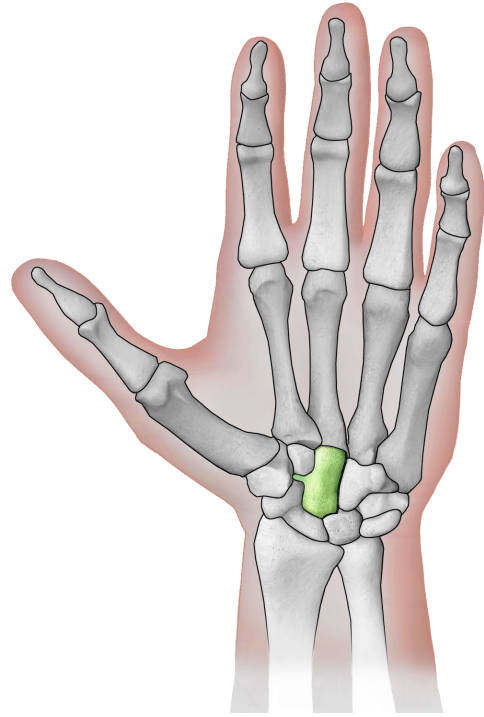
trapezoid



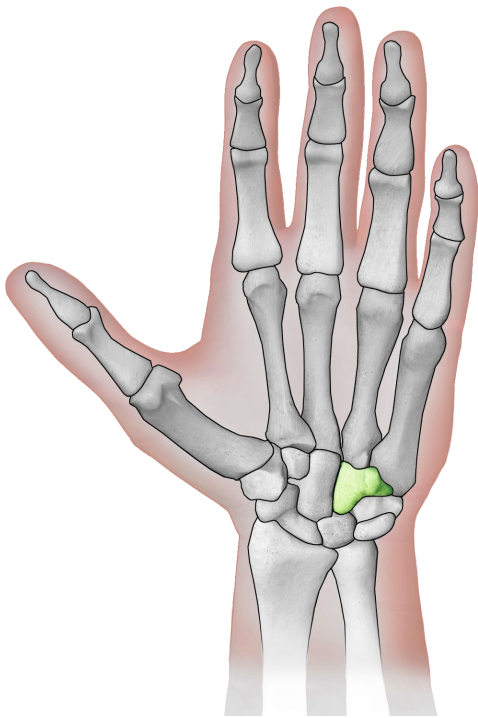
trapezoid



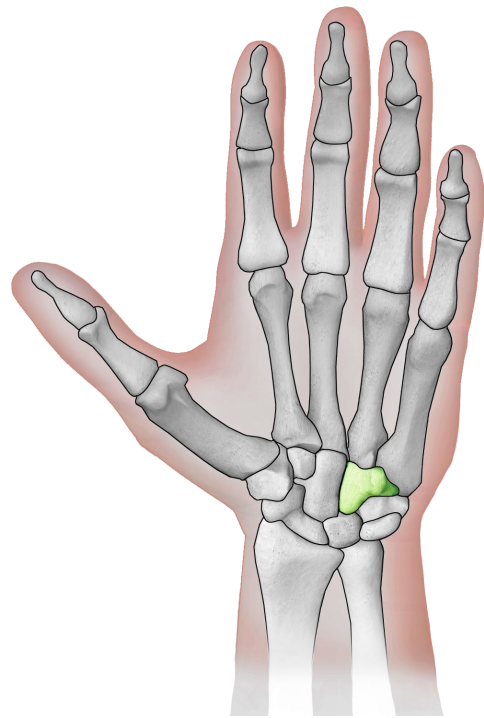
capitate



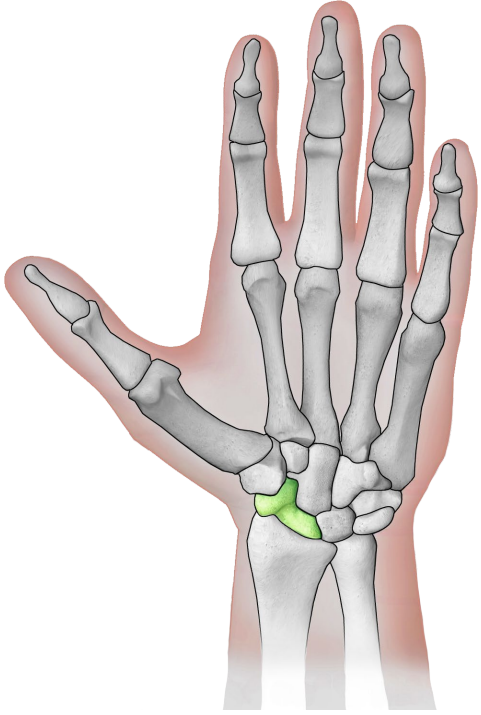
capitate



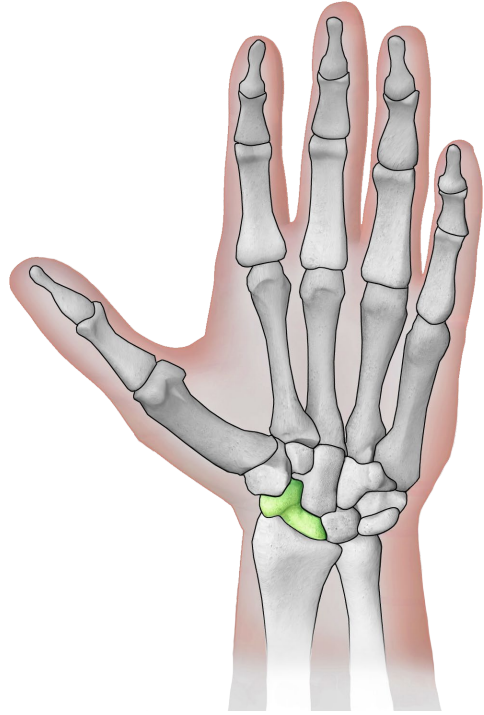
hamate



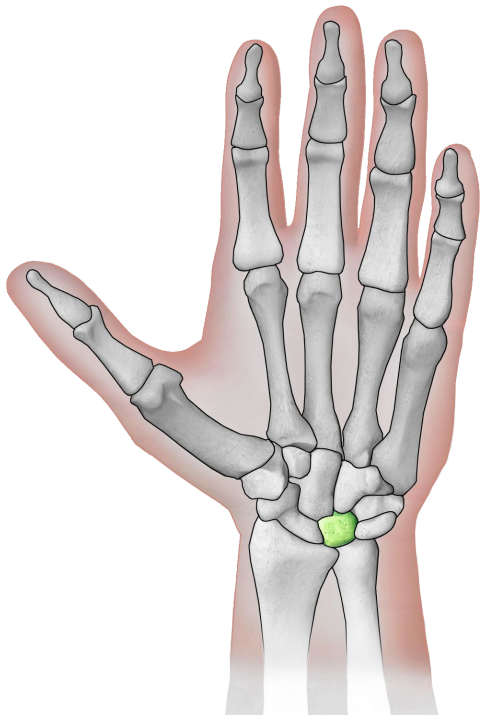
hamate



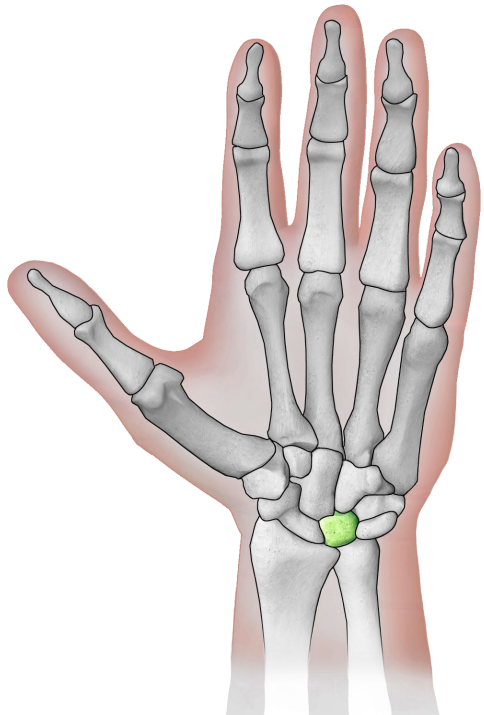
scaphoid



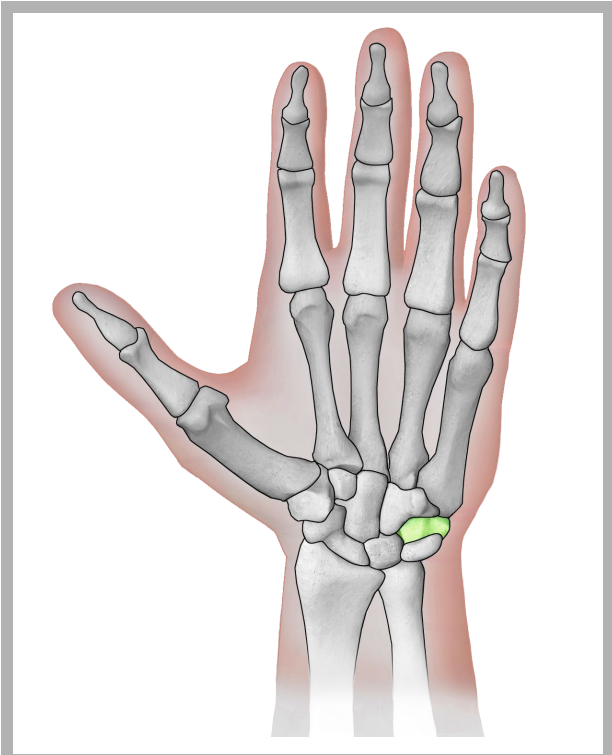
scaphoid



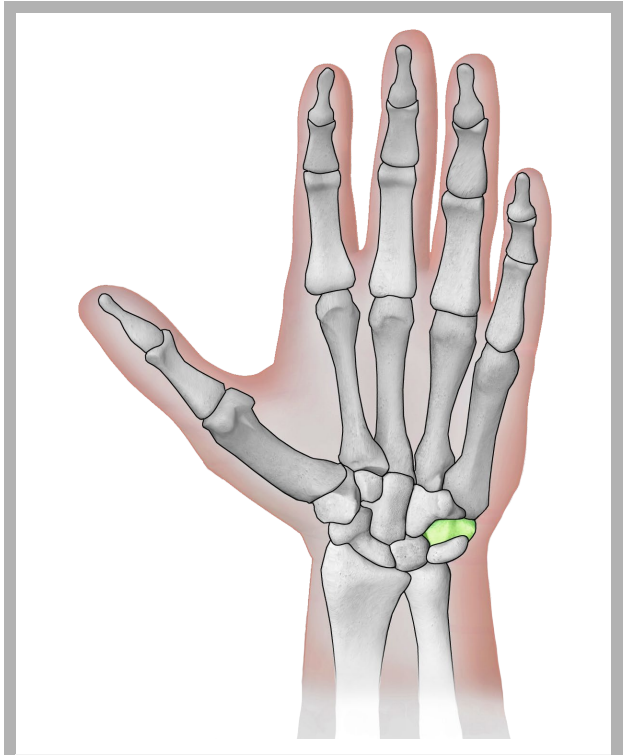
lunate



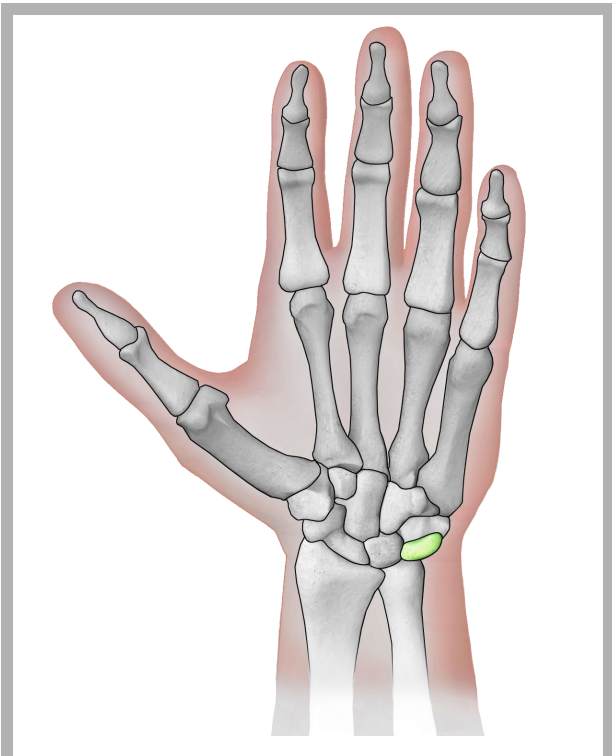
lunate



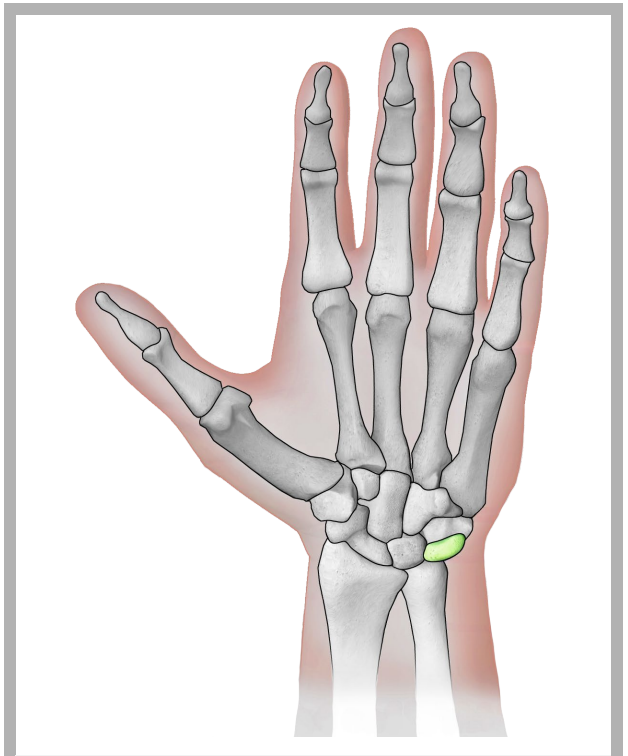pisiform



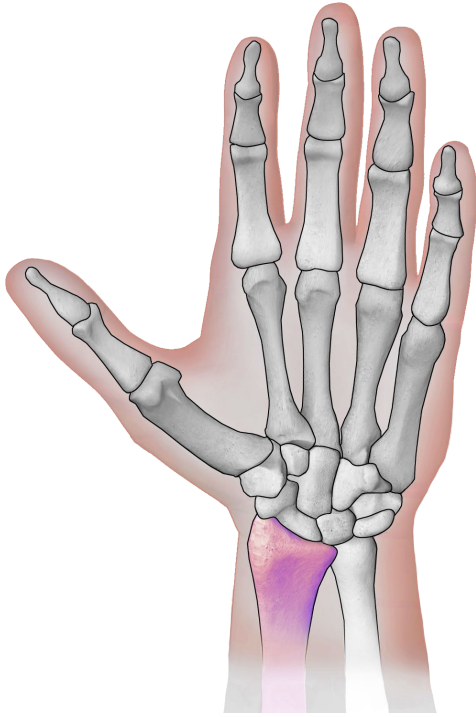
pisiform



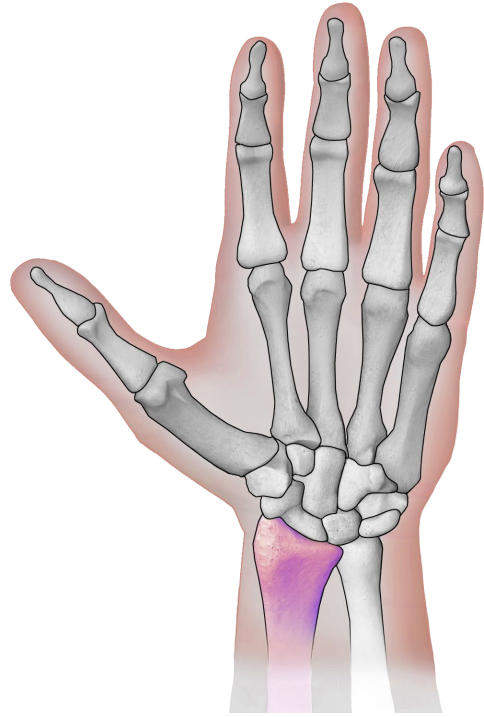
triquetral



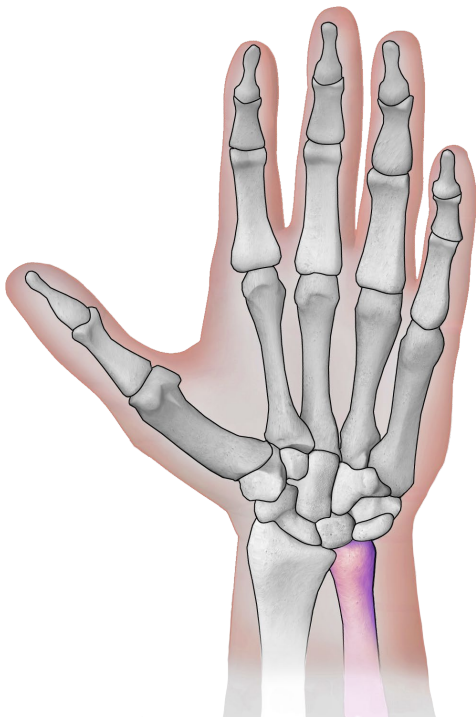
triquetral



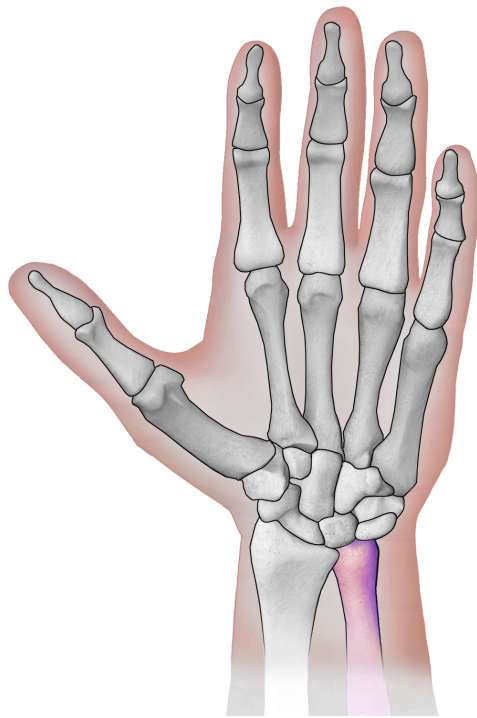
radius



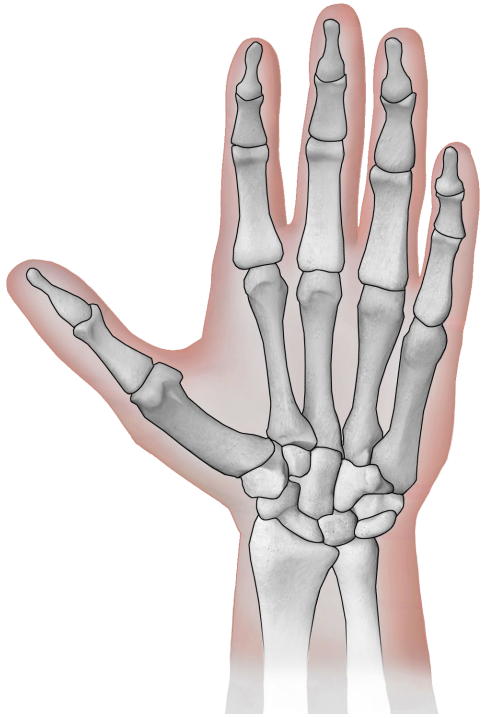
radius



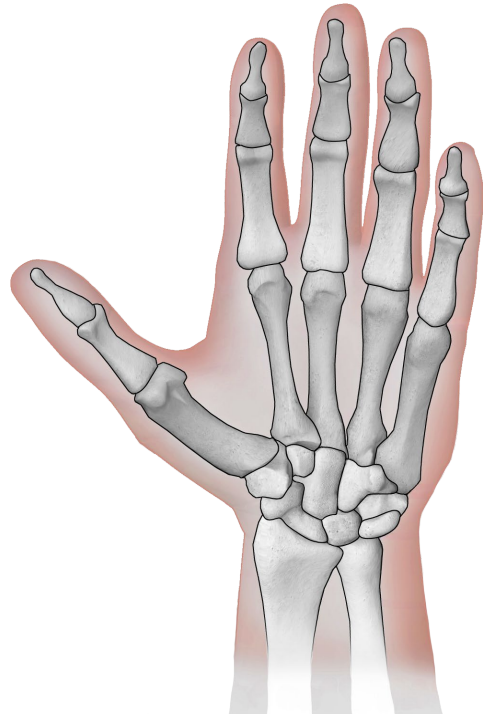
ulna



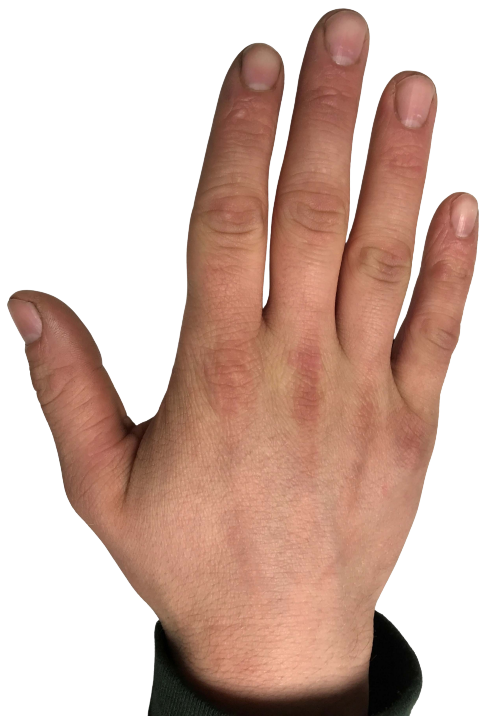ulna



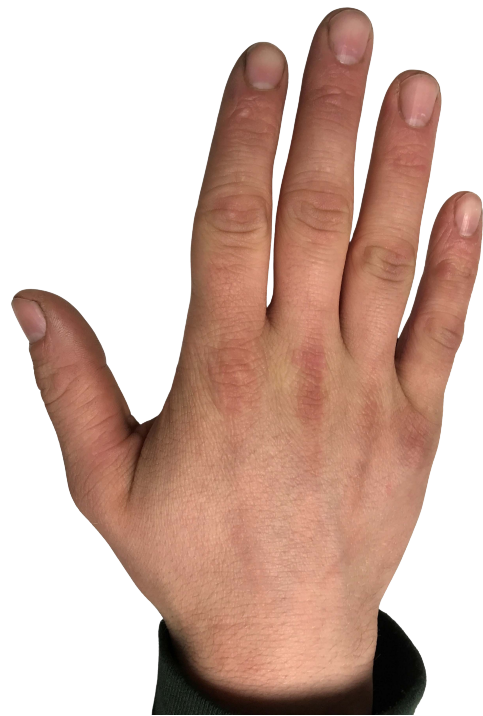hand with bone
(black/white)



hand with bone
(black/white)



hand of a teenager



hand of a teenager

Quellen

[BruceBlaus](#). When using this image in external sources it can be cited as:
Blausen.com staff (2014). "[Medical gallery of Blausen Medical 2014](#)". WikiJournal of
Medicine 1 (2). DOI:[10.15347/wjm/2014.010](#). ISSN [2002-4436](#)., [Blausen 0440](#)
[HandBones](#), Hand schwarz/weiß eingefärbt, einzelne anatomische Teile farbig drauf
gelegt., [CC BY 3.0](#)

[Eyefive45](#), [Hand of a Teenage Boy](#), Bild gedreht und Hintergrund entfernt, [CC BY-SA 4.0](#)