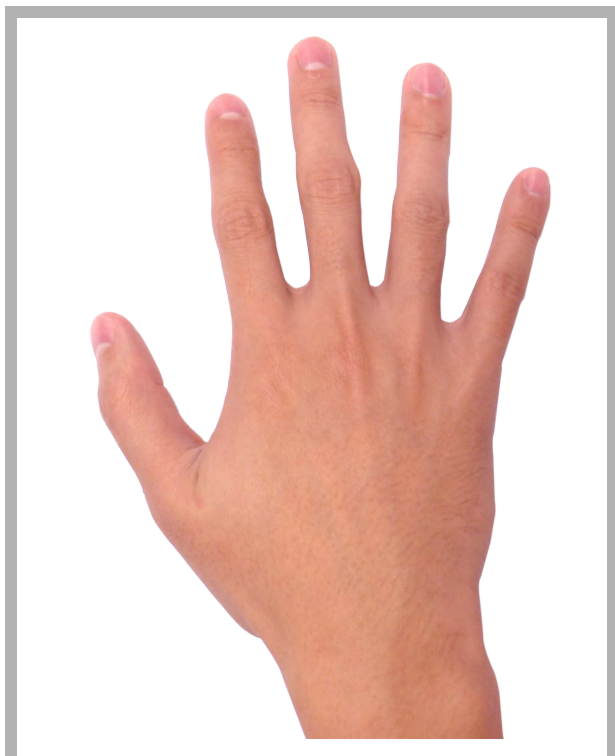
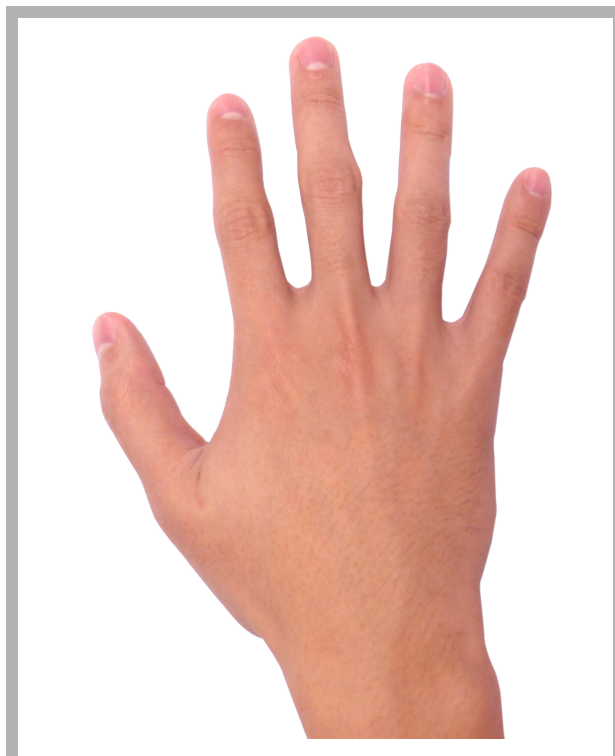
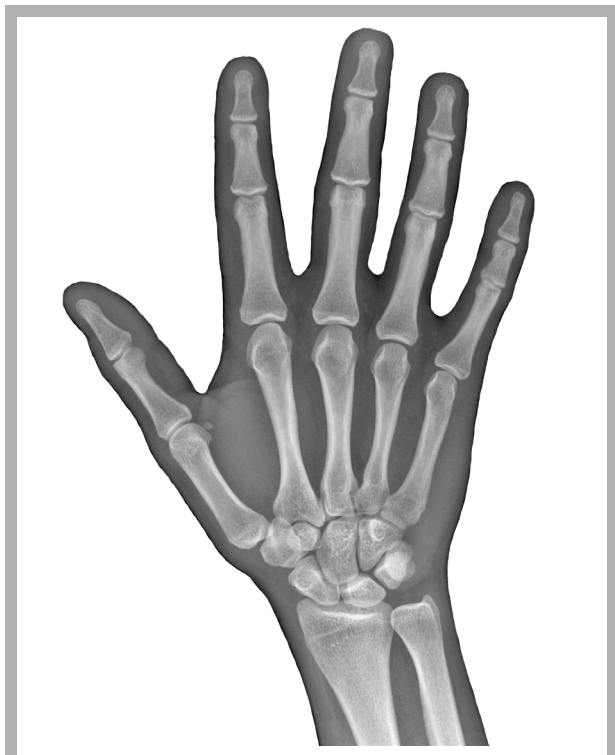

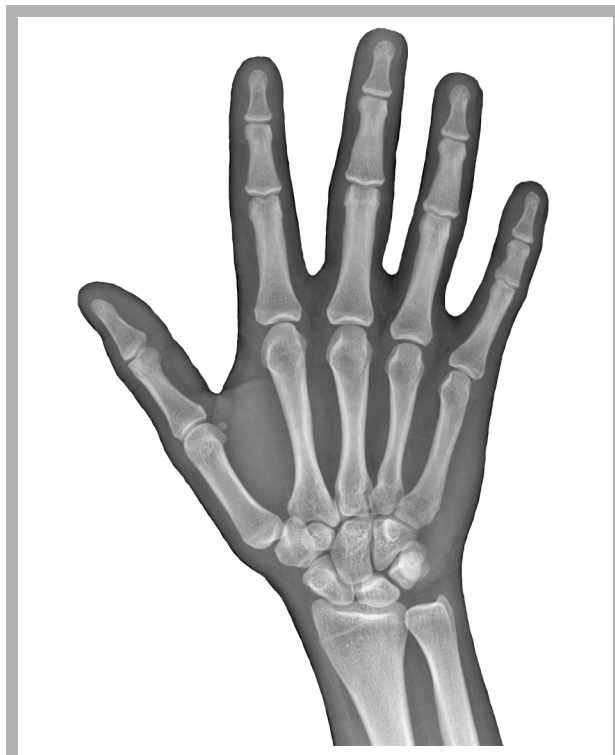mano umana



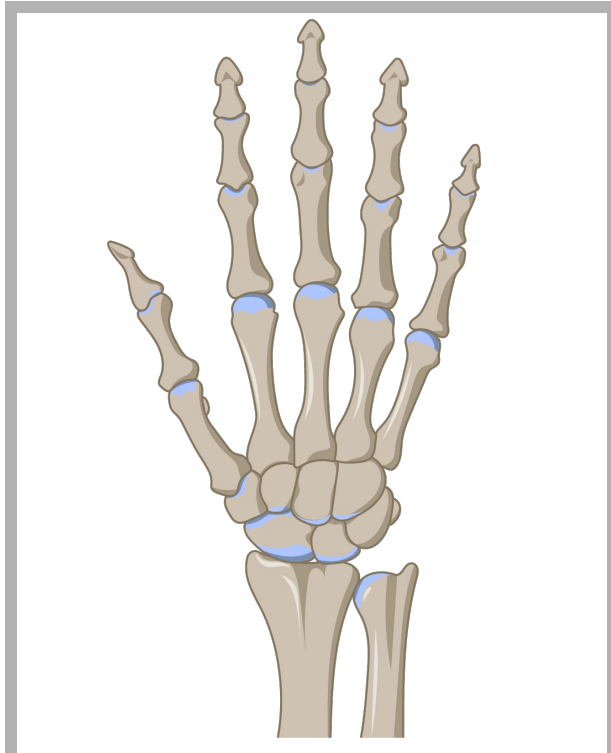
mano umana



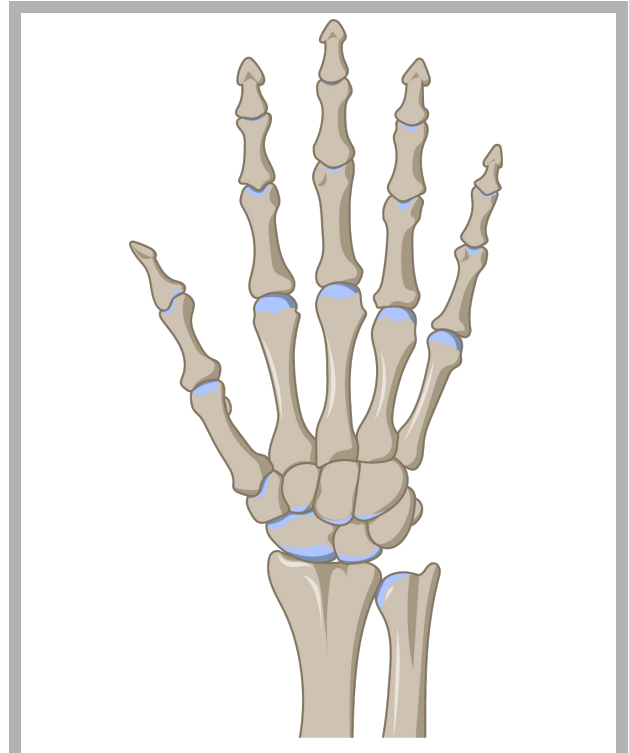
radiografia della  
mano destra



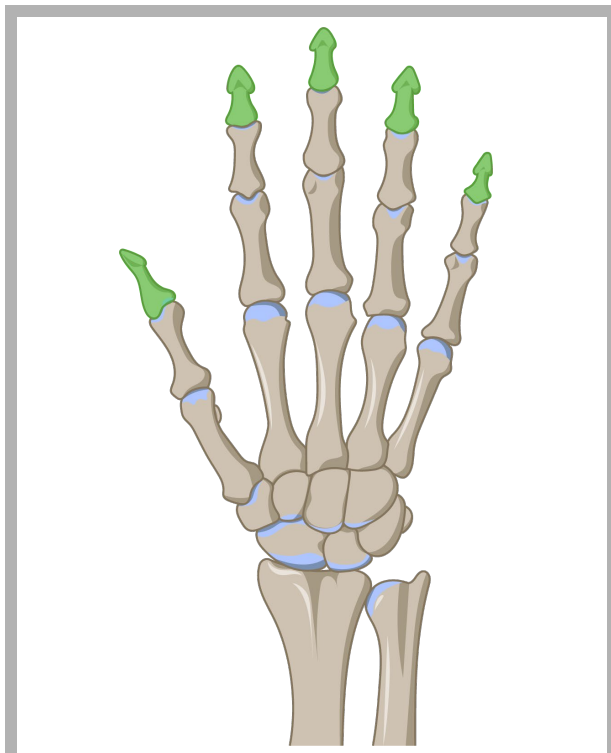
radiografia della  
mano destra



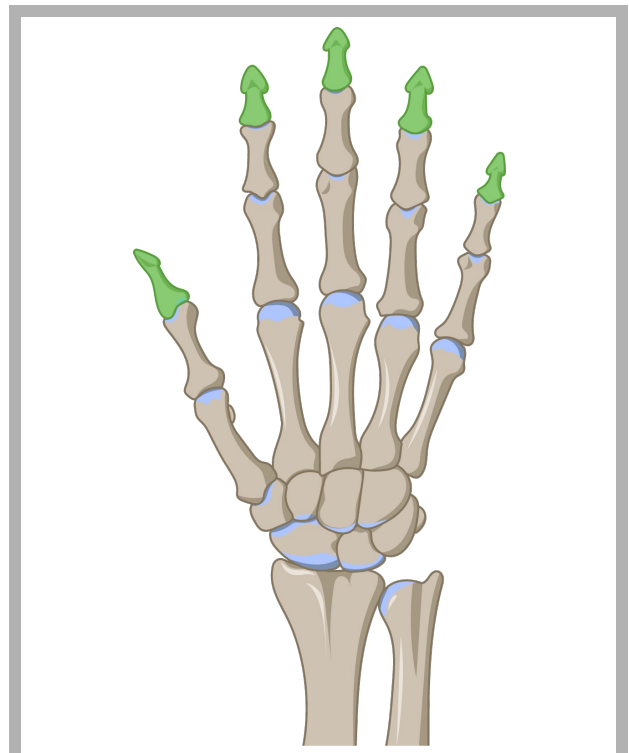
ossa della mano



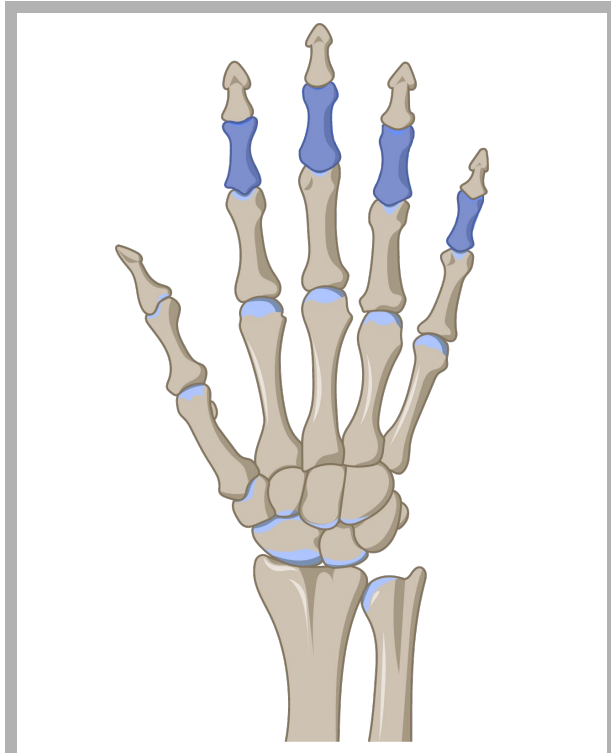
ossa della mano



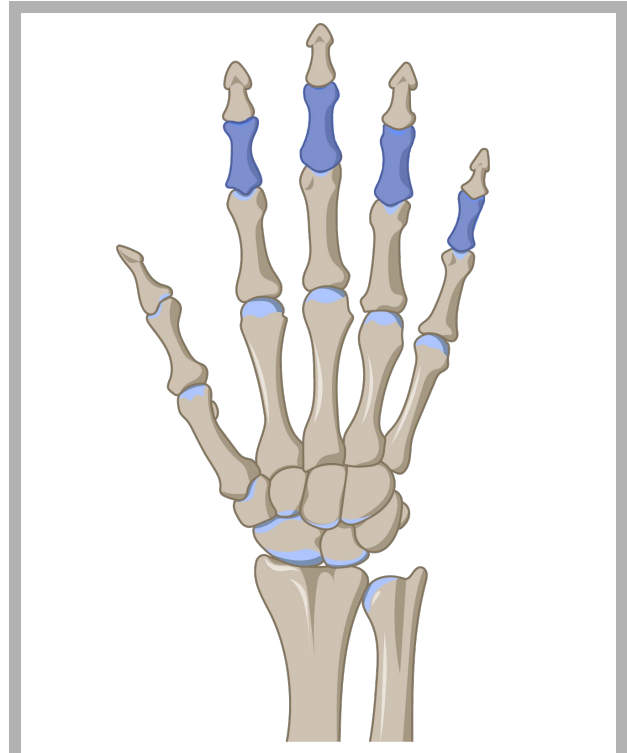
falangi distali



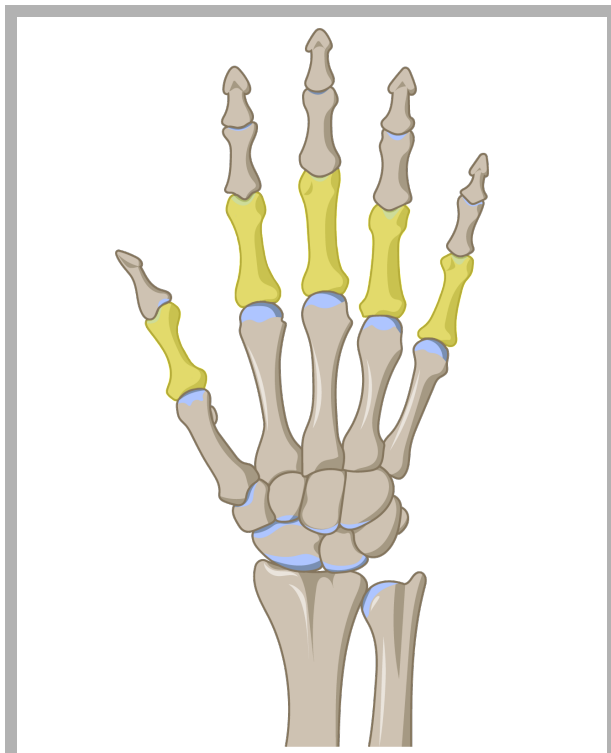
falangi distali



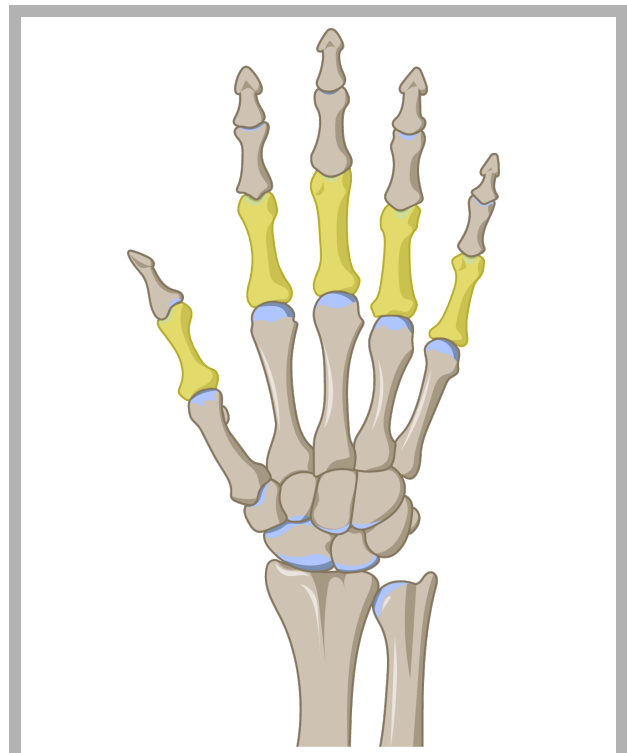
falangi intermedie



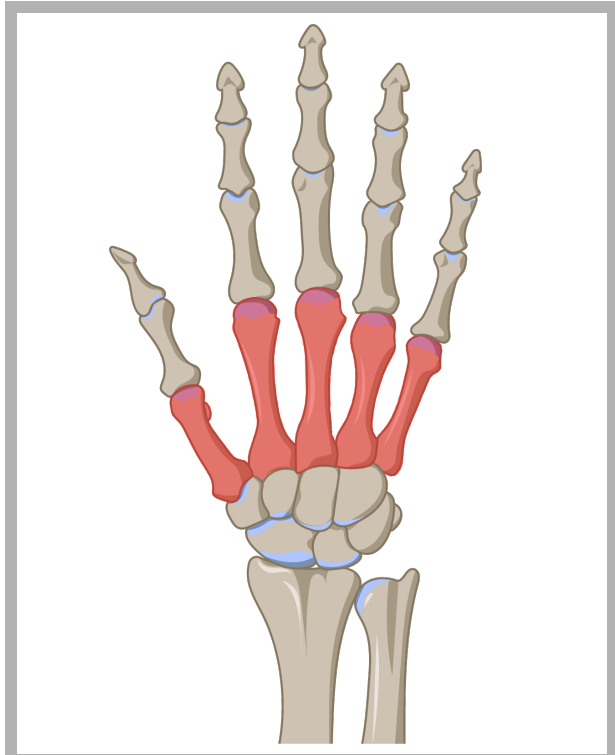
falangi intermedie



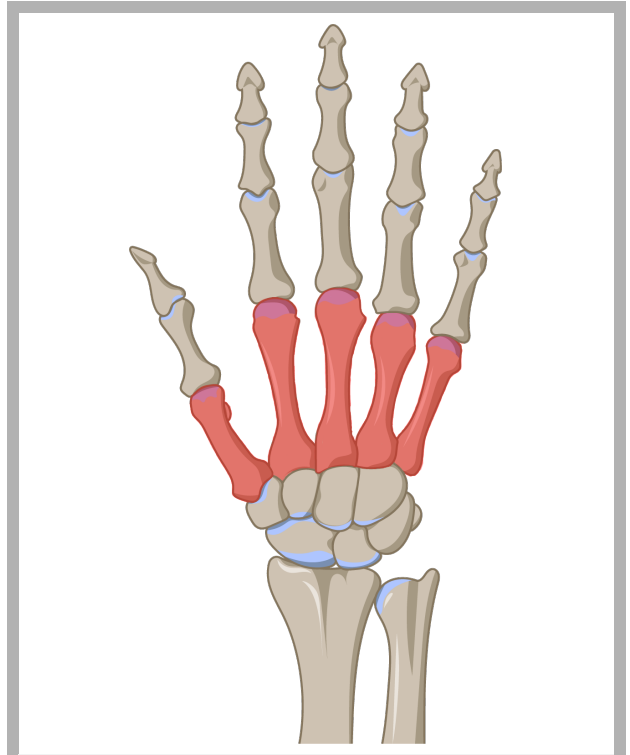
falangi prossimali



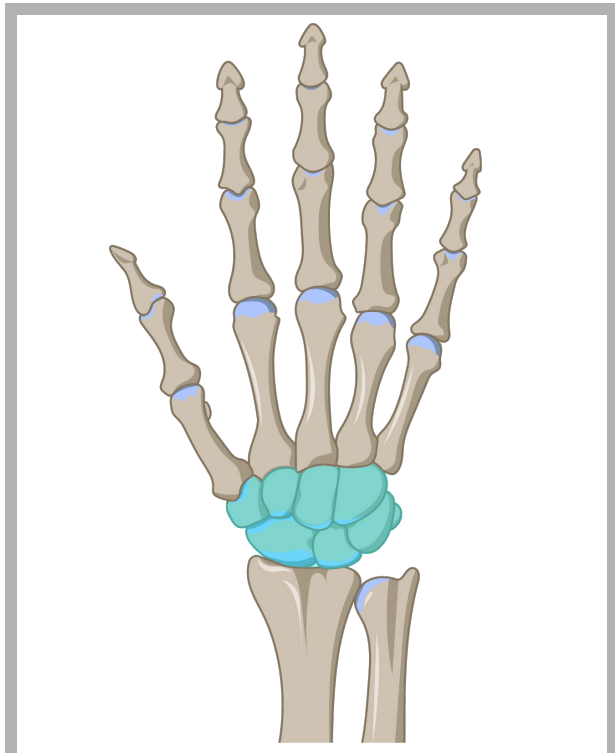
falangi prossimali



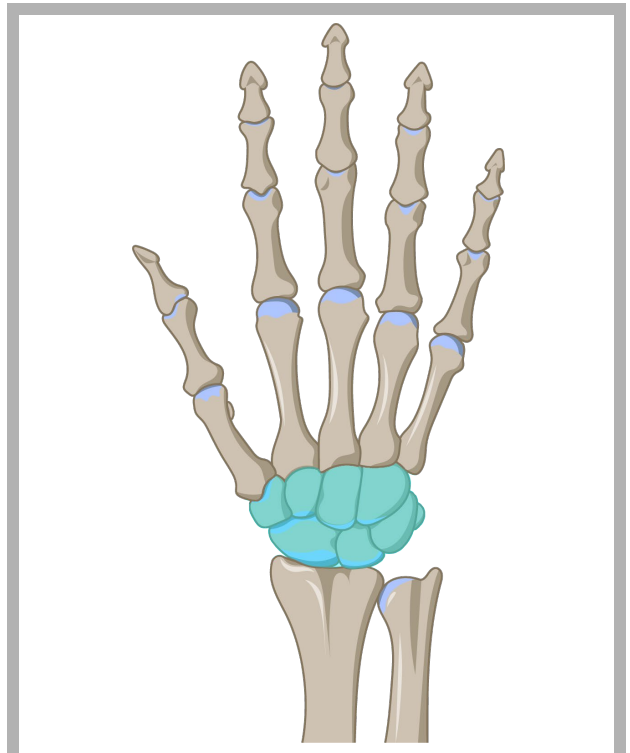
metacarpi



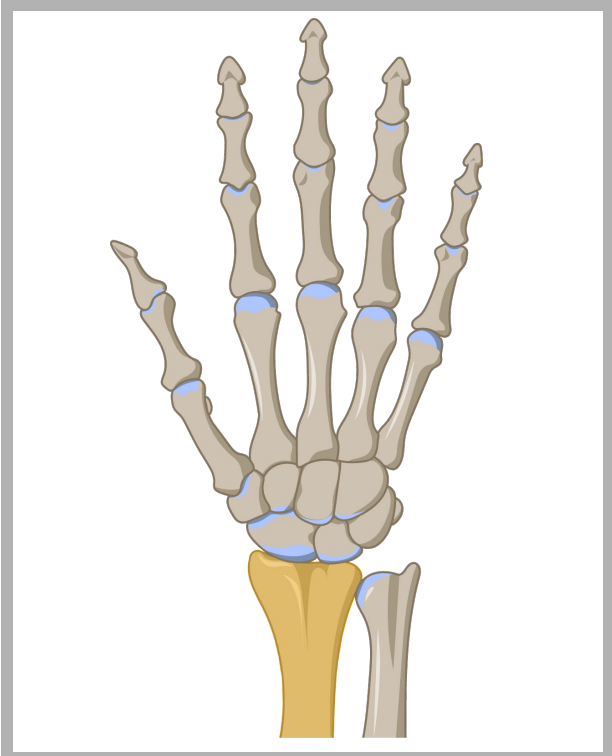
metacarpi



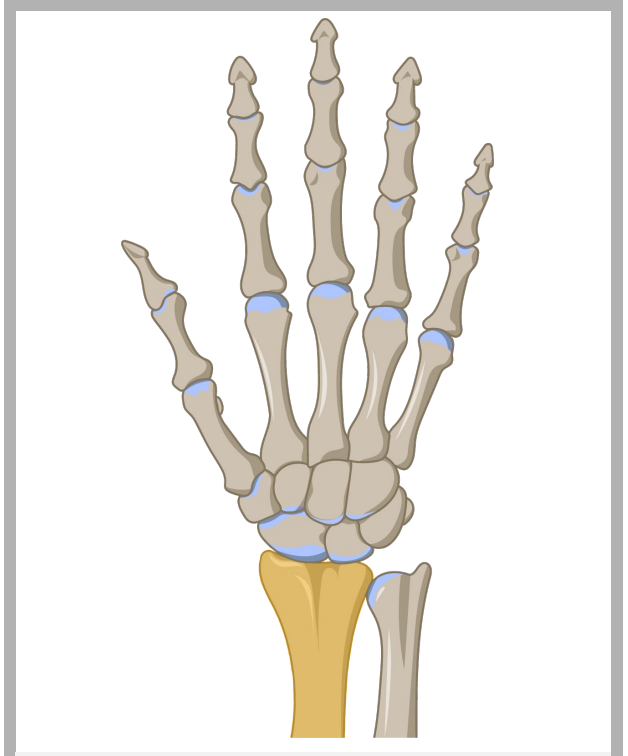
carpali



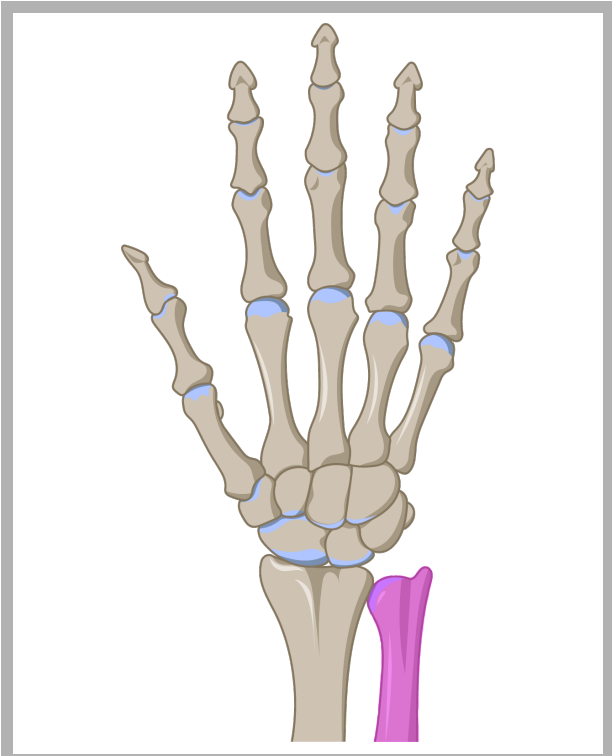
carpali



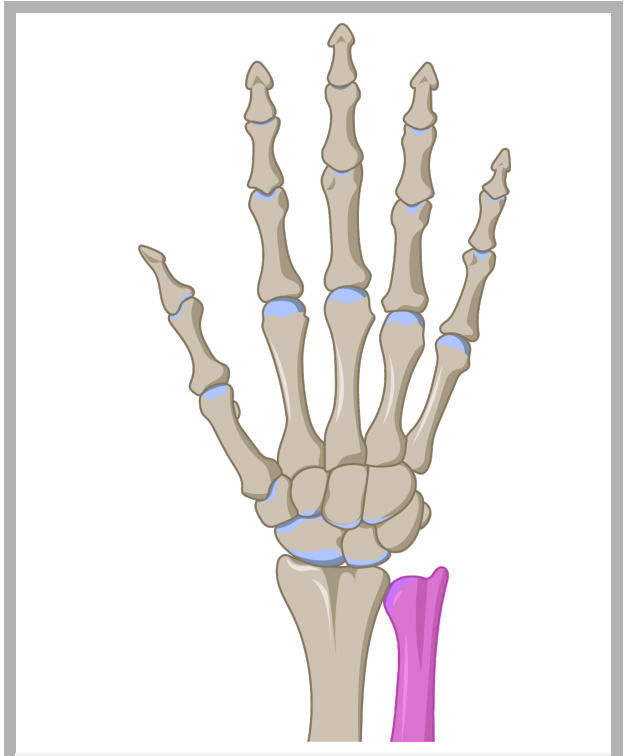
radio



radio



ulna (cubito)



ulna (cubito)

## Quellen

[Hand on flat surface Kostenloser Foto-Download | FreImages](#)

© Nevit Dilmen, [Medical X-Ray imaging EGA04 nevit](#), Hand freigestellt, [CC BY-SA 3.0](#)

DataBase Center for Life Science (DBCLS), [202110 Posterior view of bones of right hand](#), Einzelne anatomische Elemente farbig angemalt, [CC BY 4.0](#)