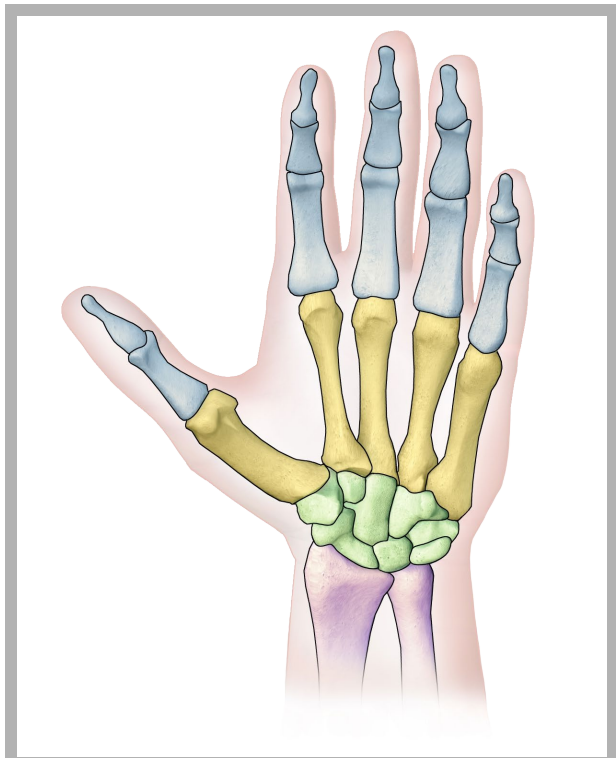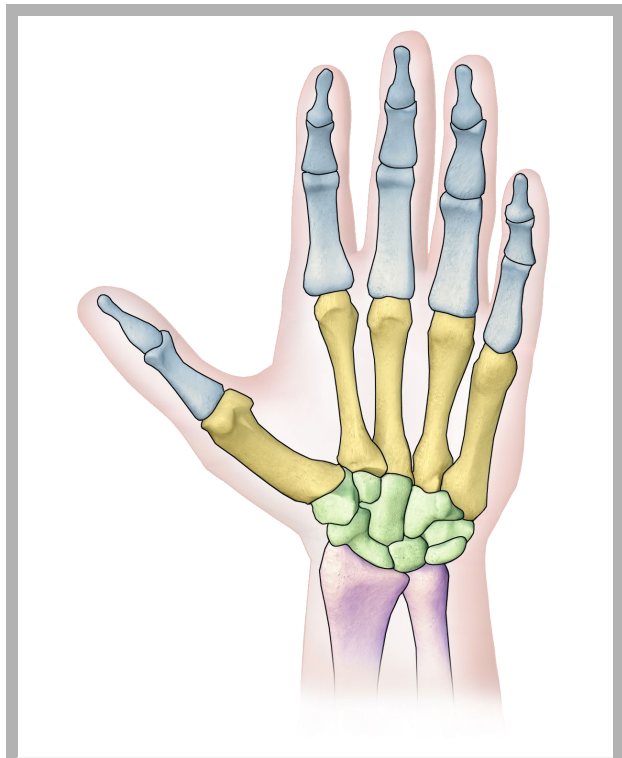
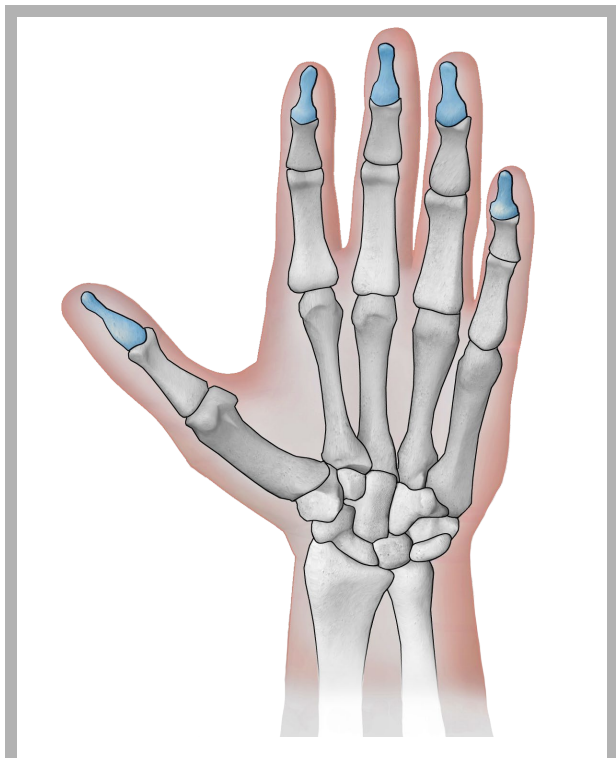


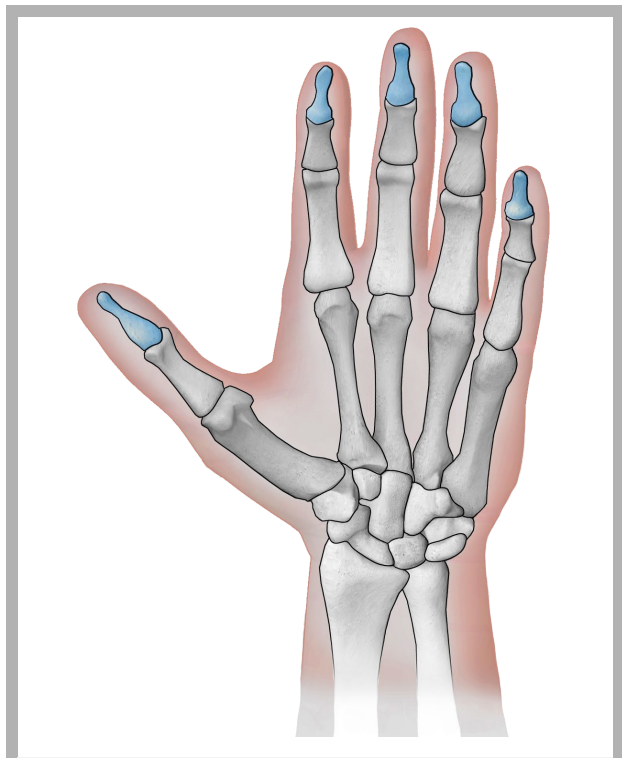
ossa della mano



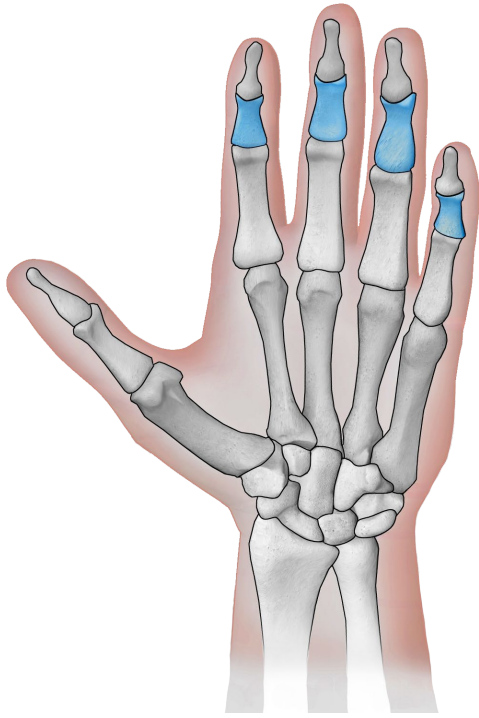
ossa della mano



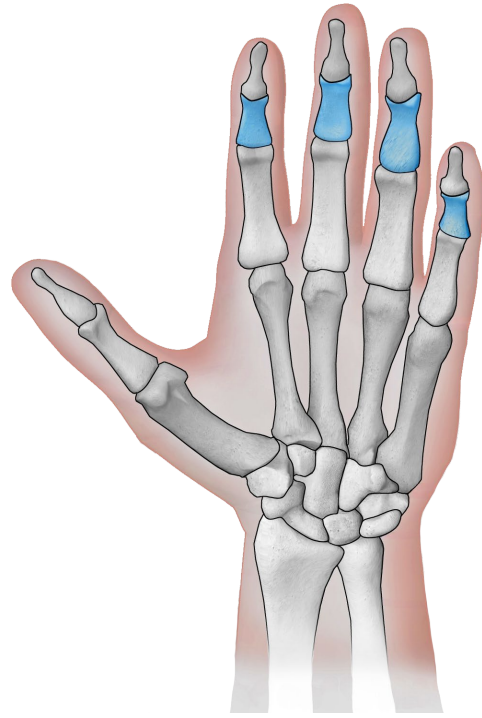
falangi distali



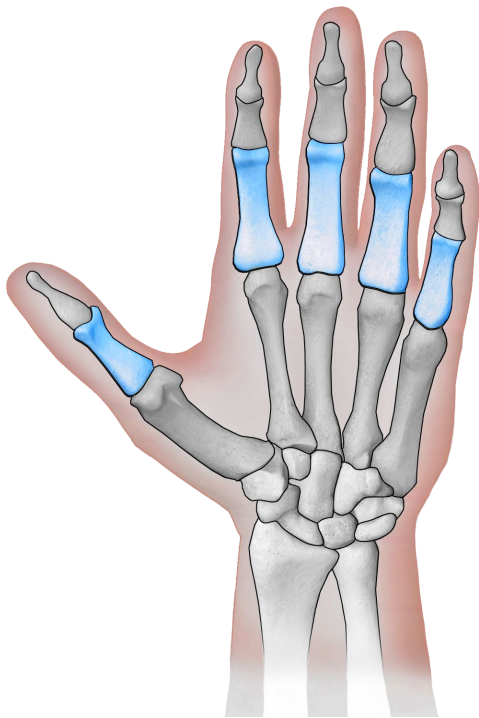
falangi distali



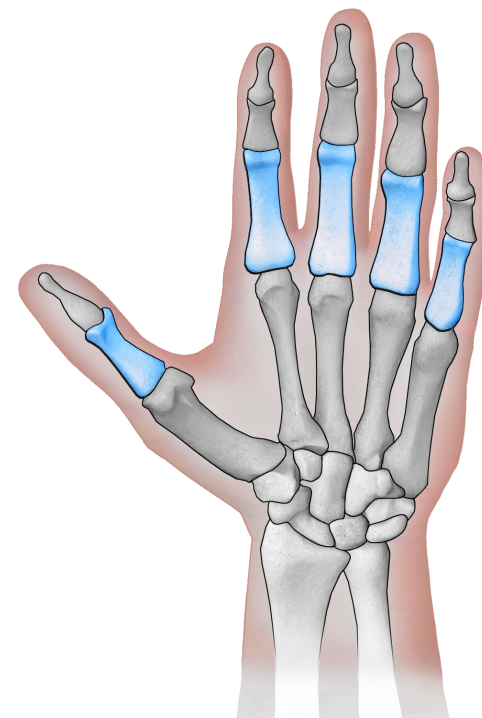
falangi intermedie



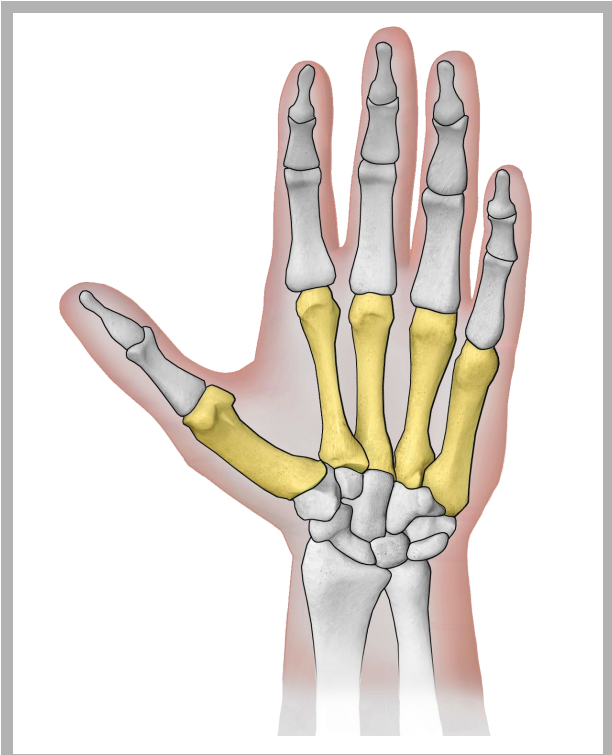
falangi intermedie



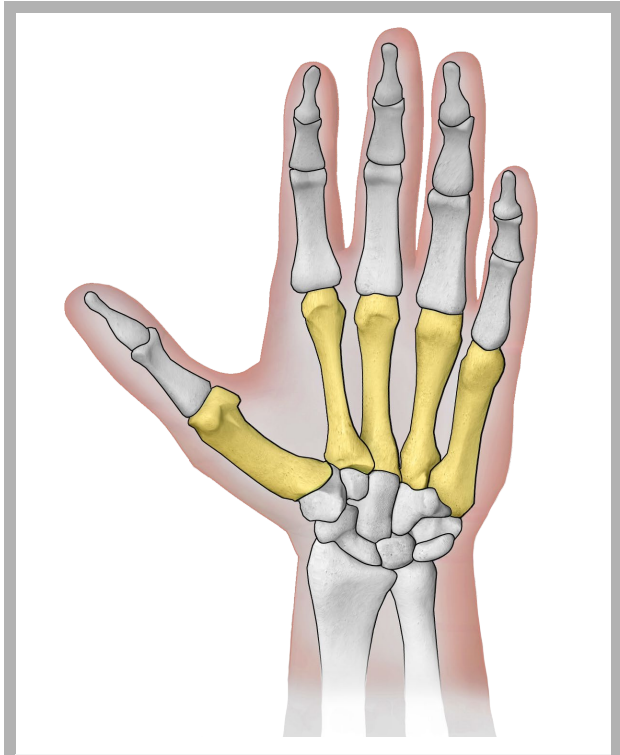
falangi prossimali



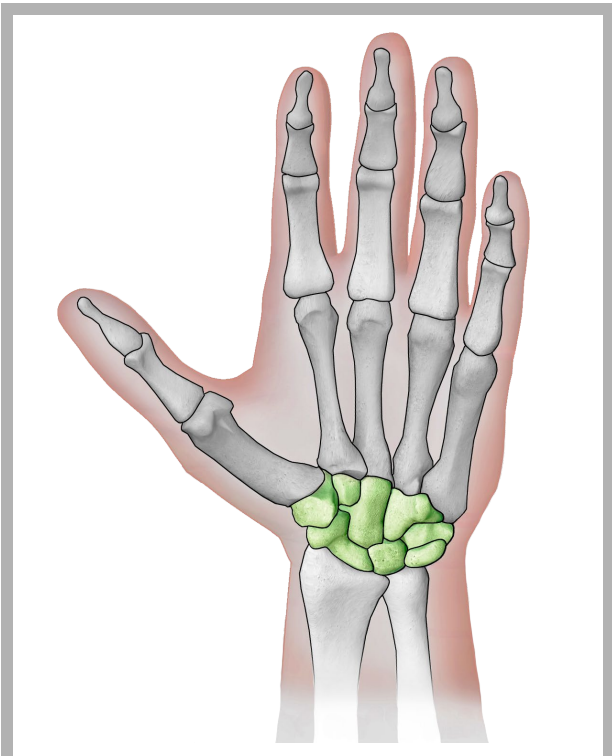
falangi prossimali



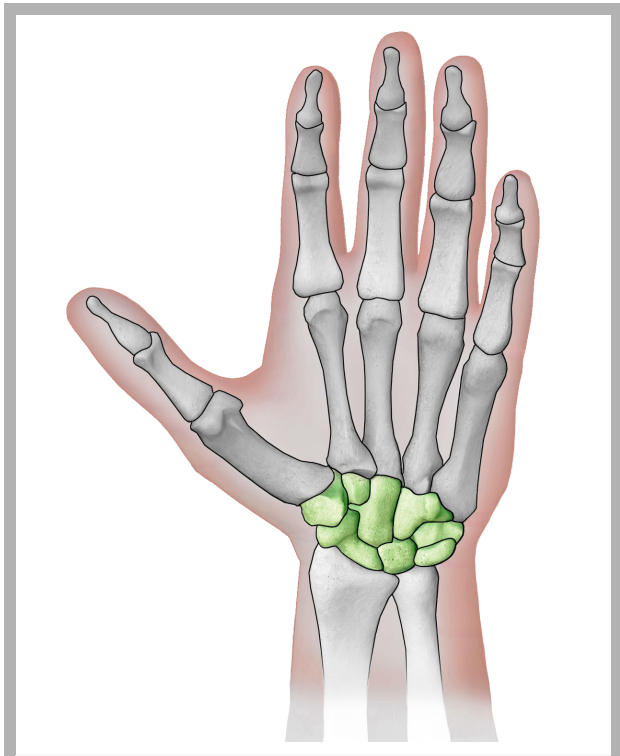
metacarpi



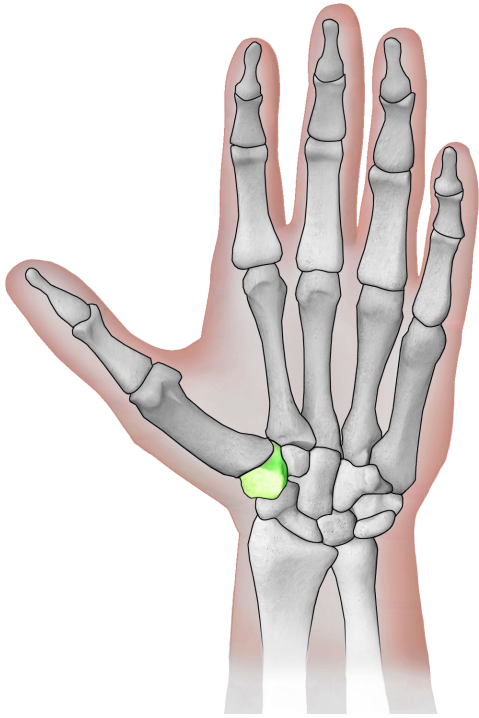
metacarpi



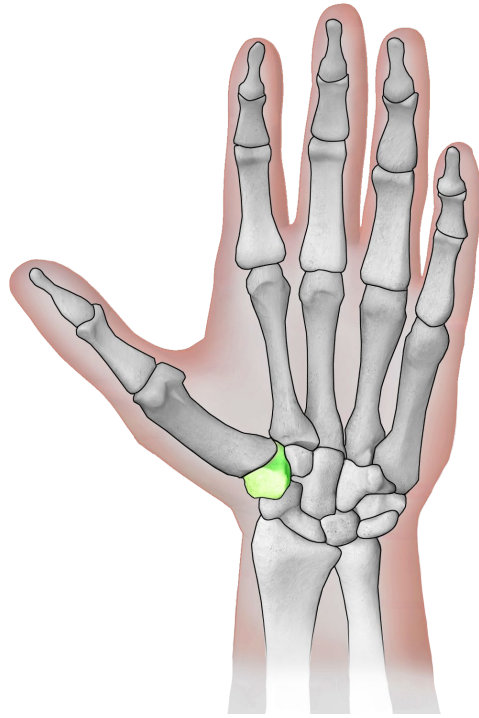
carpali



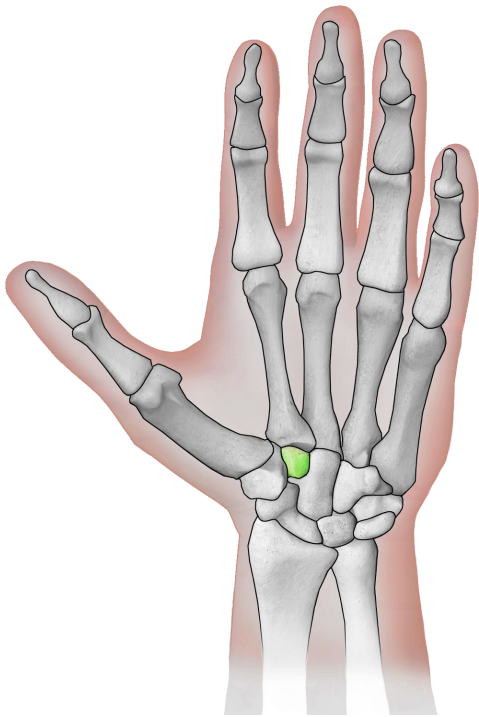
carpali



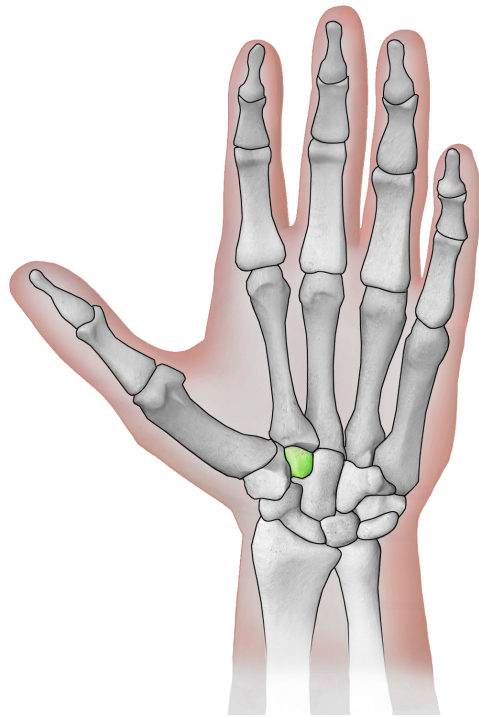
osso trapezio



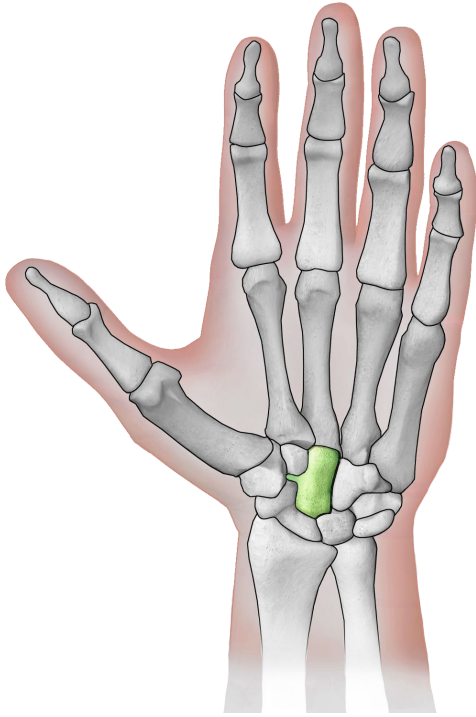
osso trapezio



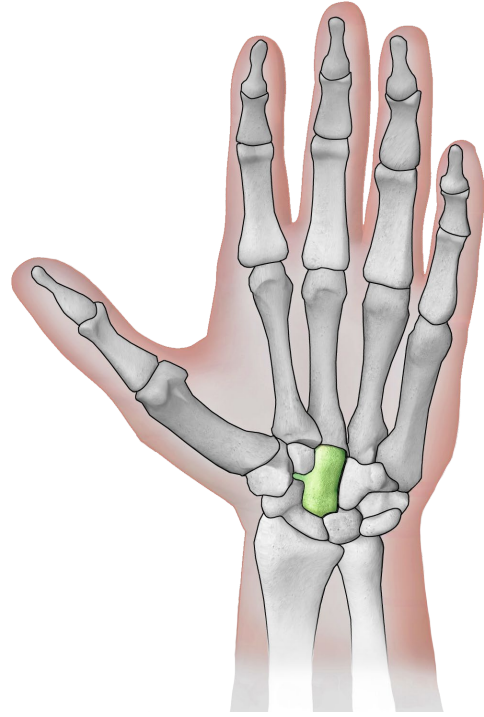
osso trapezoide



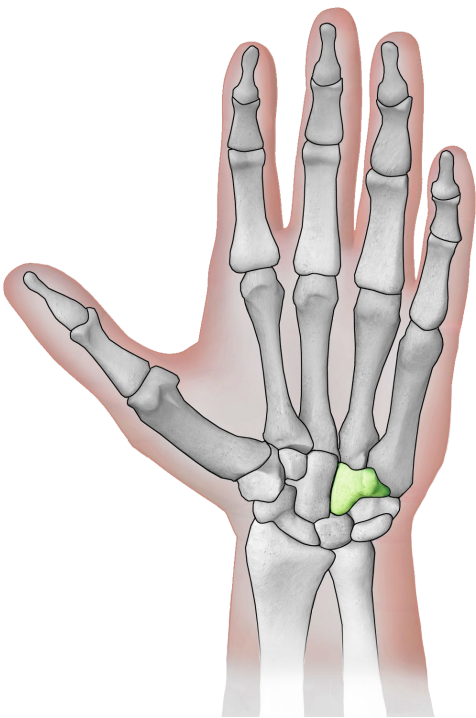
osso trapezoide



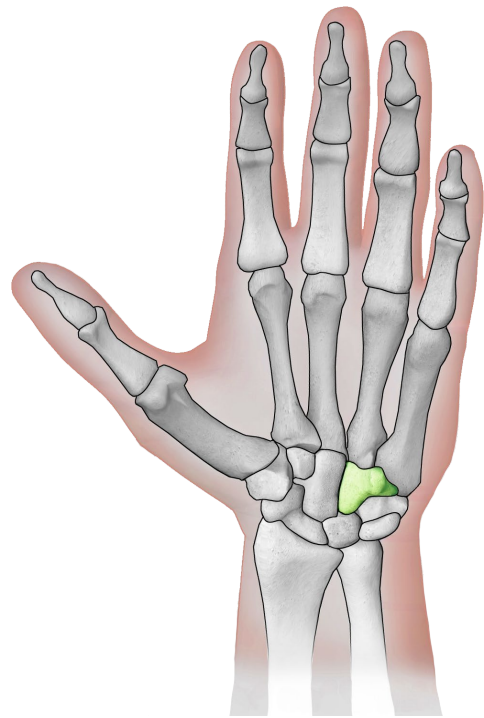
osso capitato



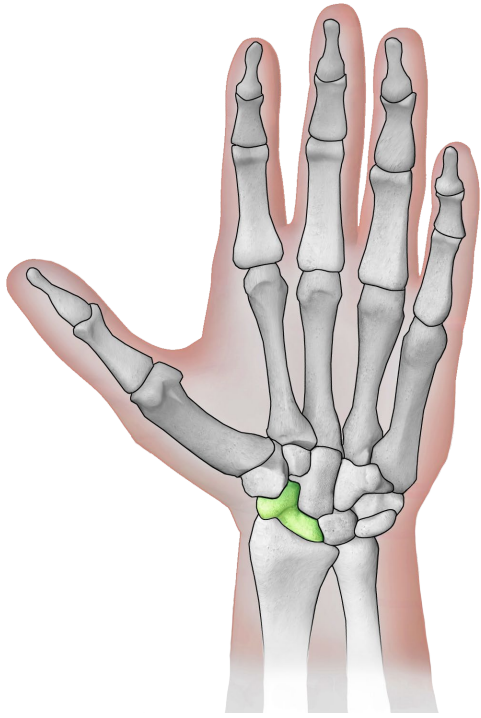
osso capitato



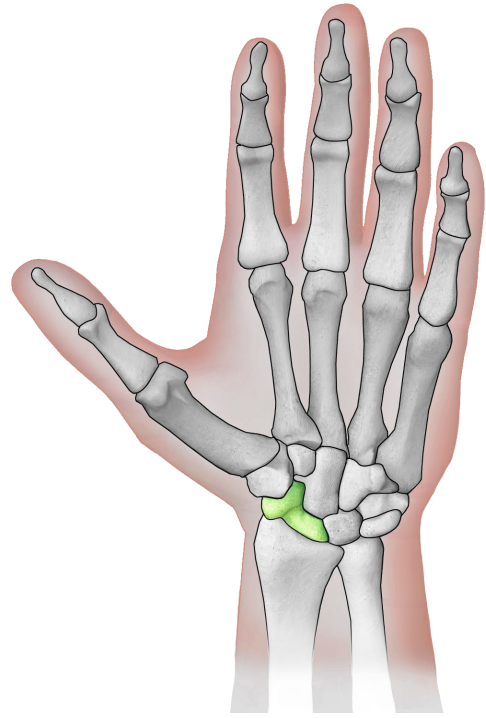
osso uncinato



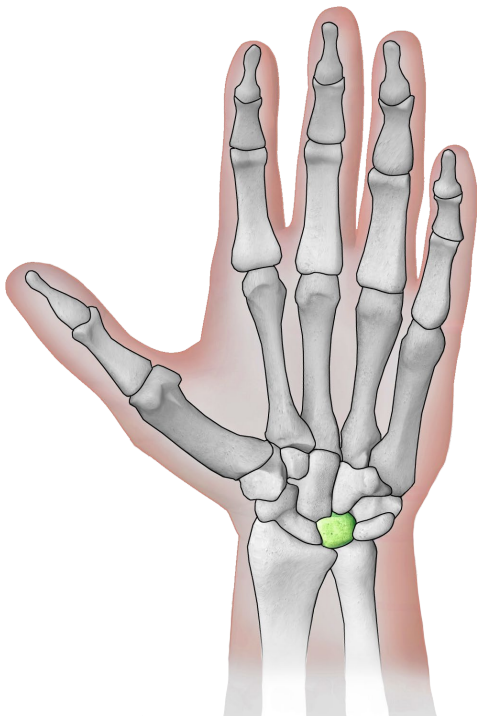
osso uncinato



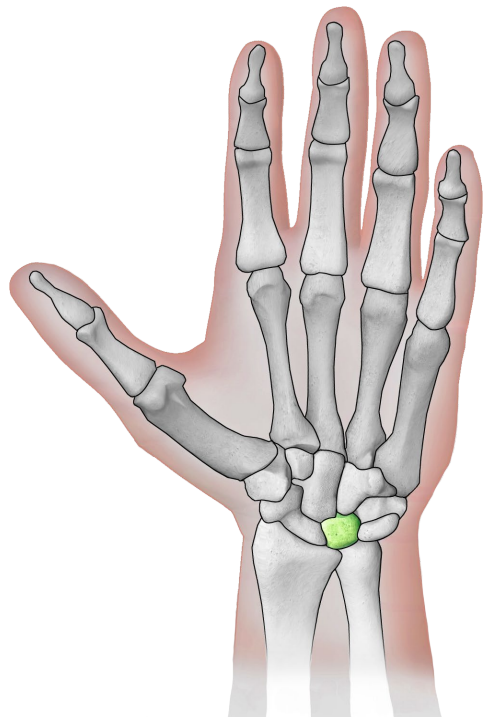
osso scafoide



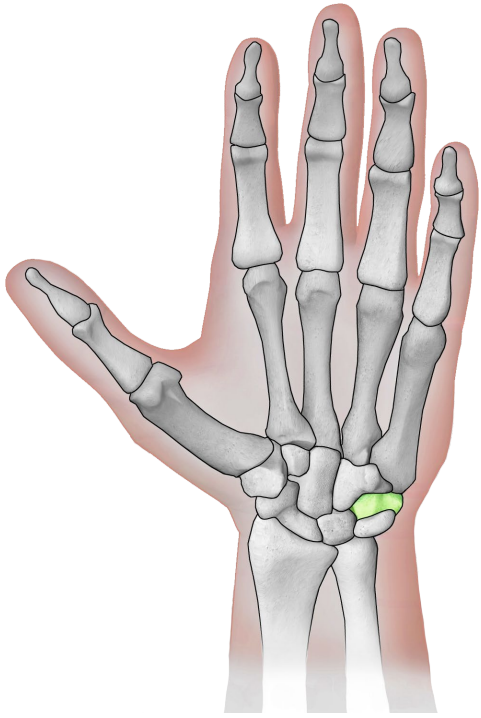
osso scafoide



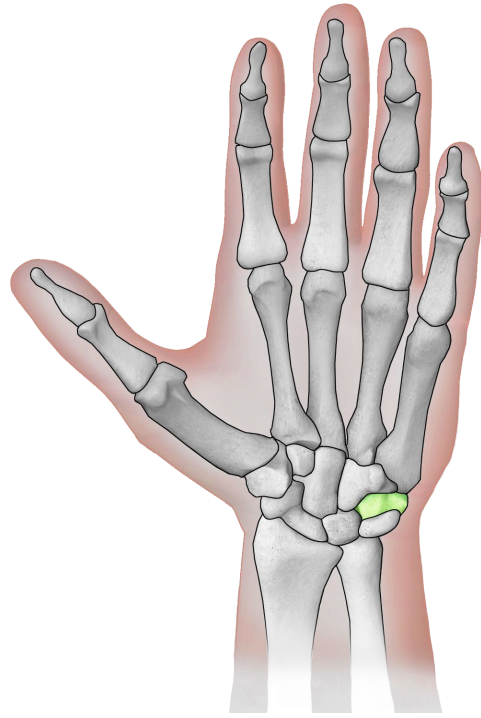
osso semilunare



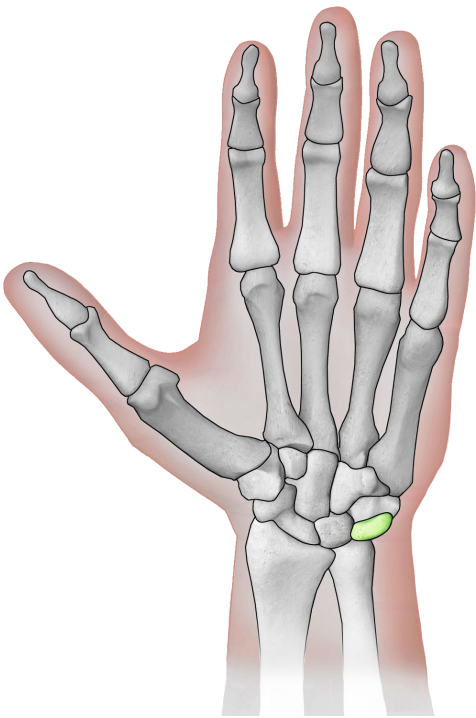
osso semilunare



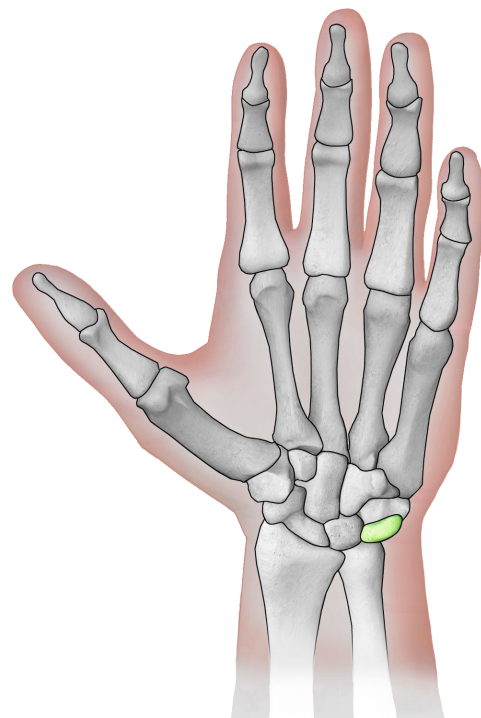
osso pisiforme



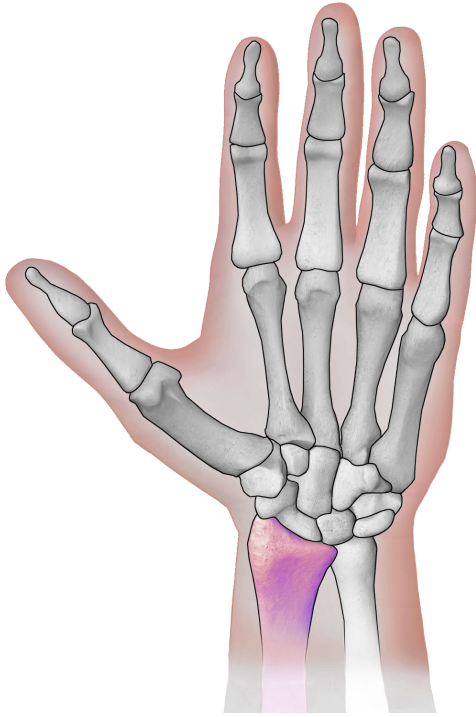
osso pisiforme



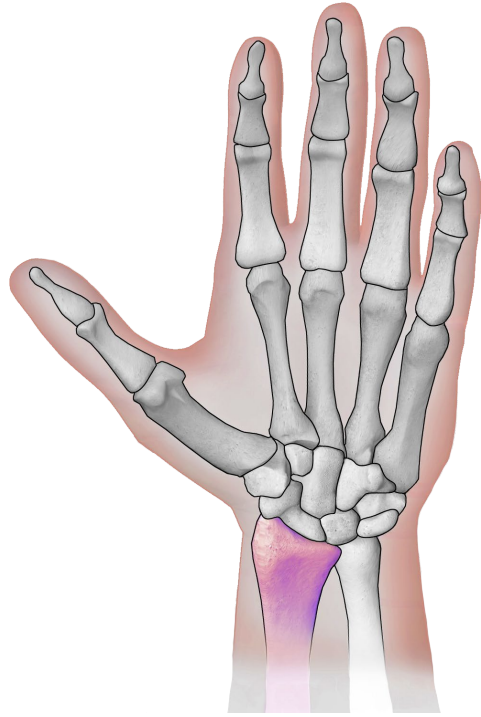
osso piramidale



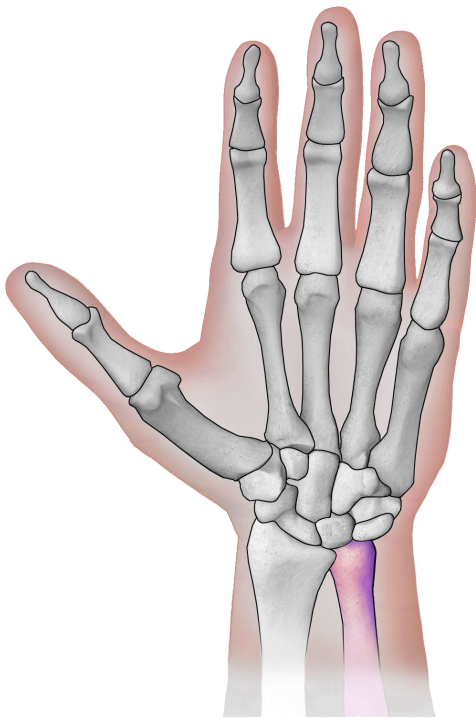
osso piramidale



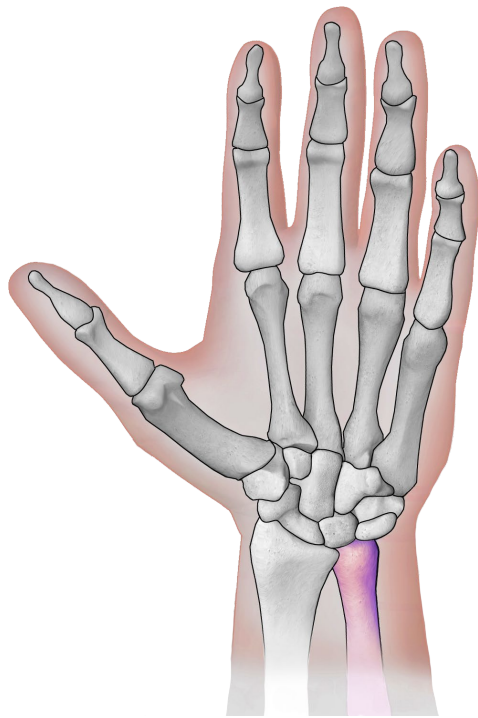
radio



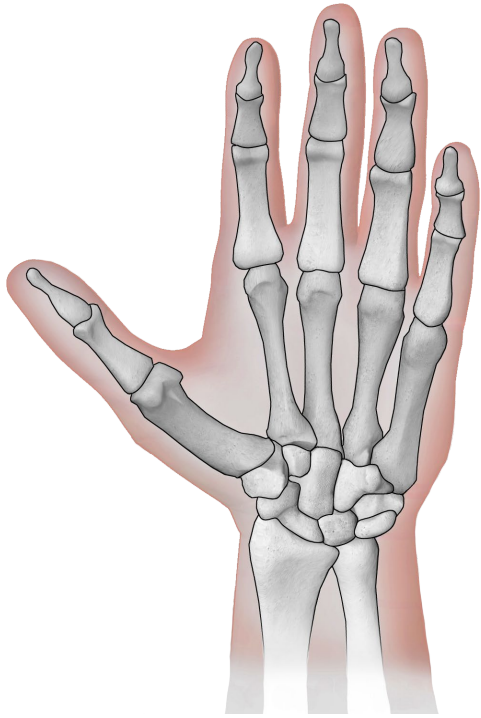
radio



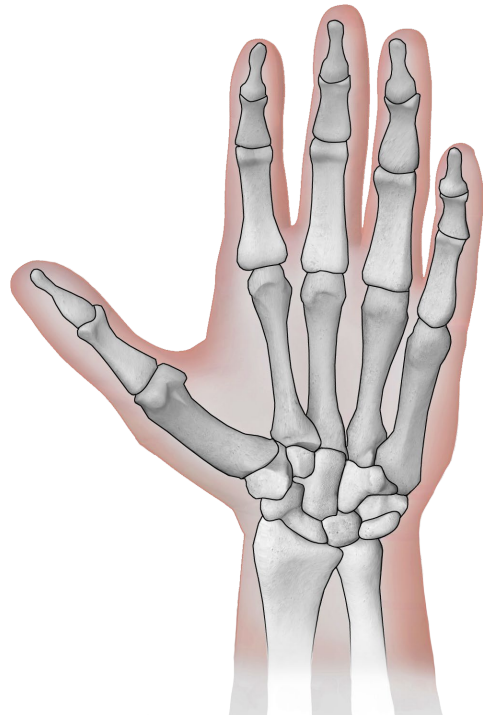
ulna (cubito)



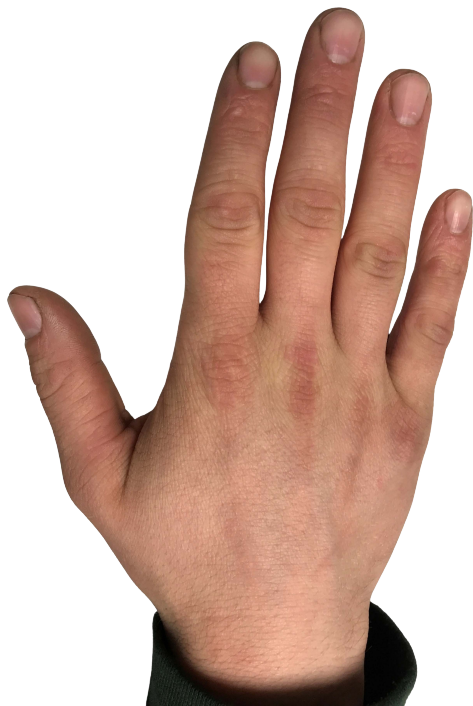ulna (cubito)



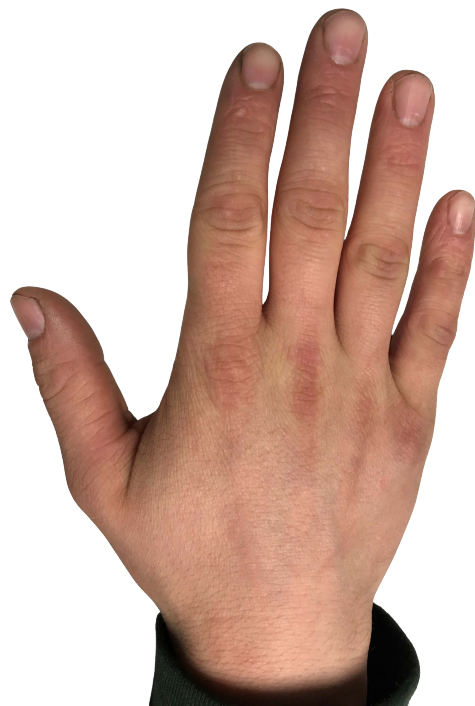mano con osso
(bianco/nero)



mano con osso
(bianco/nero)



mano di un
adolescente



mano di un
adolescente

Quellen

[BruceBlaus](#). When using this image in external sources it can be cited as:
Blausen.com staff (2014). "[Medical gallery of Blausen Medical 2014](#)". WikiJournal of
Medicine 1 (2). DOI:[10.15347/wjm/2014.010](#). ISSN [2002-4436](#)., [Blausen 0440](#)
[HandBones](#), Hand schwarz/weiß eingefärbt, einzelne anatomische Teile farbig drauf
gelegt., [CC BY 3.0](#)

[Eyefive45](#), [Hand of a Teenage Boy](#), Bild gedreht und Hintergrund entfernt, [CC BY-SA 4.0](#)