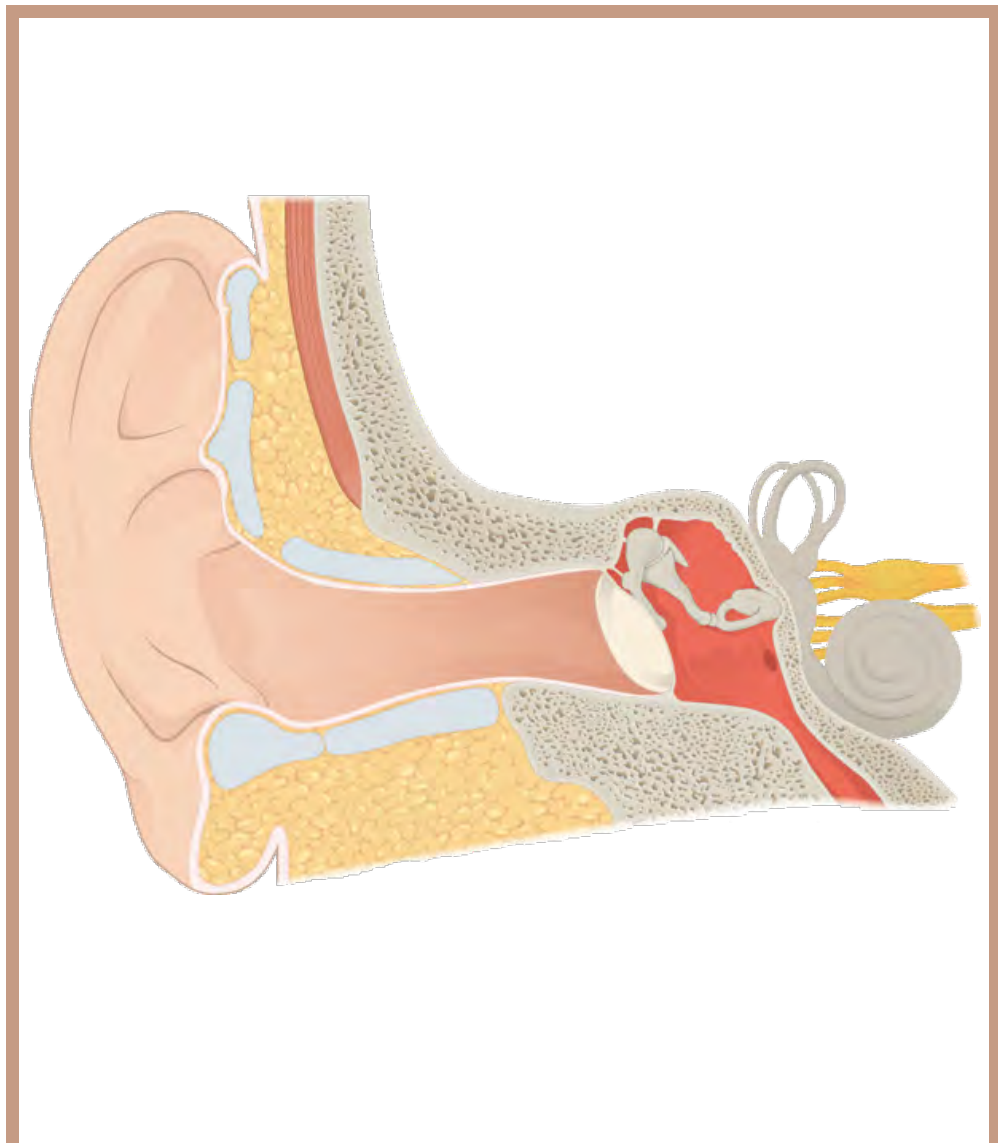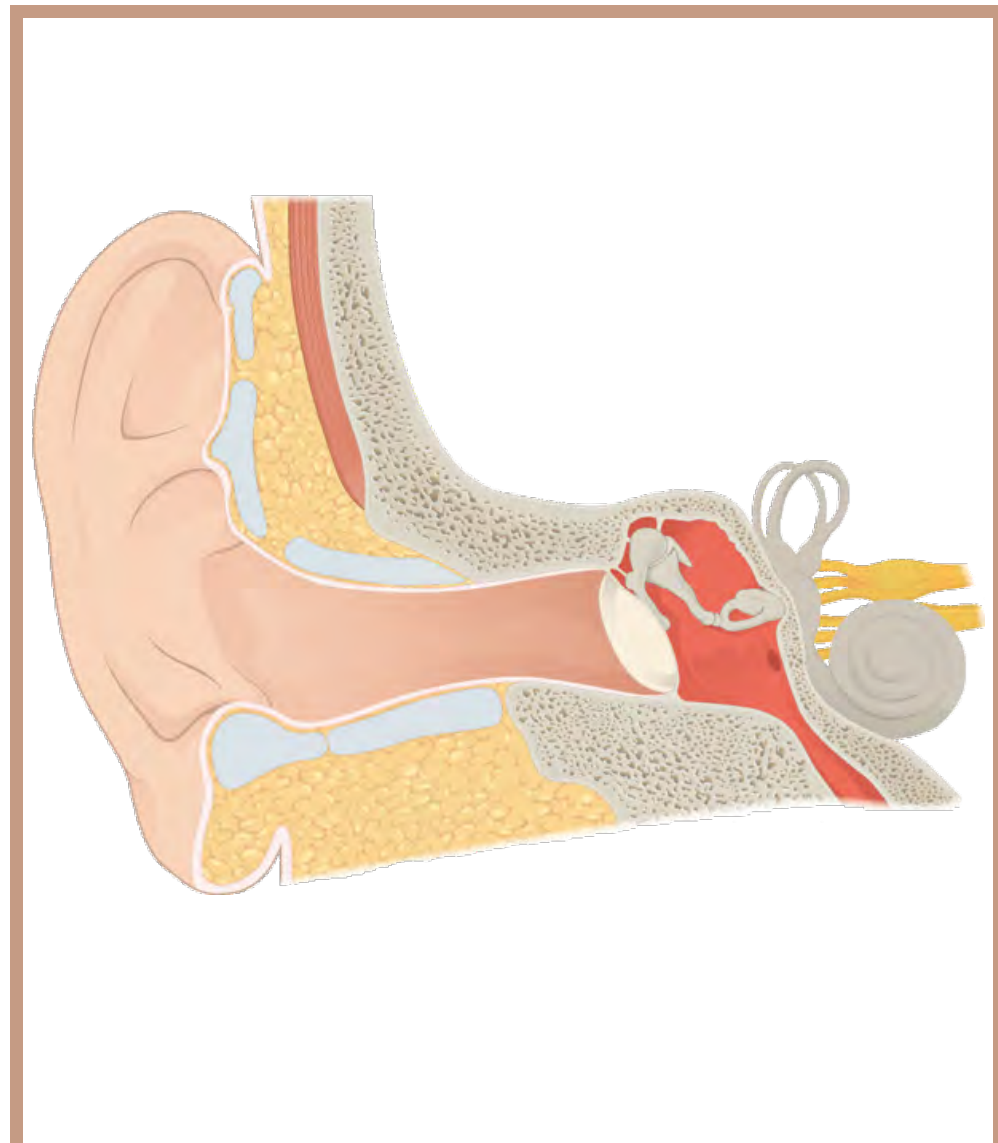
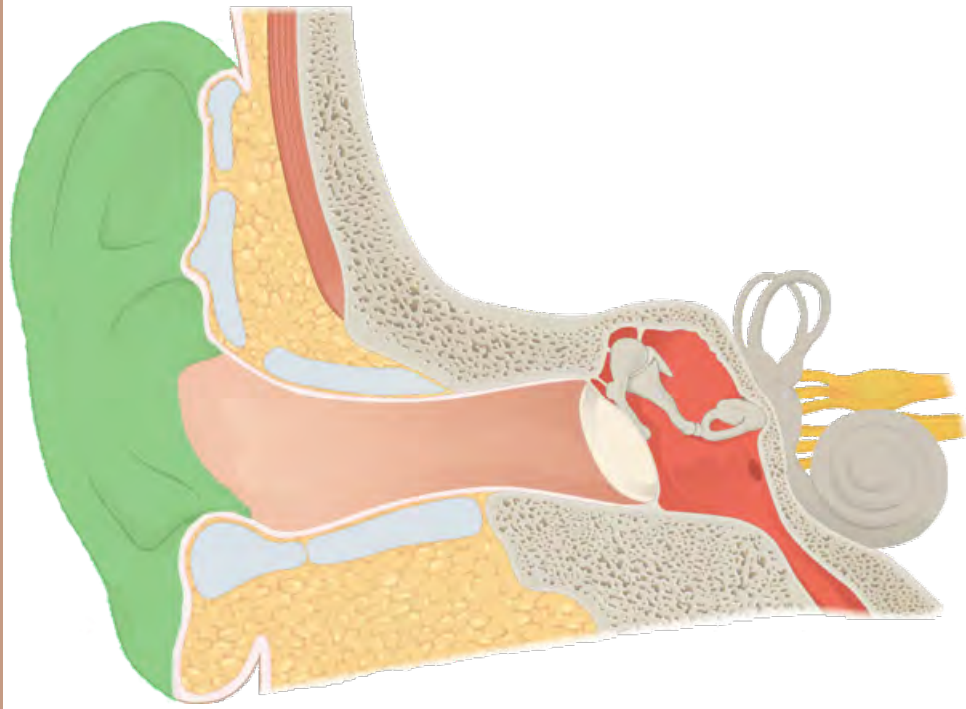


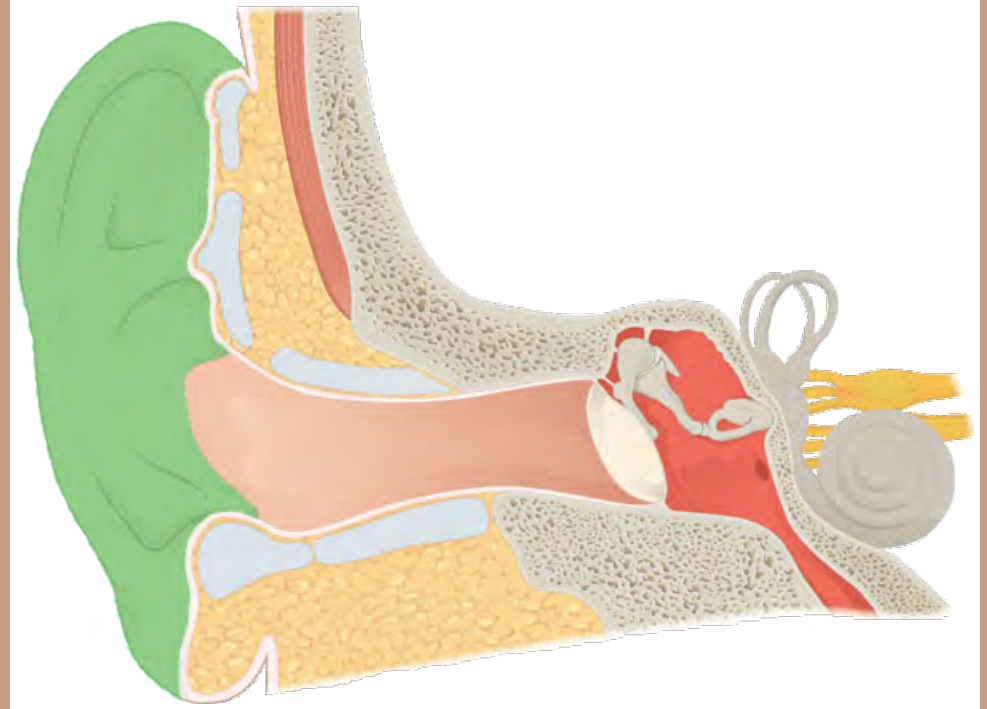
oído



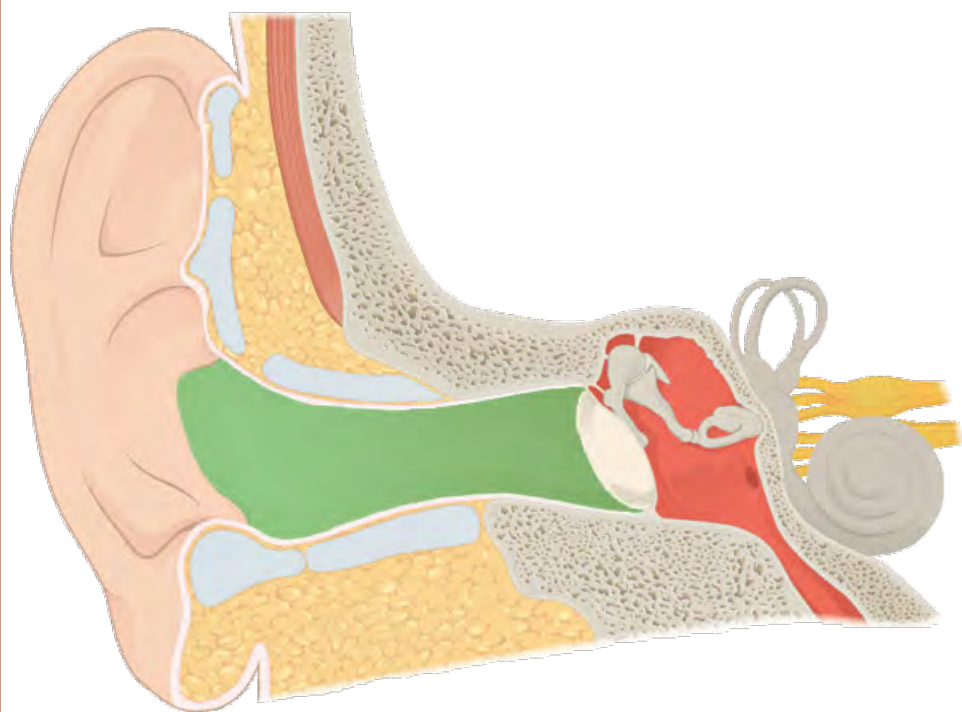
oído



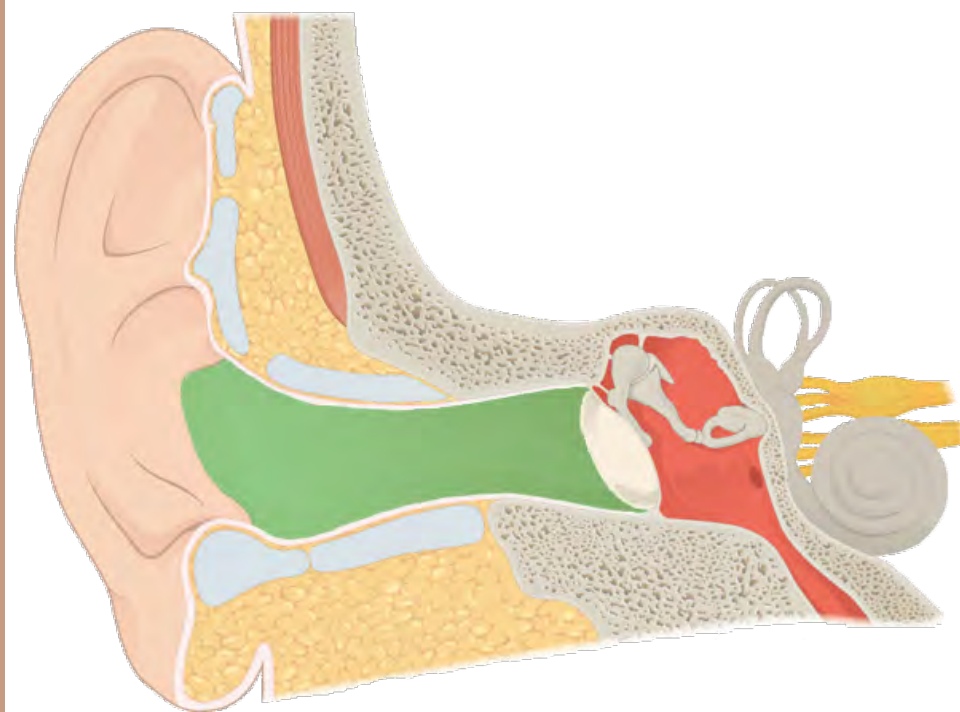
aurícula



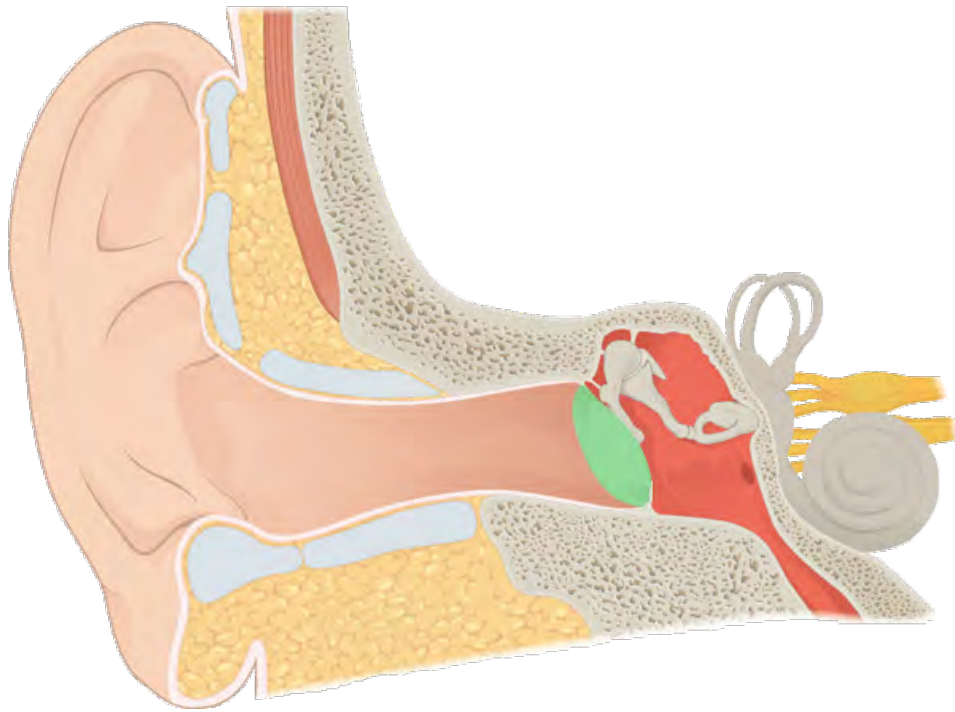
aurícula



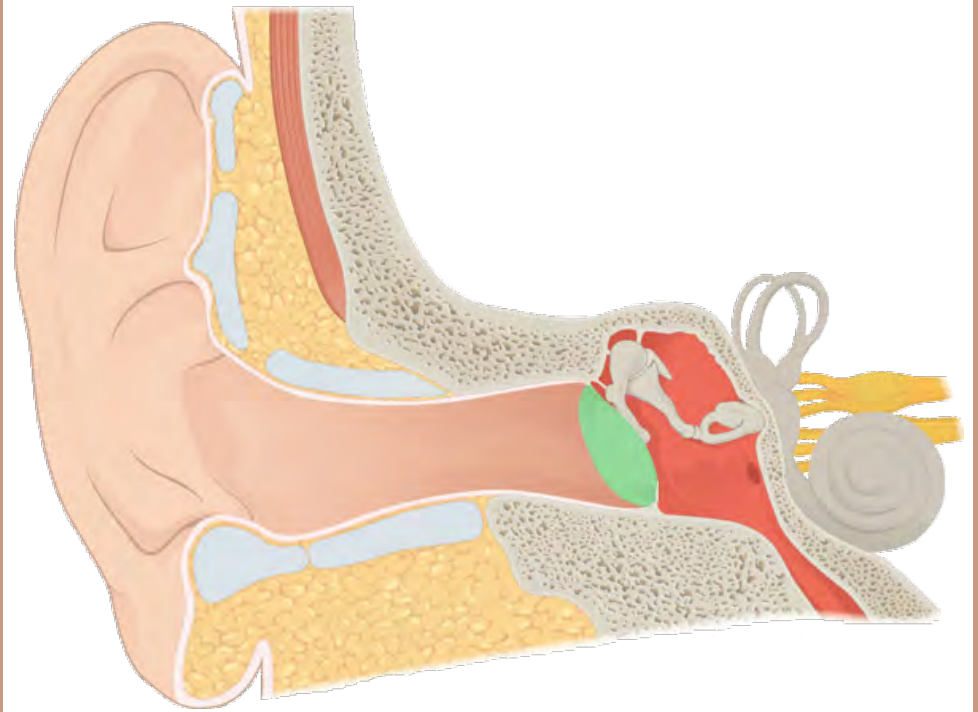
conducto auditivo externo



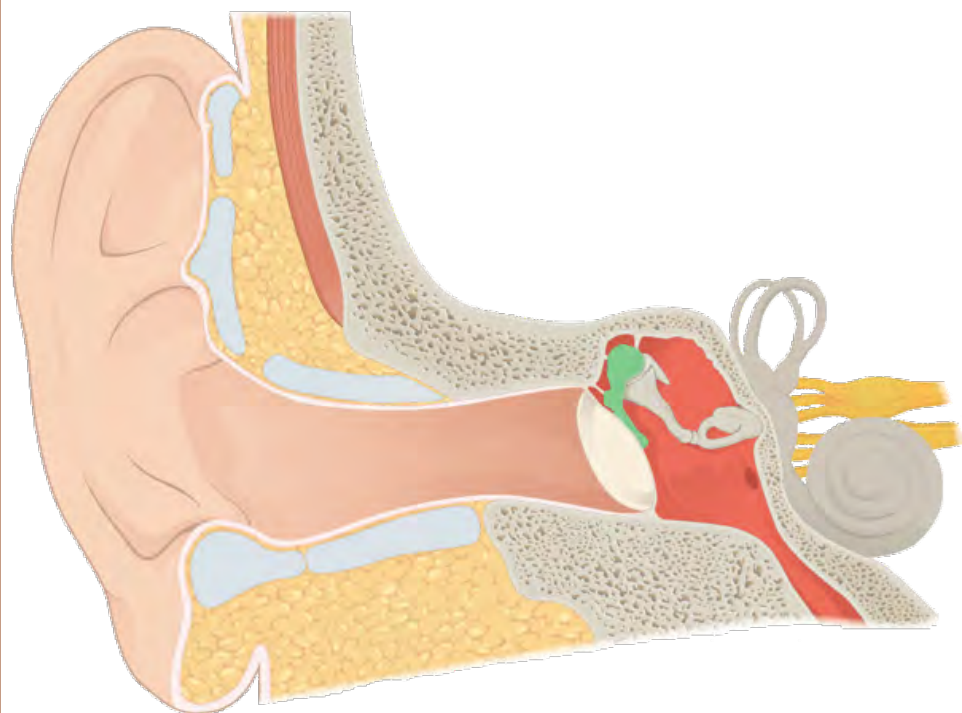
conducto auditivo externo



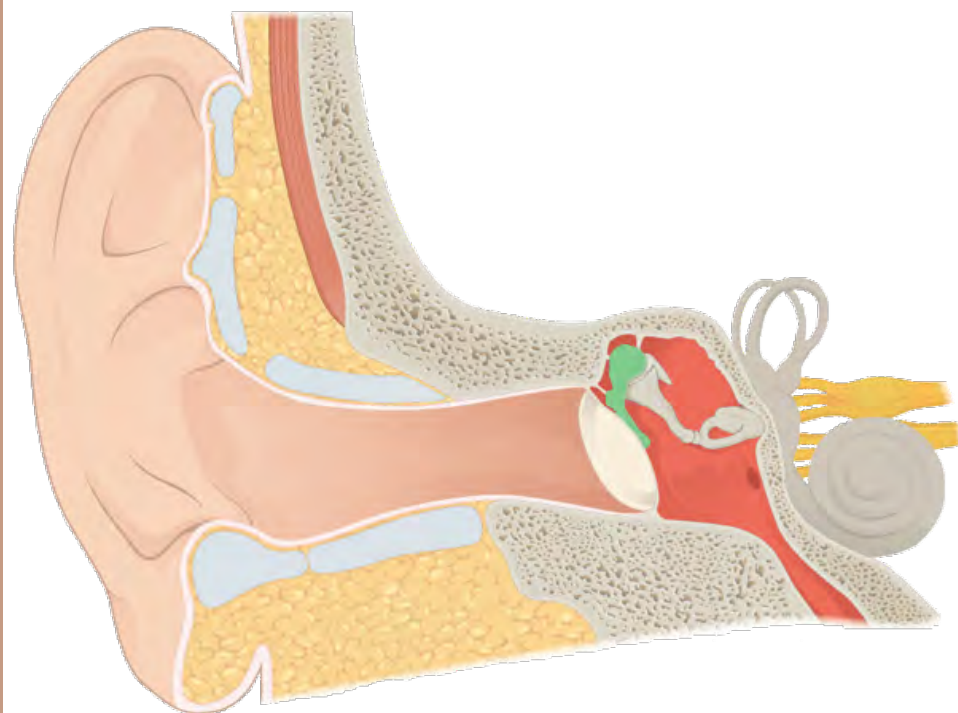
timpani



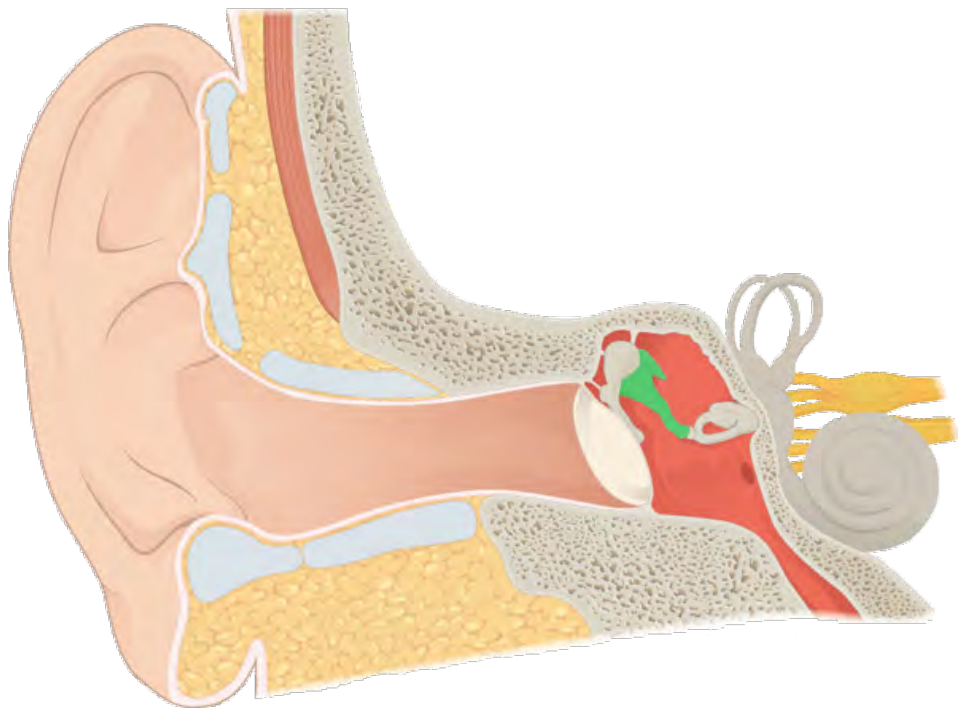
timpani



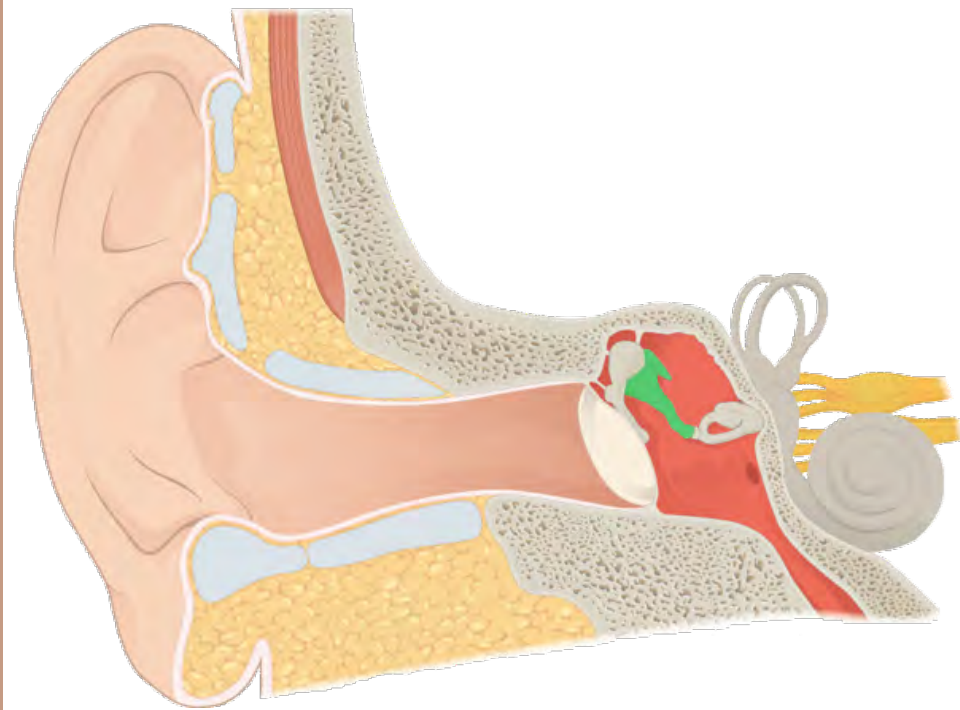
martillo o maleo



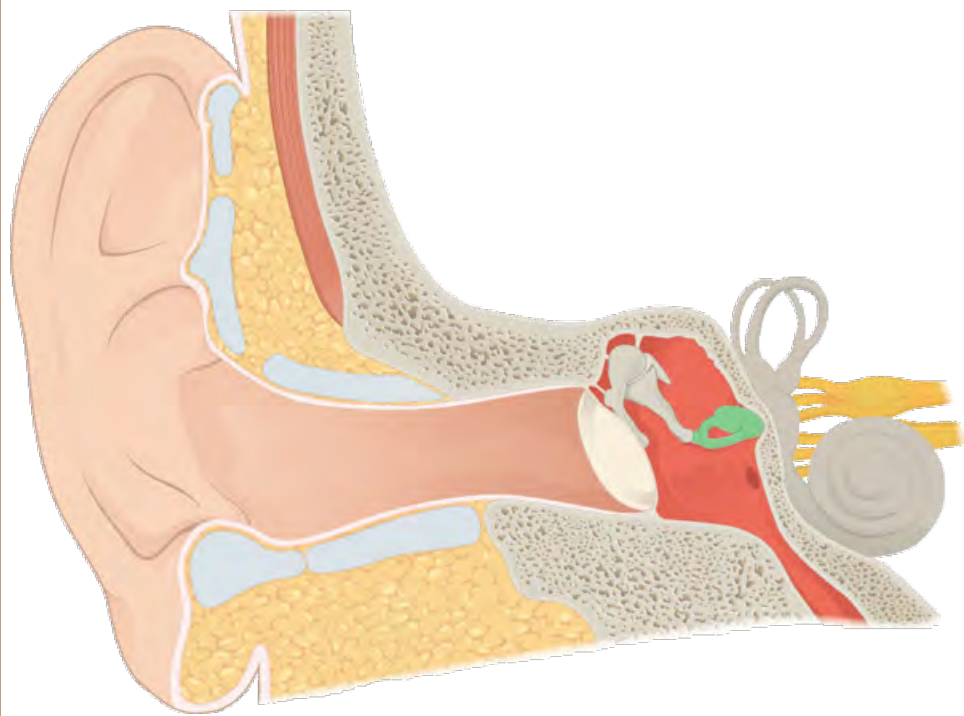
martillo o maleo



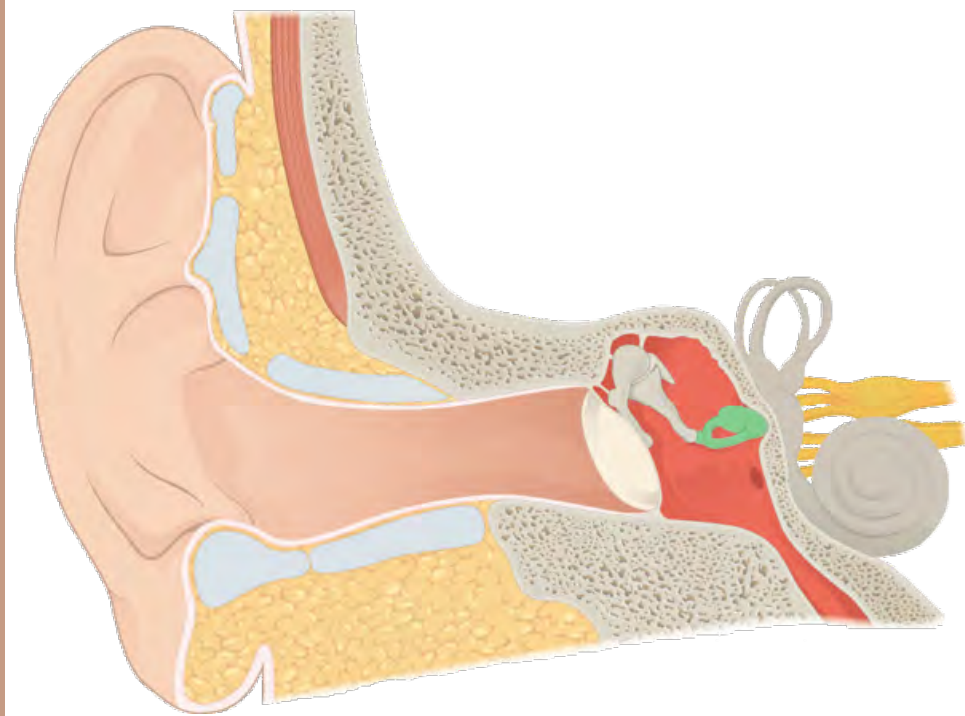
yunque



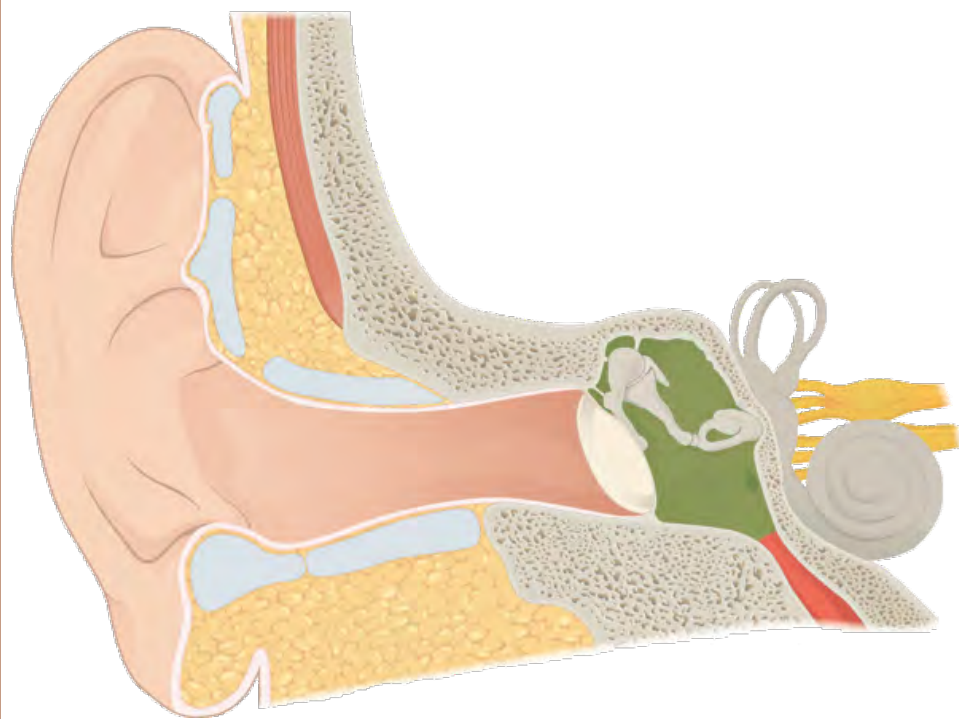
yunque



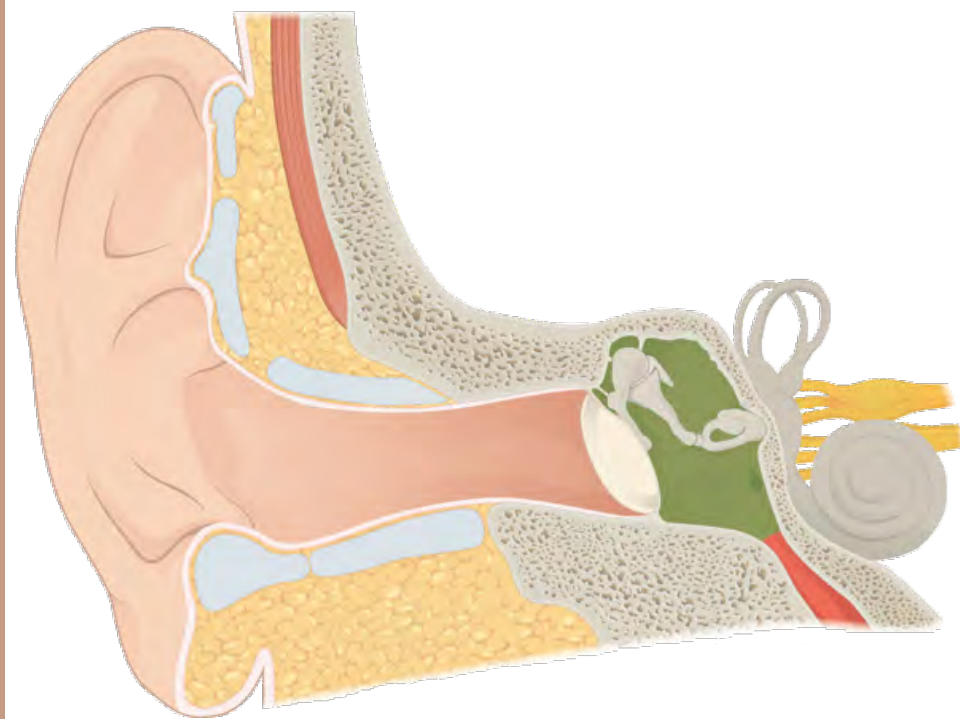
estribo



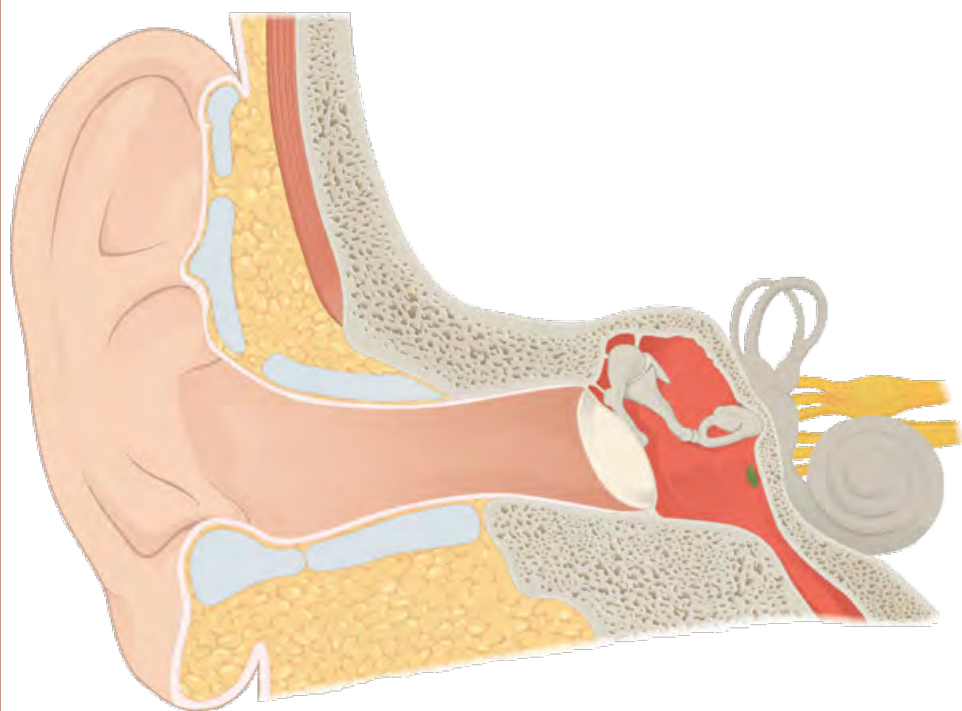
estribo



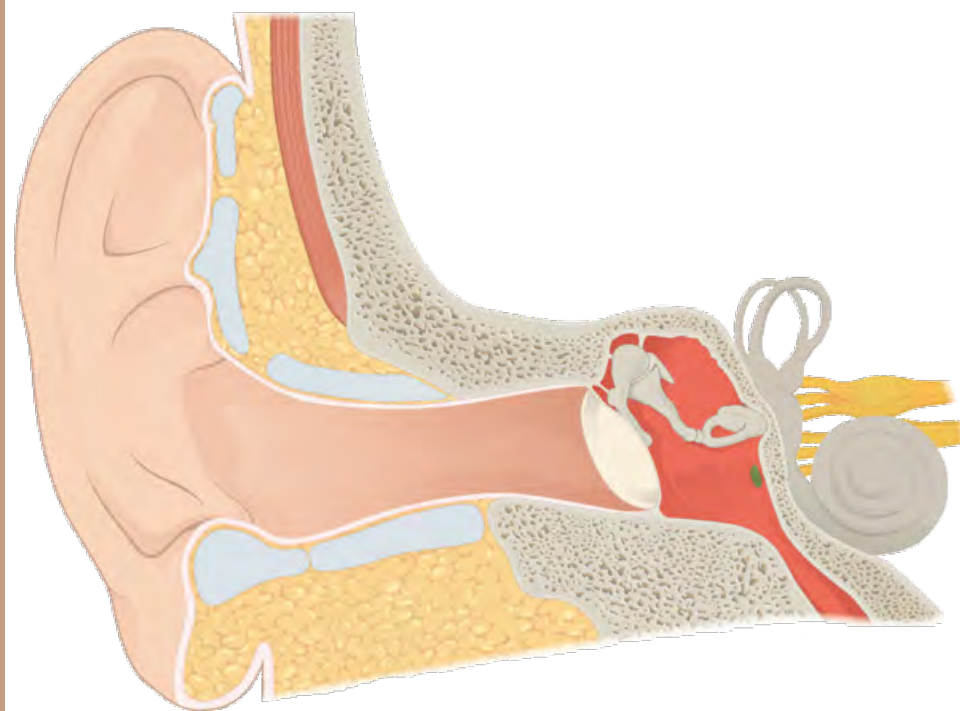
cavidad timpánica



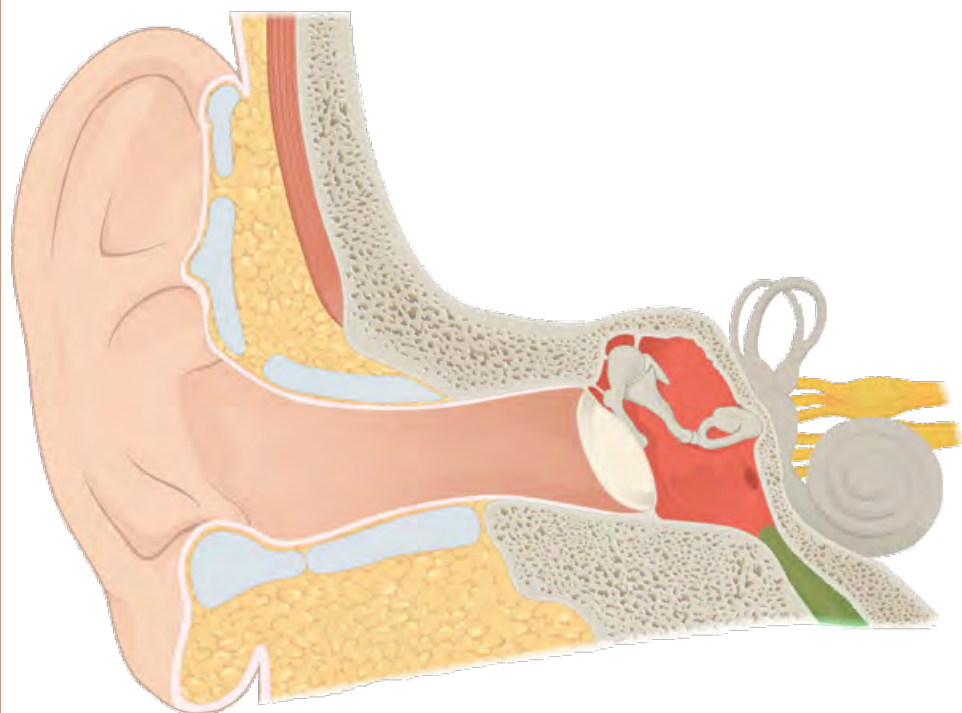
cavidad timpánica



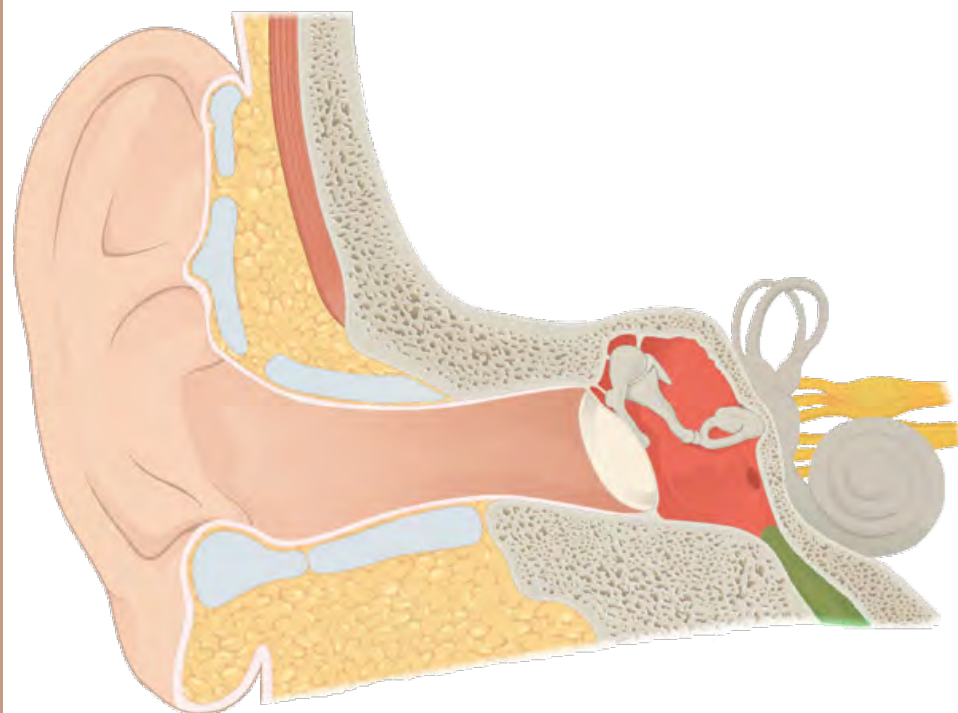
ventana redonda



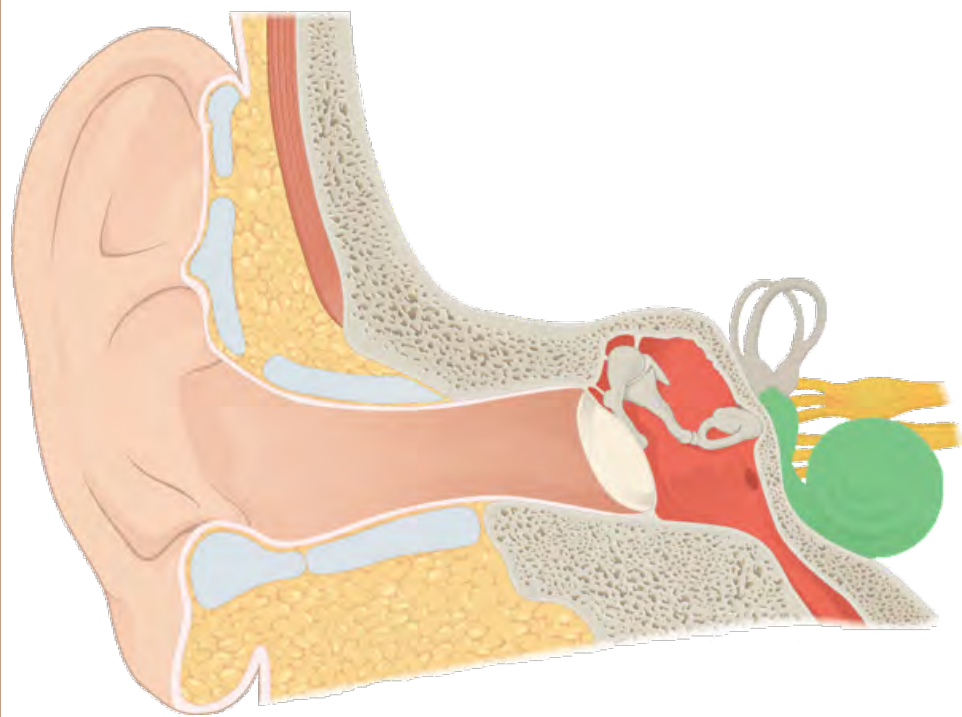
ventana redonda



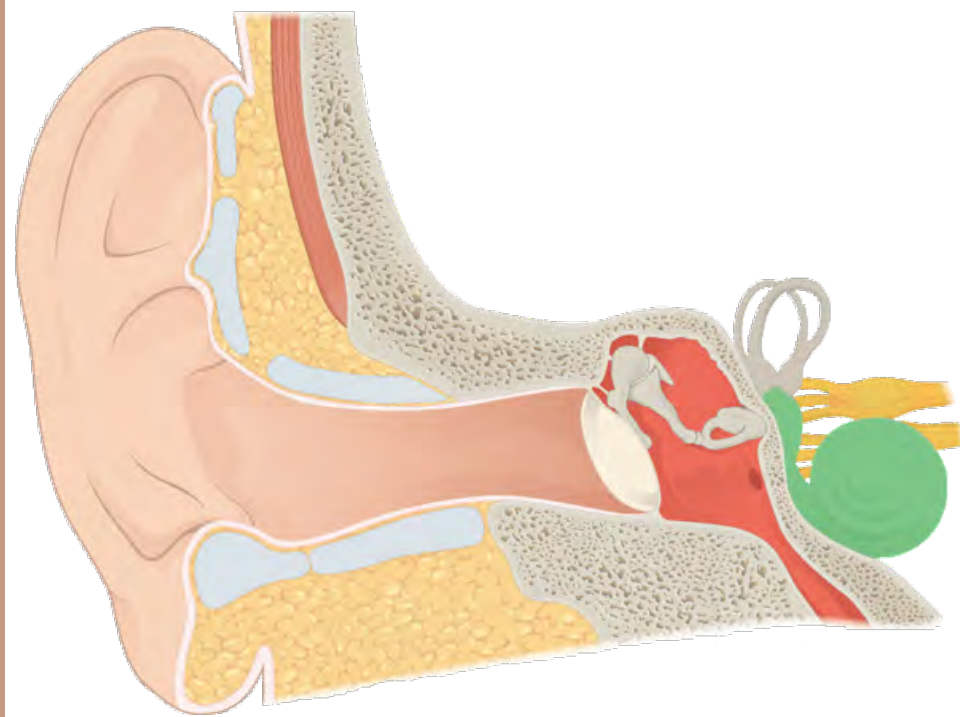
trompa de Eustaquio



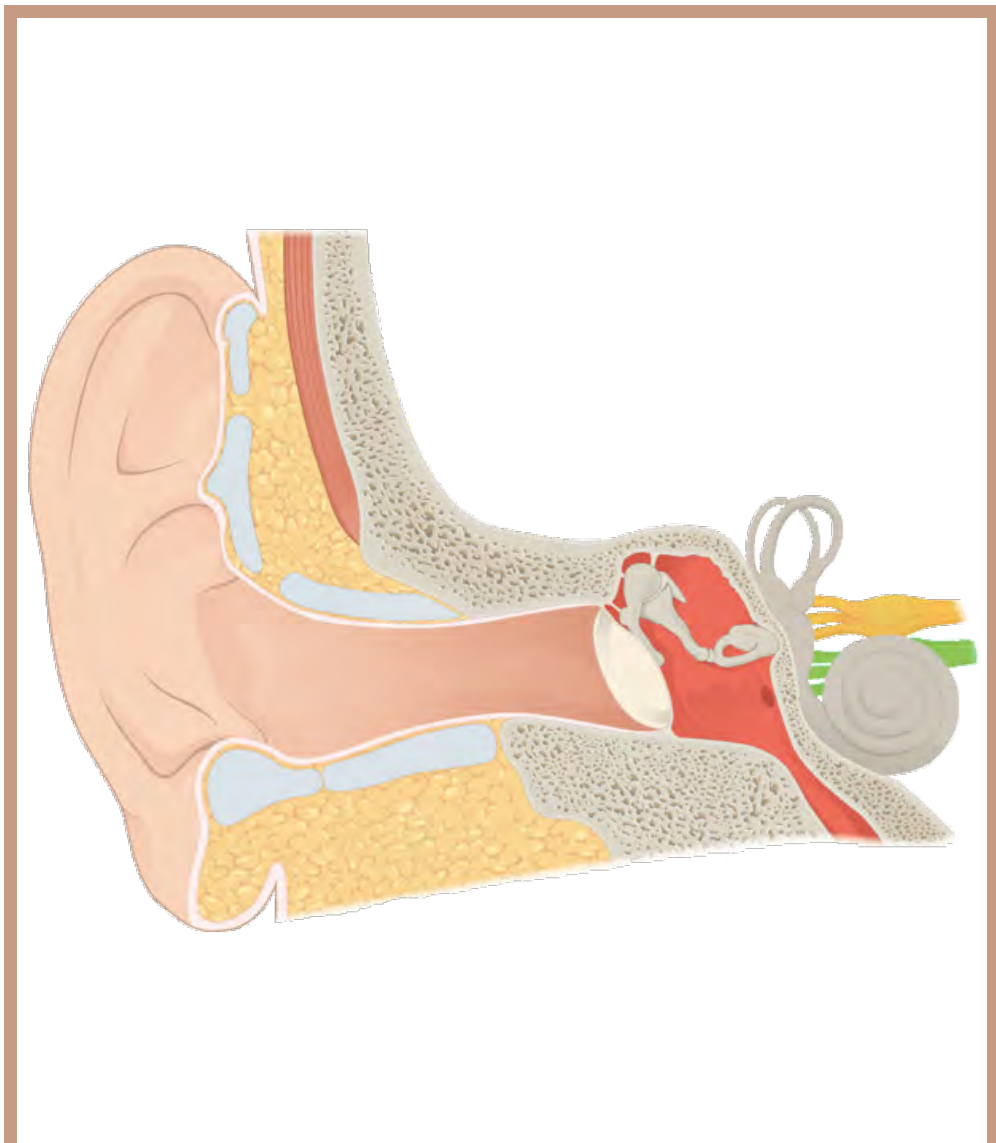
trompa de Eustaquio



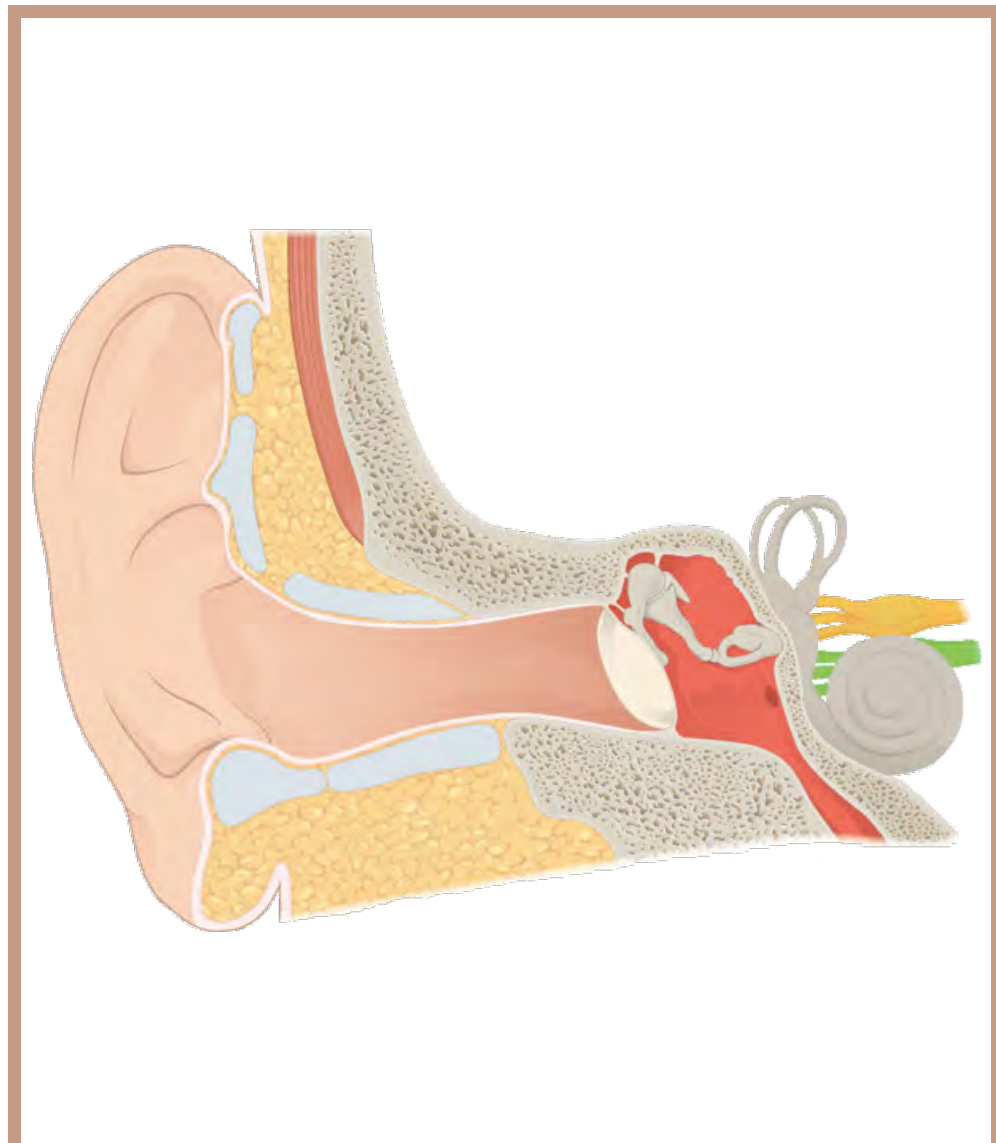cóclea



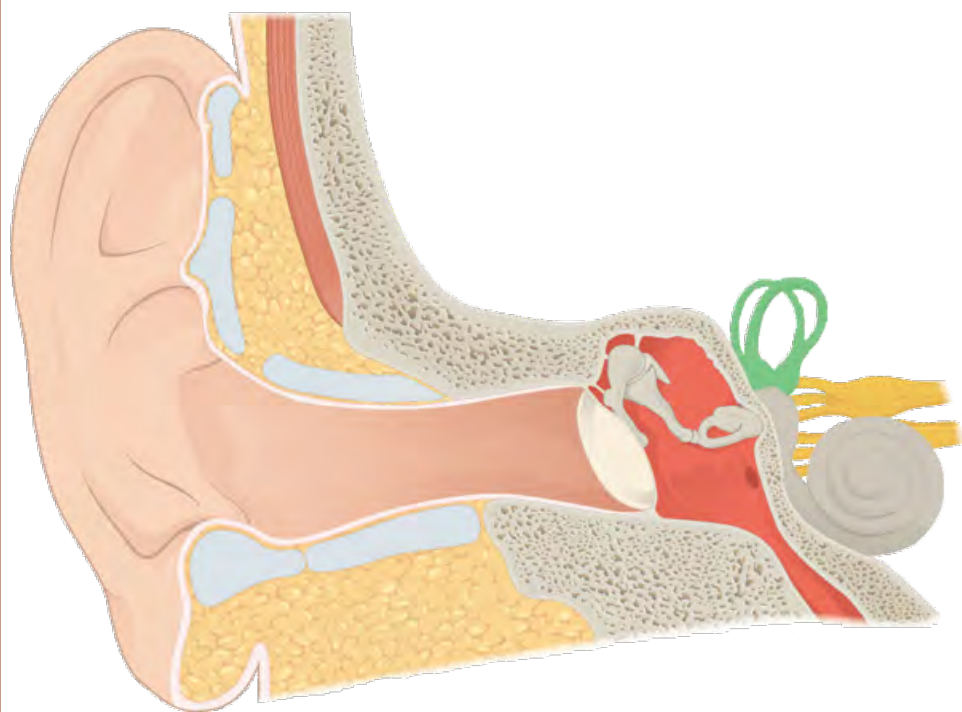
cóclea



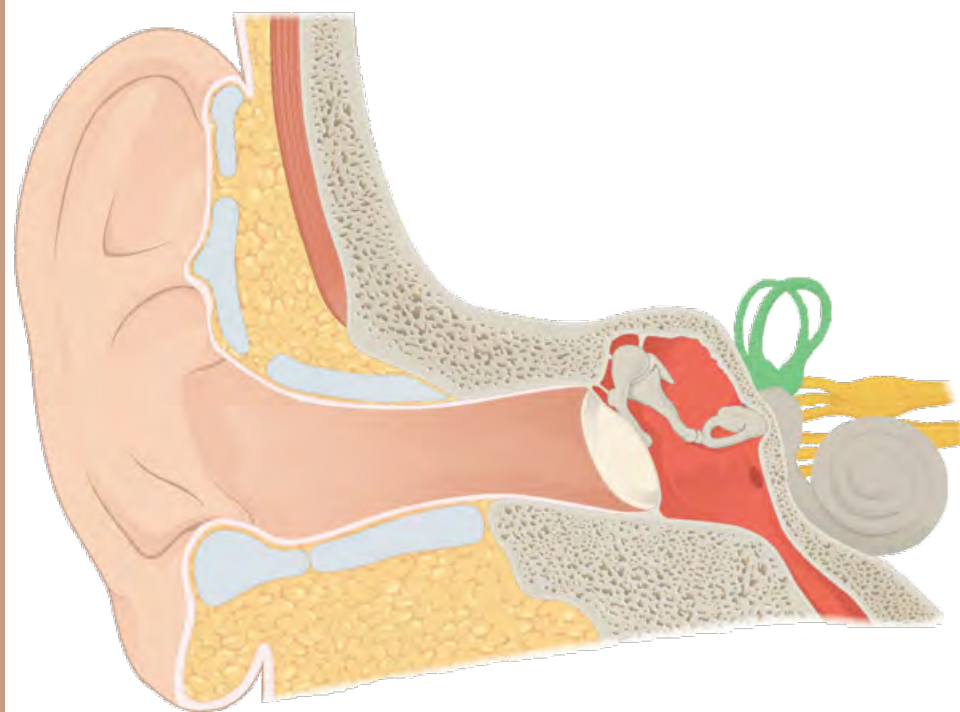
nervio coclear



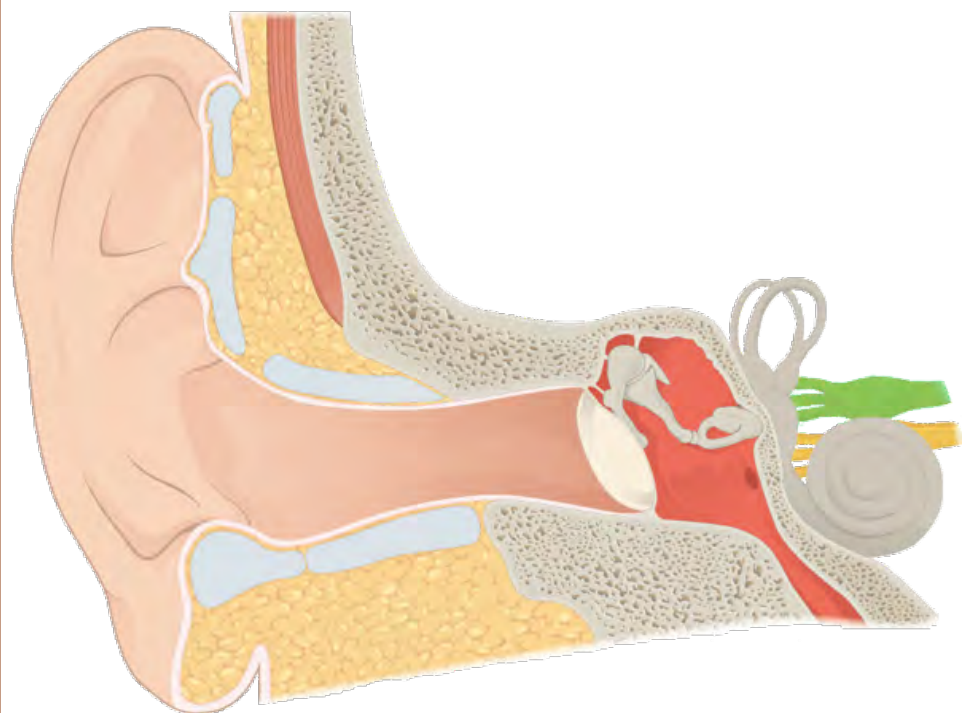
nervio coclear



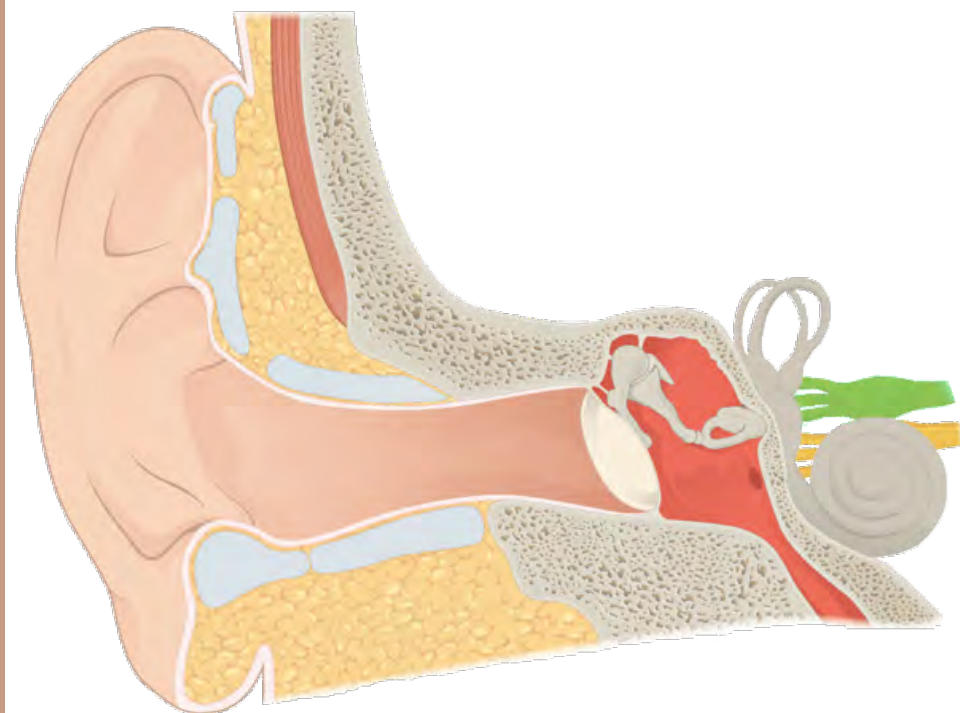
canales semicirculares



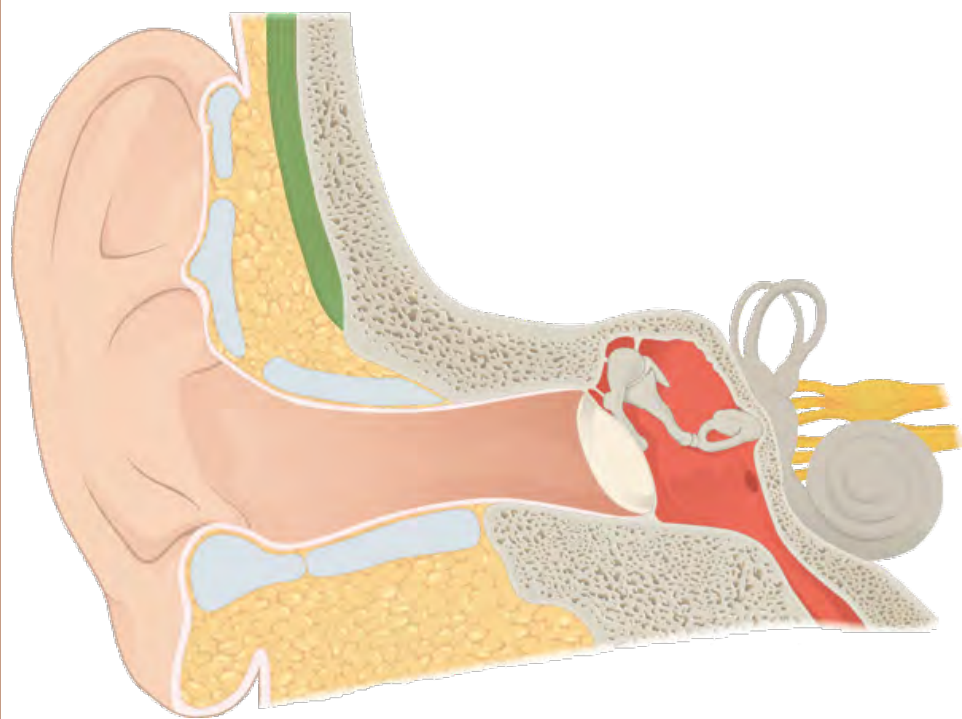
canales semicirculares



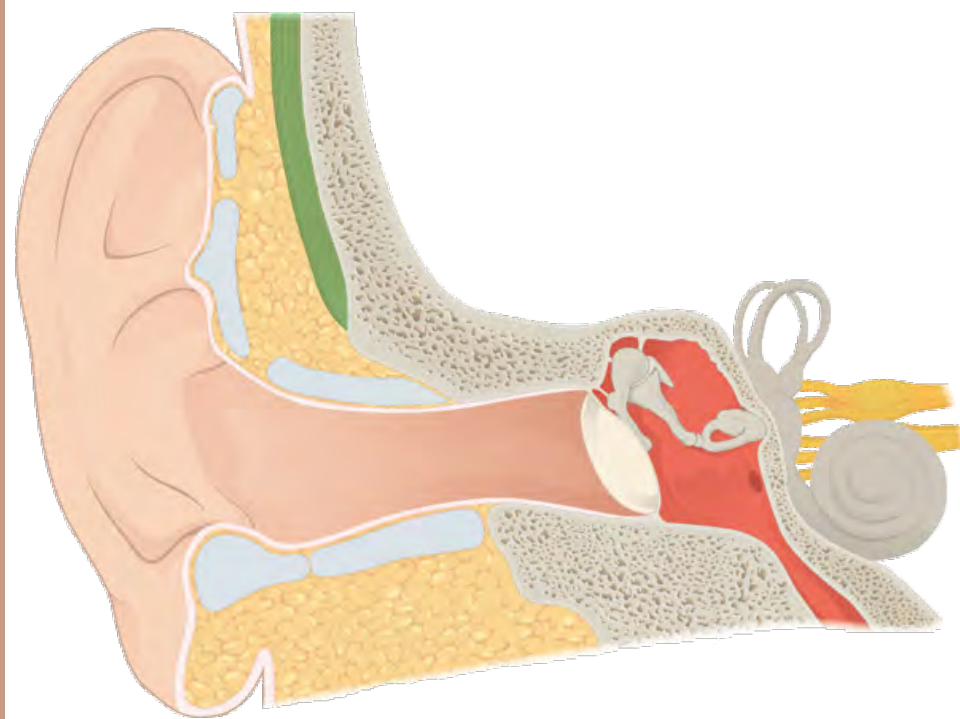
nervio vestibular



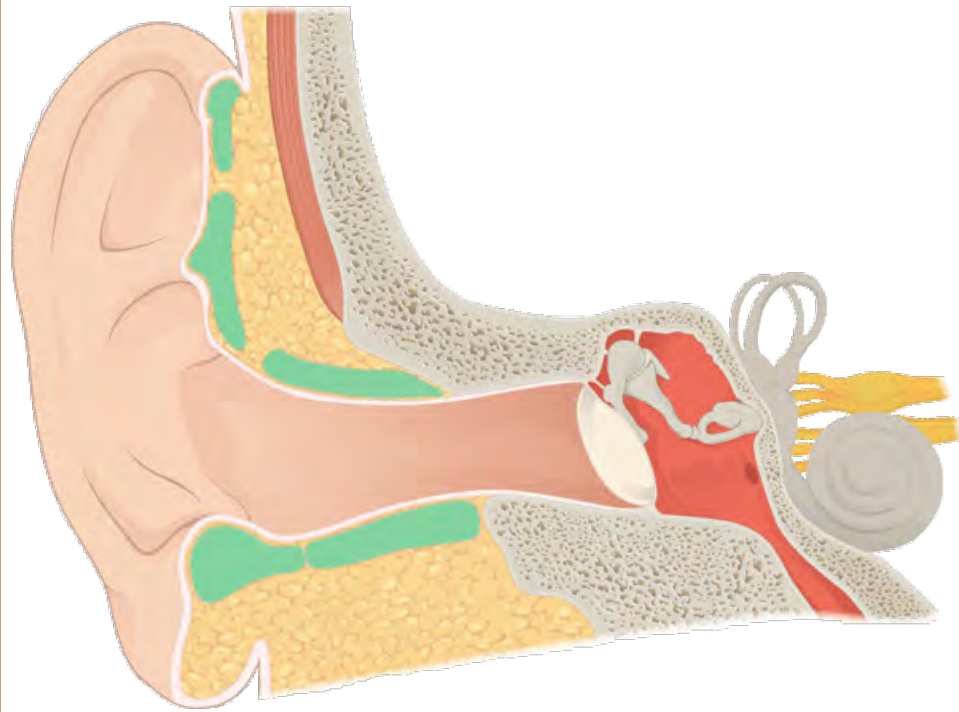
nervio vestibular



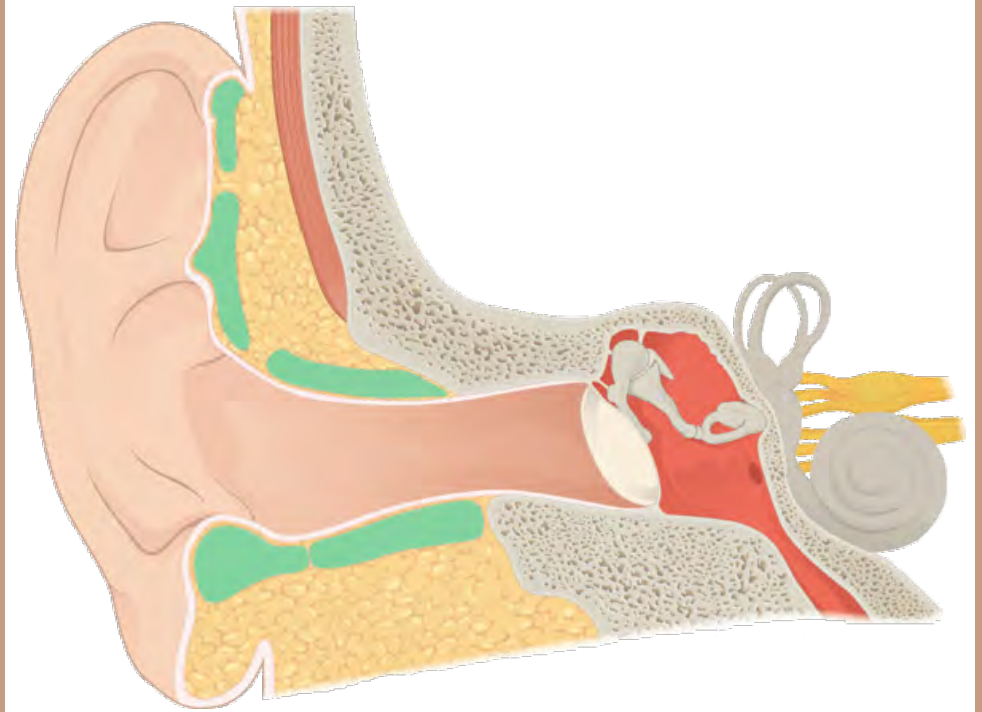
músculo temporal



músculo temporal



cartílago elástico



cartílago elástico

imagen: https://commons.wikimedia.org/wiki/File:1404_The_Structures_of_the_Ear.jpg

escritura: KG Primary Penmanship 2

editado con: Adobe Photoshop